



UCDAVIS

VETERINARY MEDICINE

California Animal Health and
Food Safety Laboratory System



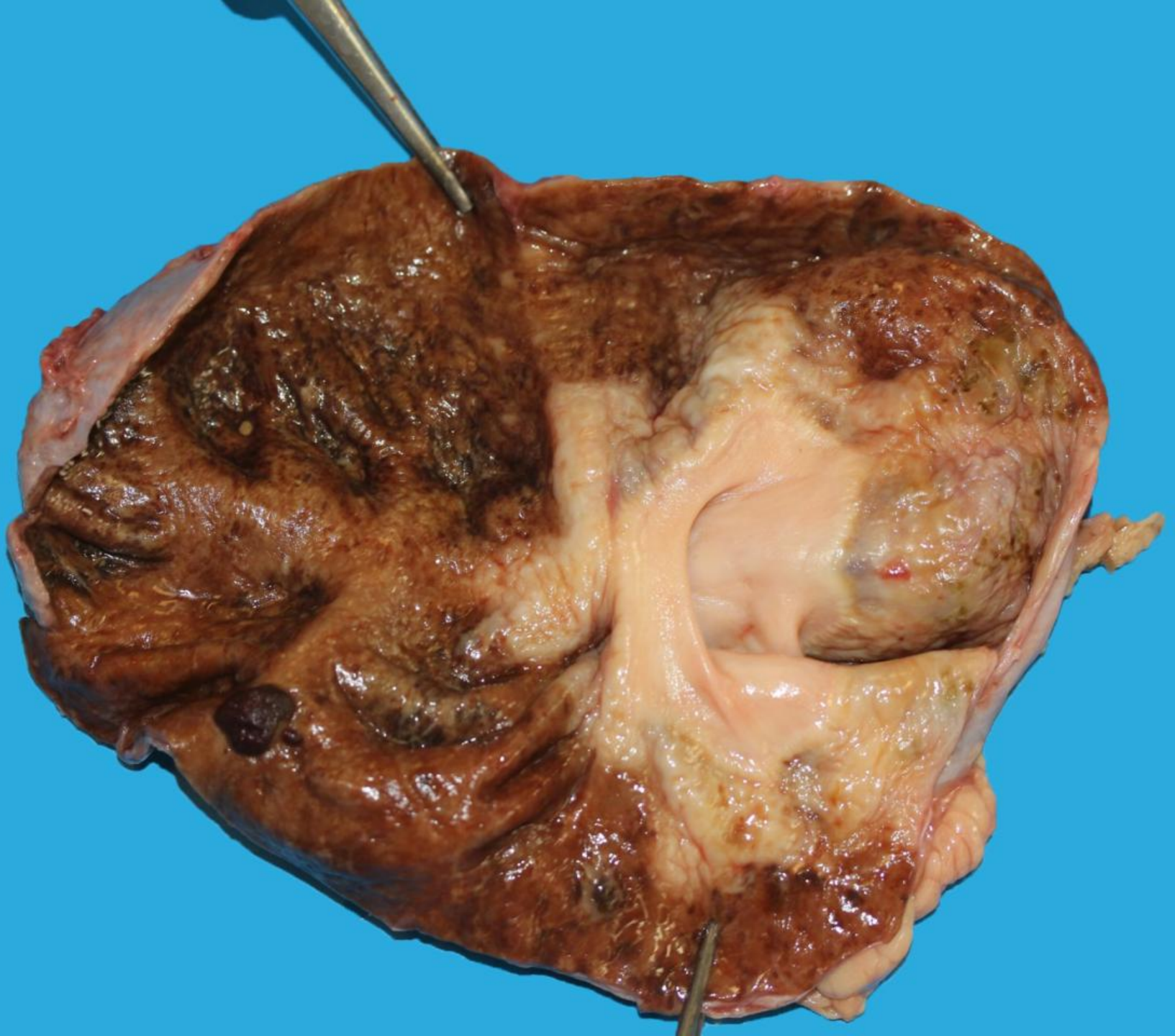
Equine urinary tract pathology

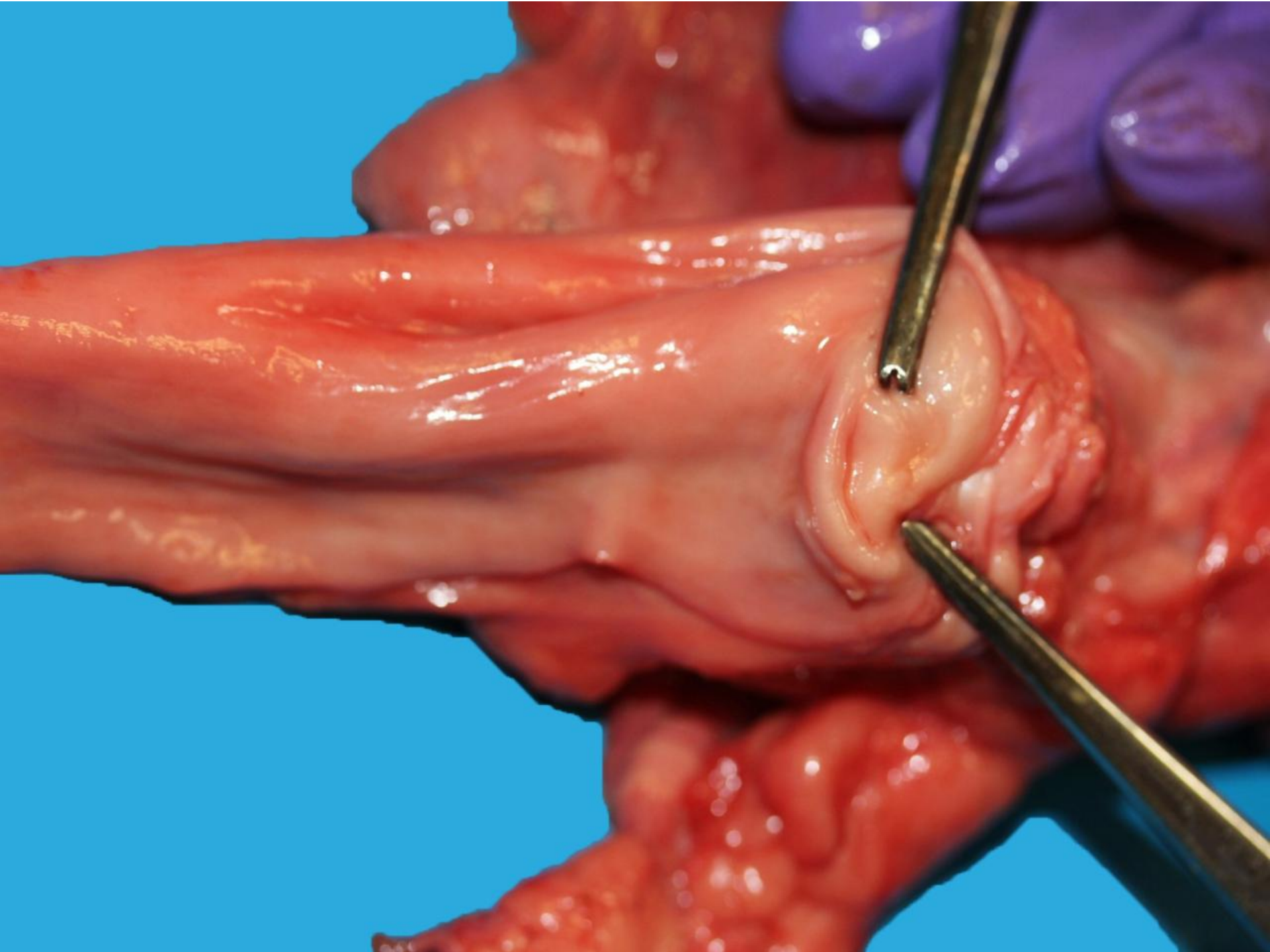
Francisco A. Uzal

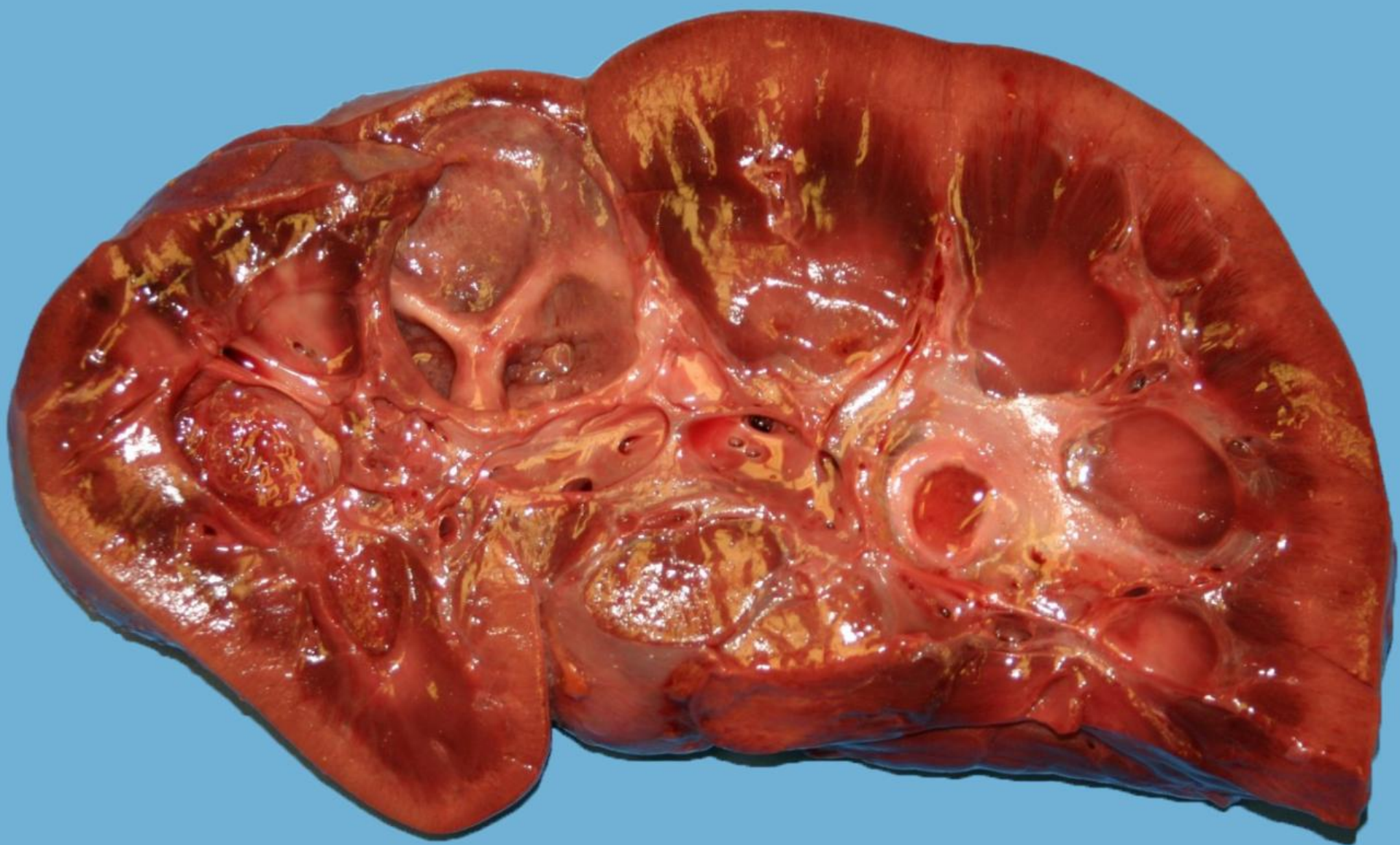California Animal Health and Food Safety Laboratory System,
San Bernardino Branch, UC Davis

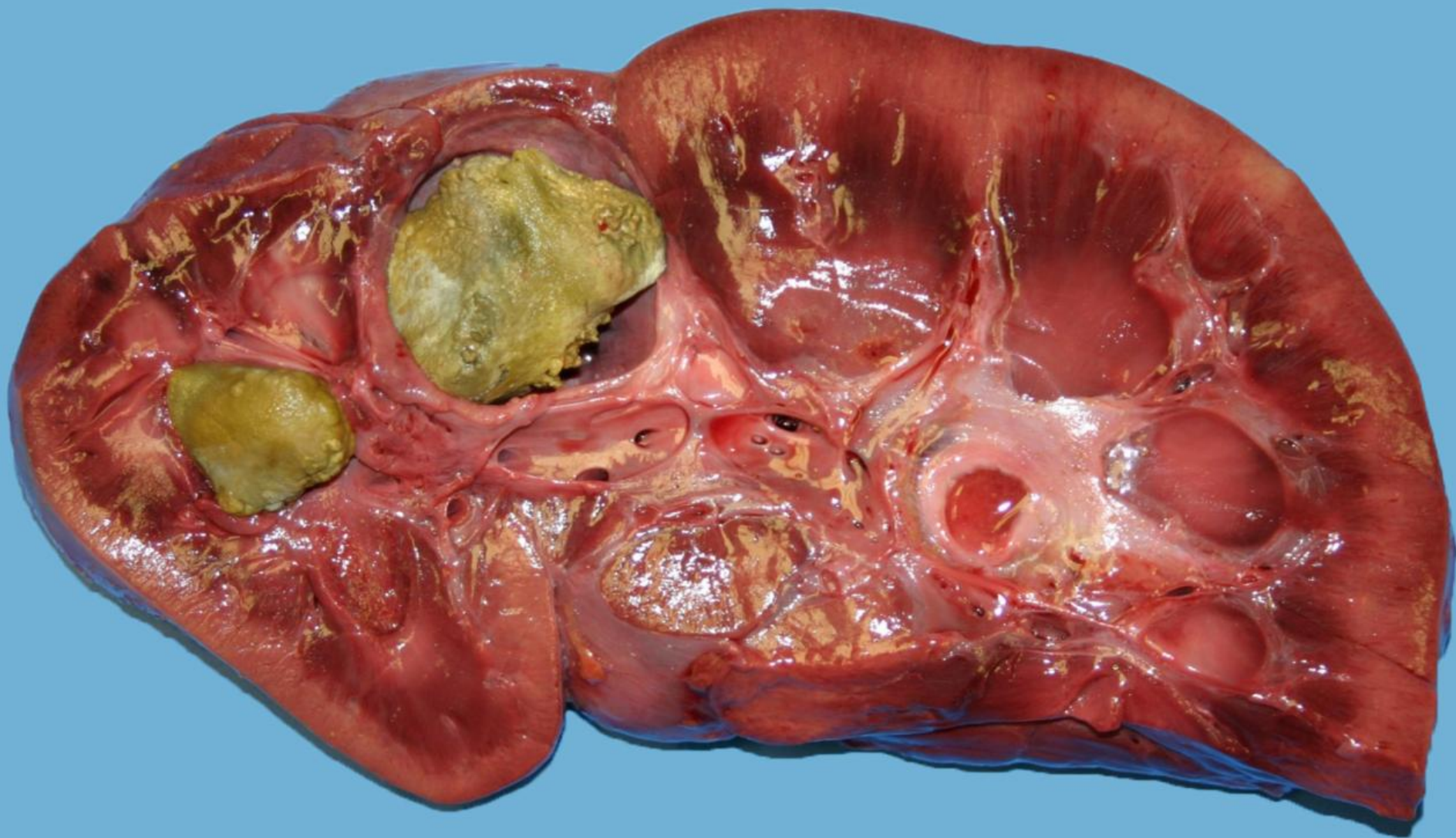
Photographic credits

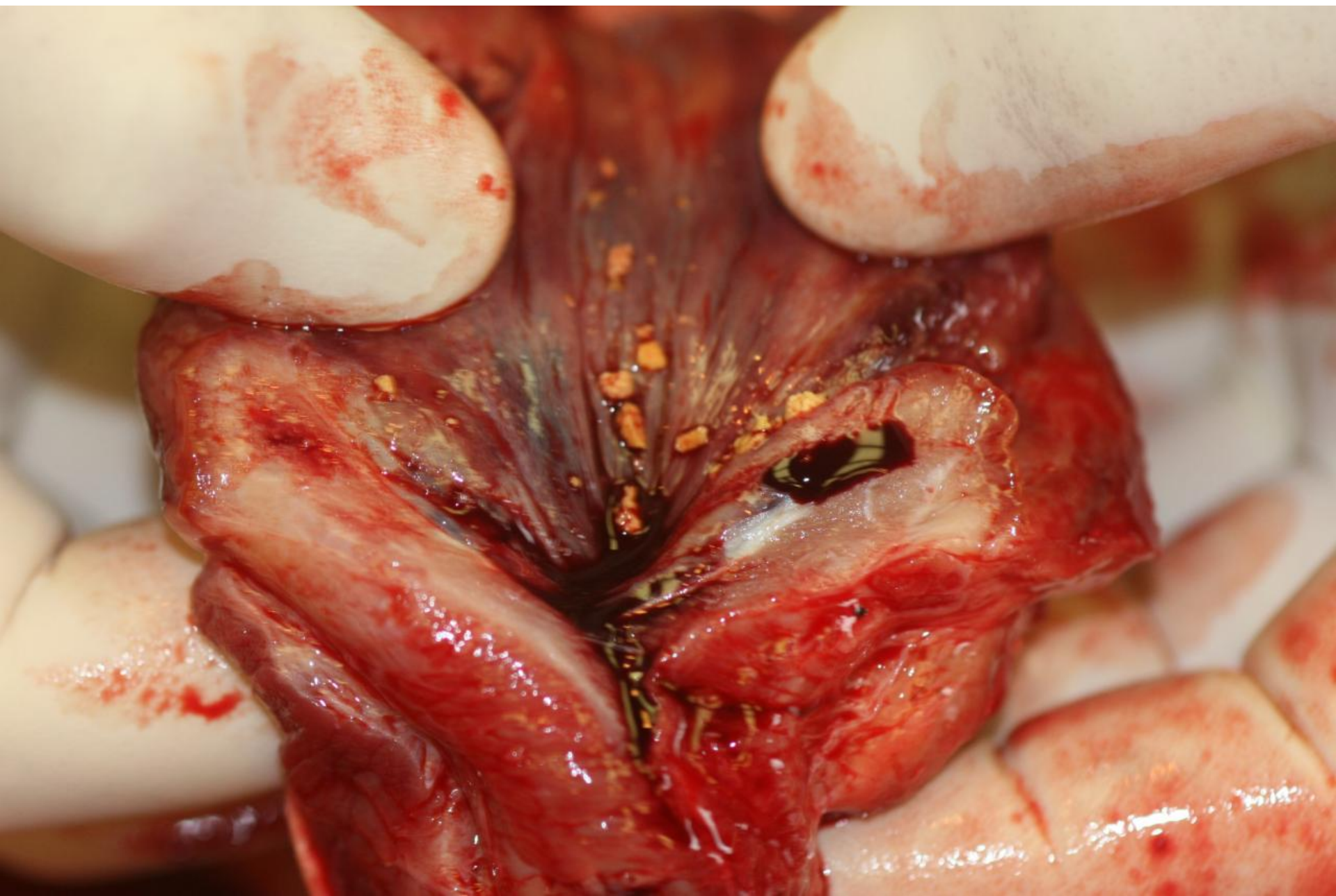
- Noha's Arkives
- Brian Porter

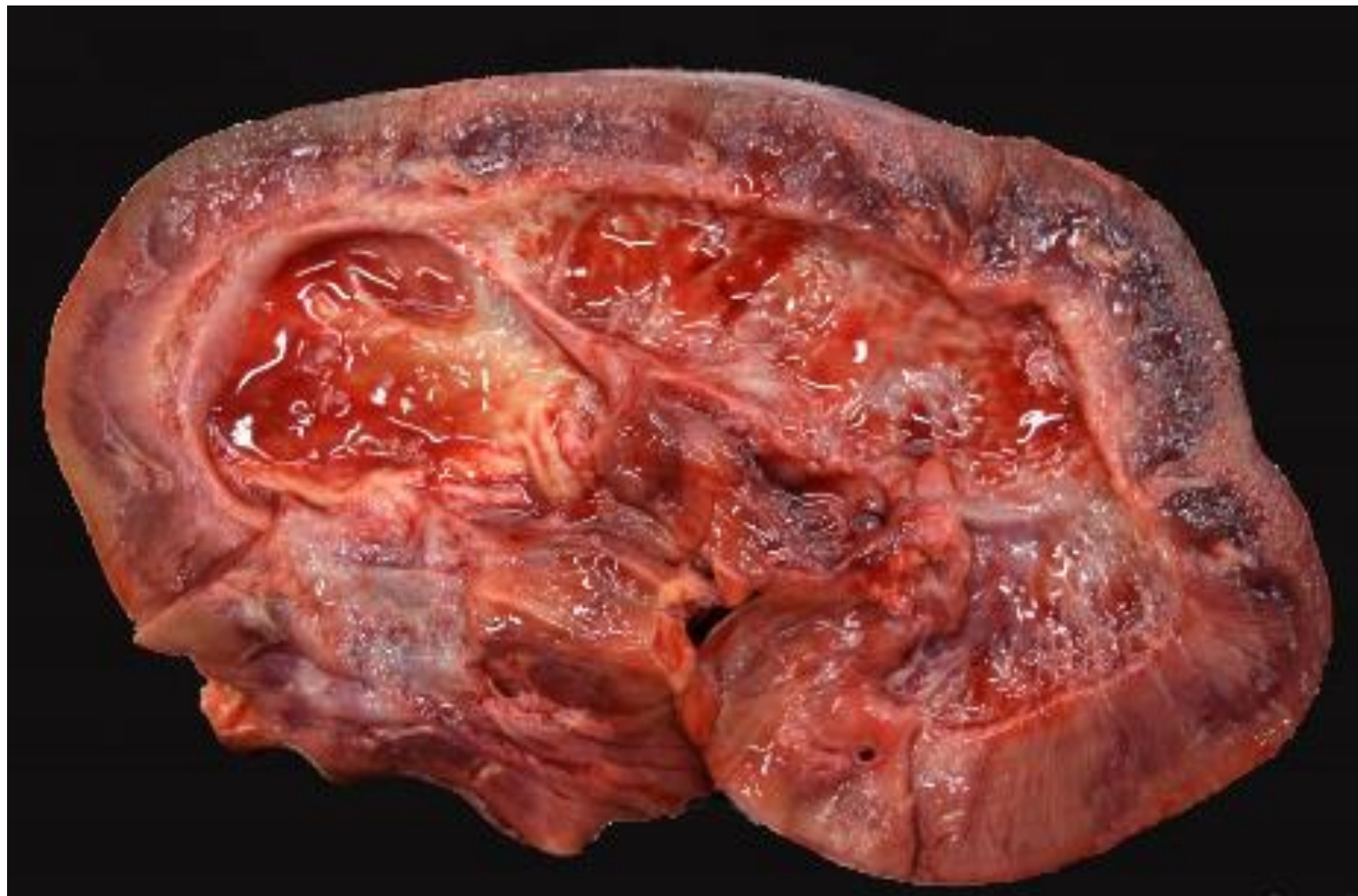

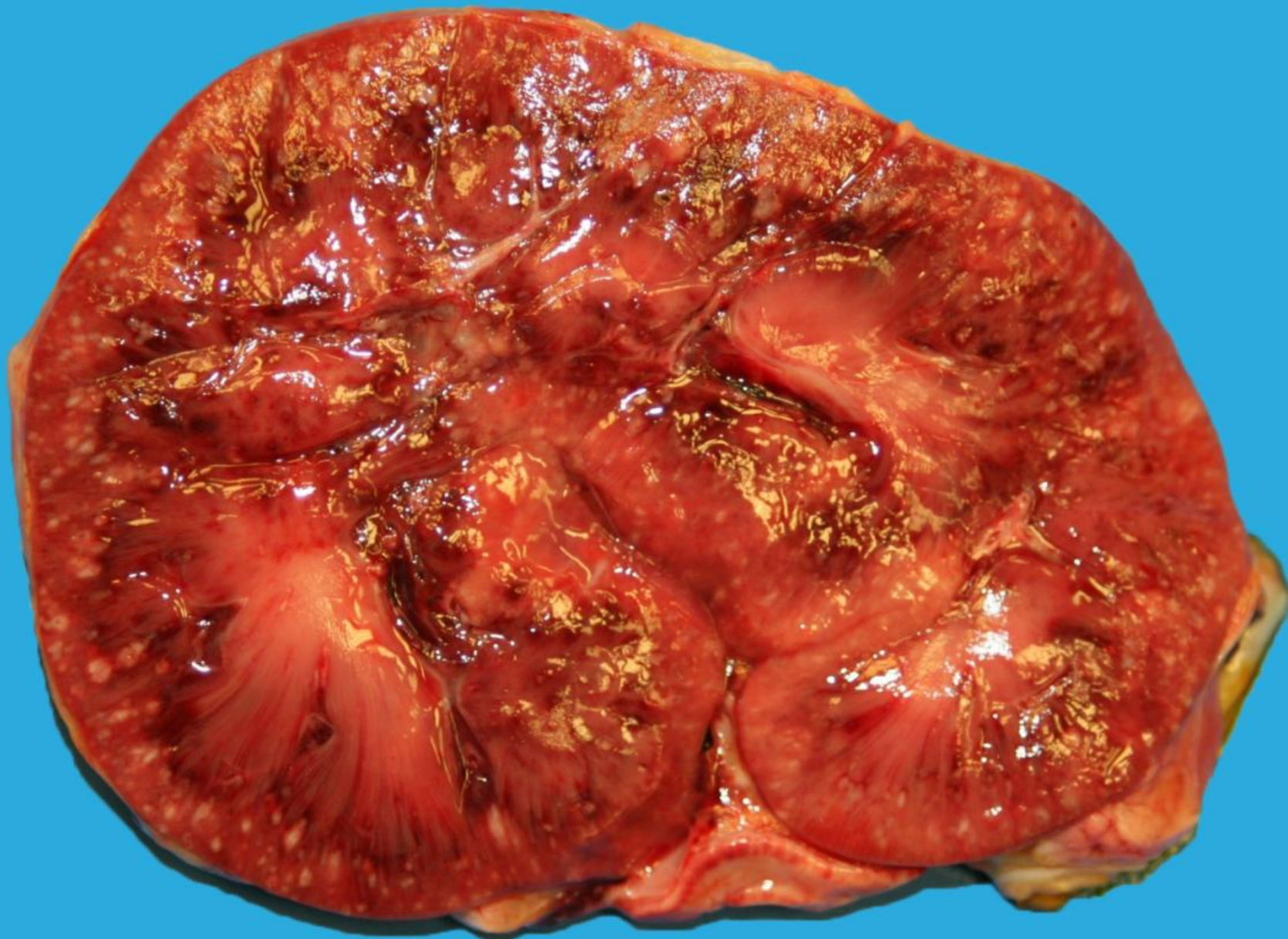


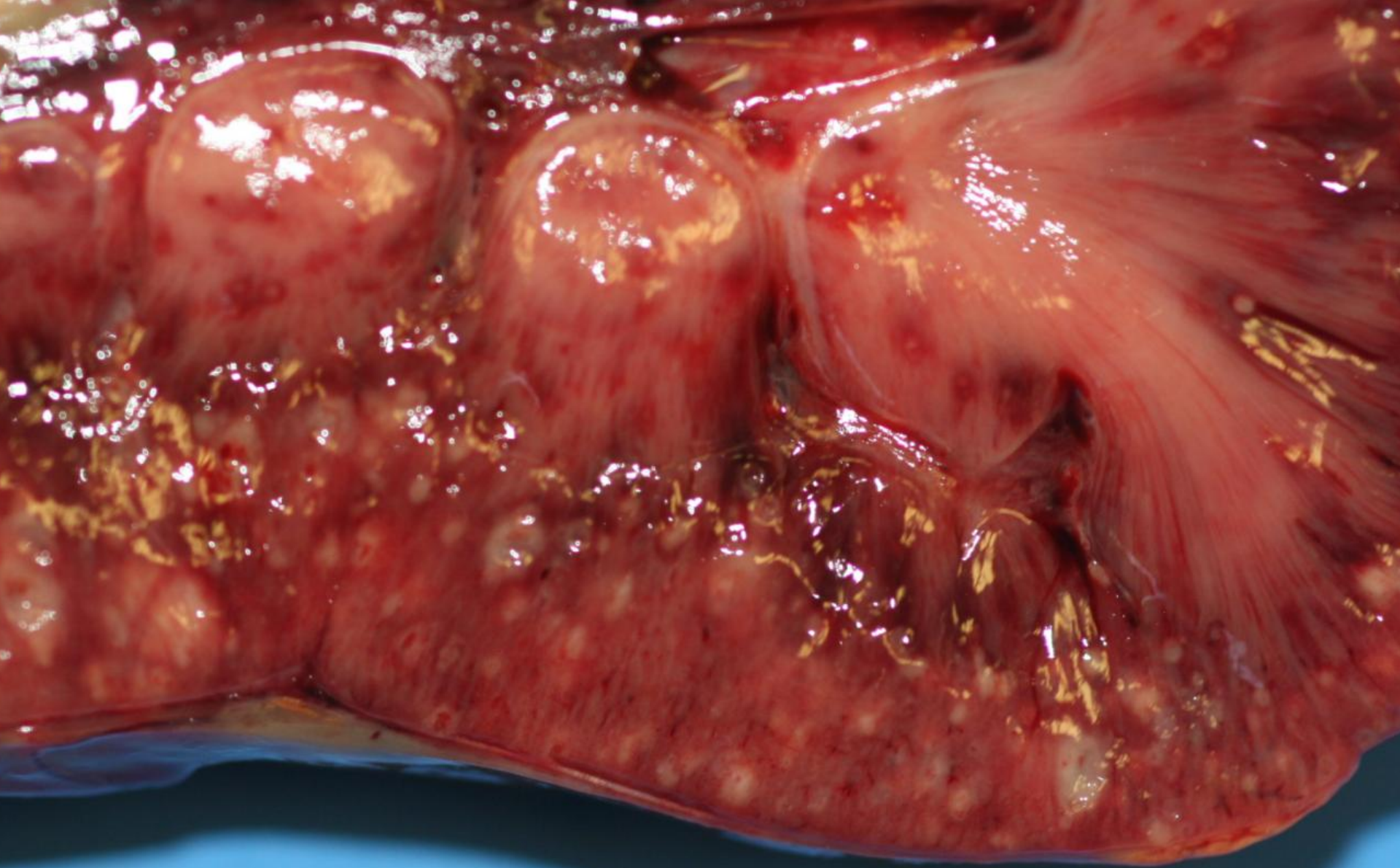


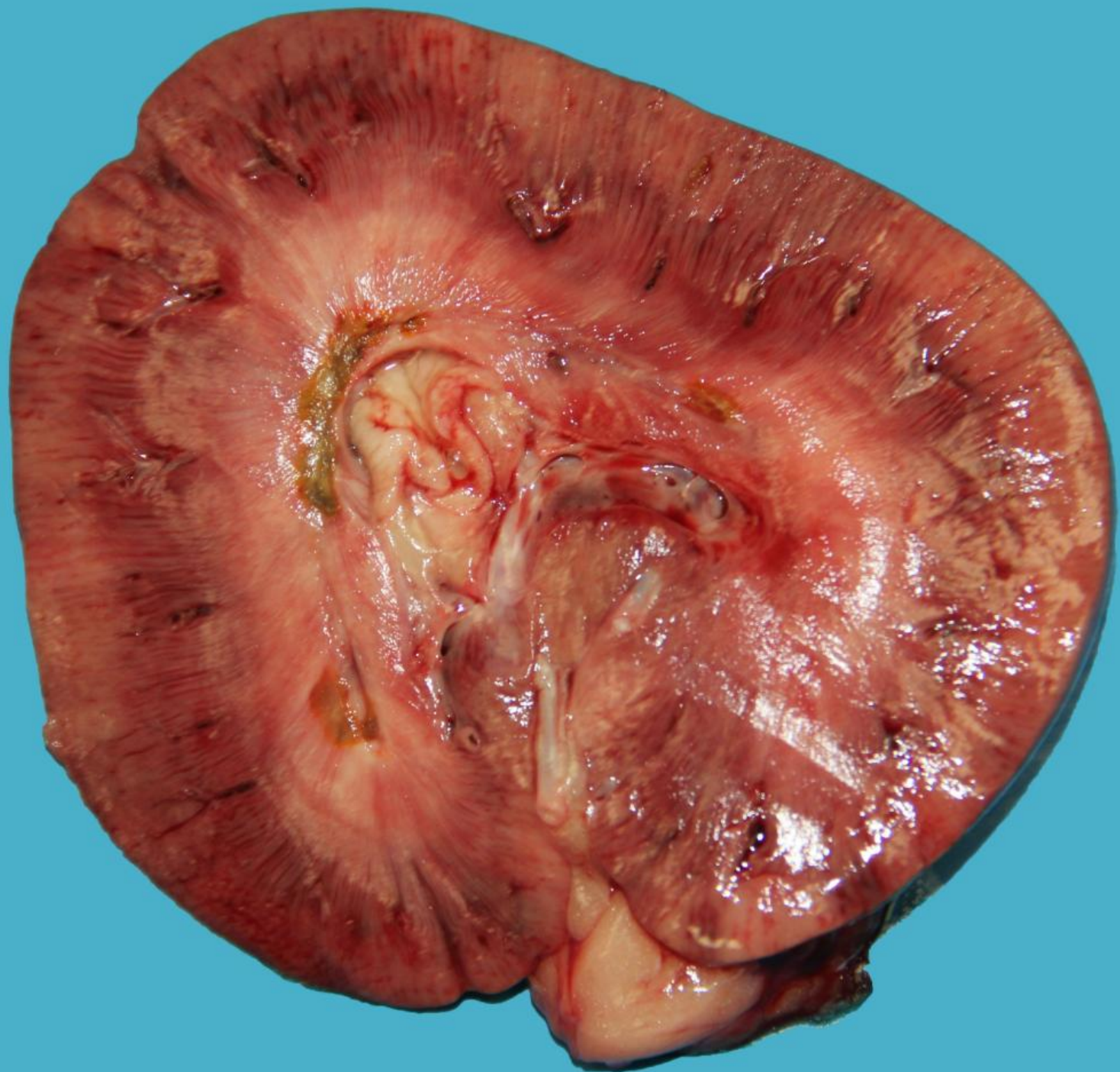


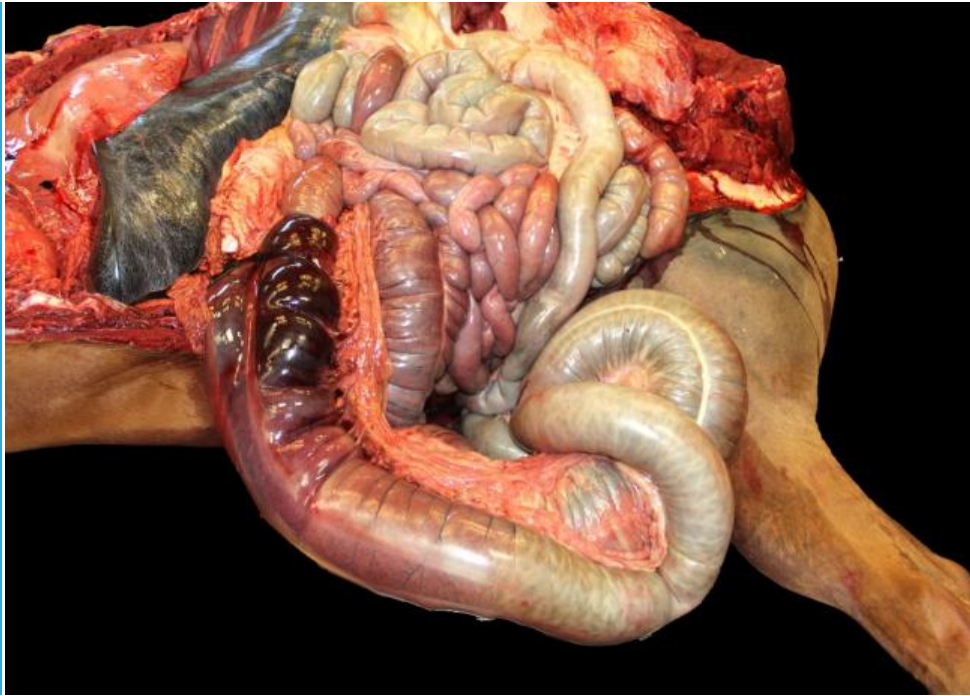

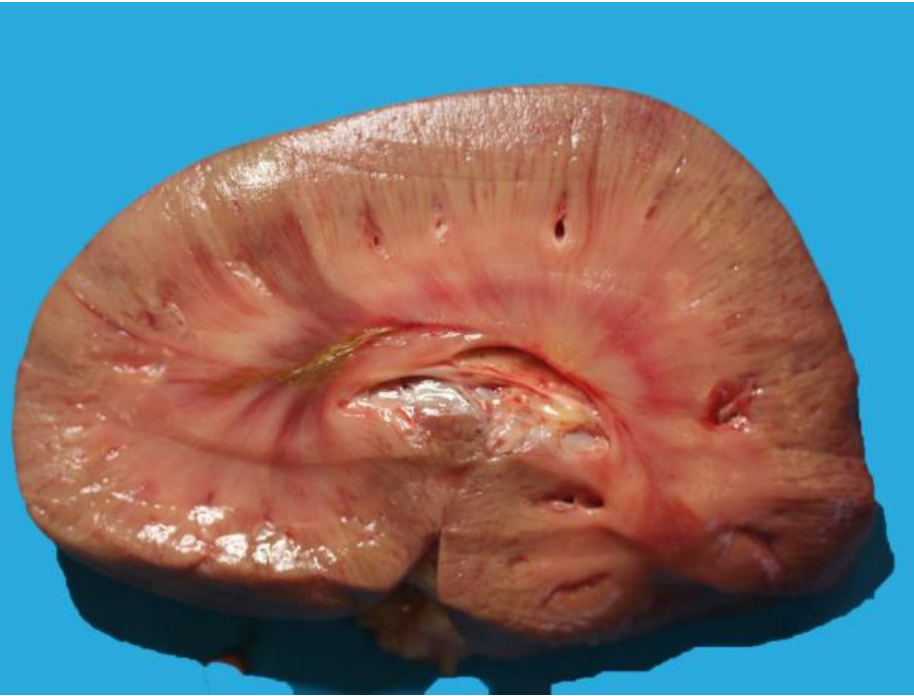


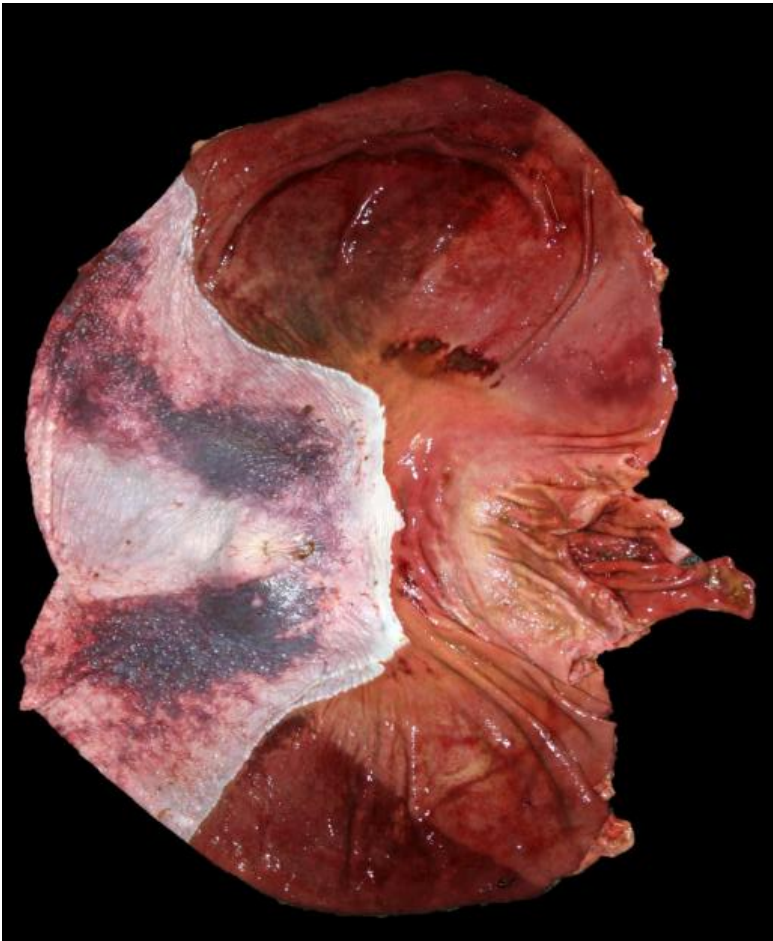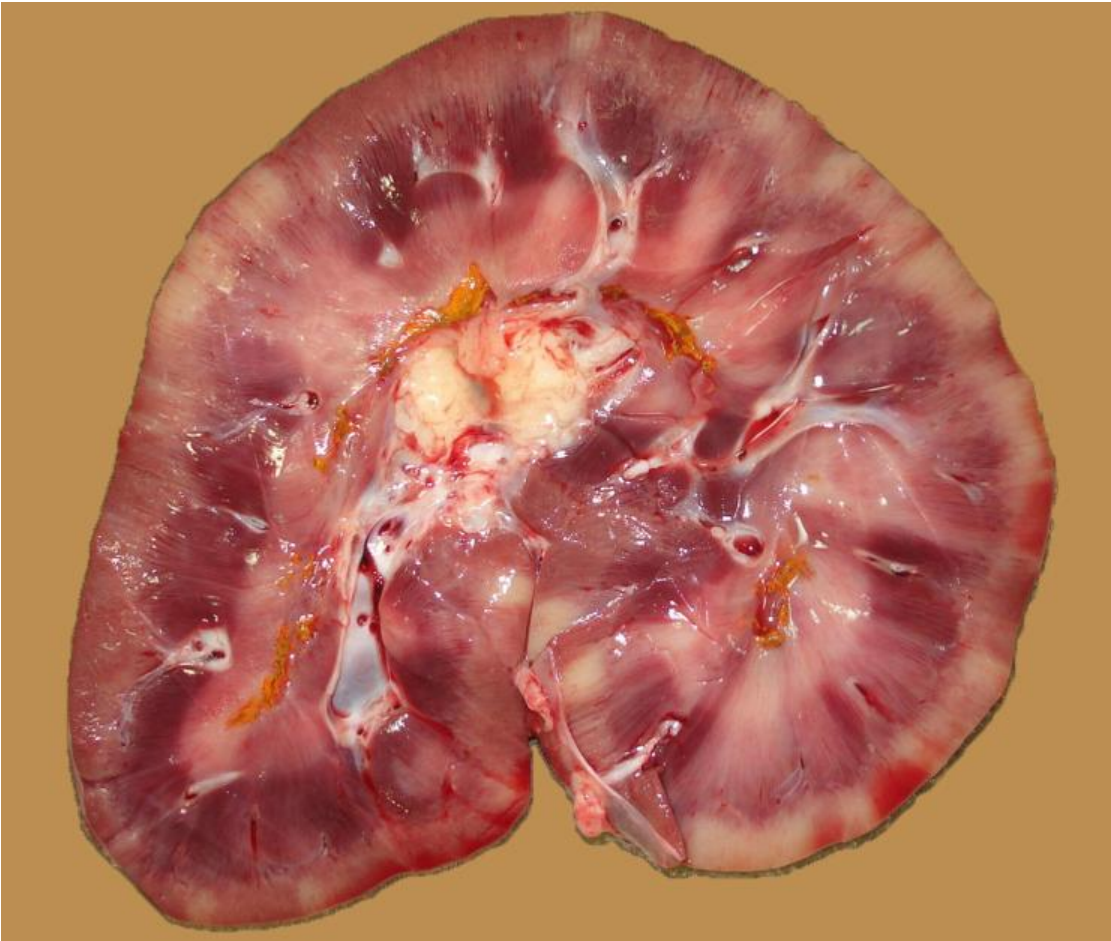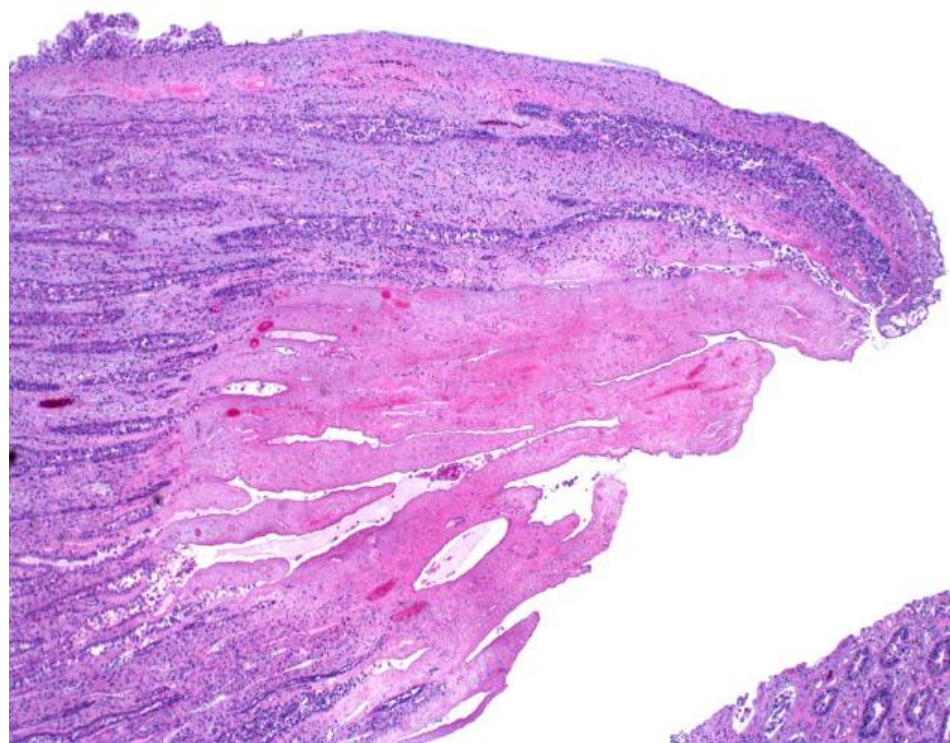




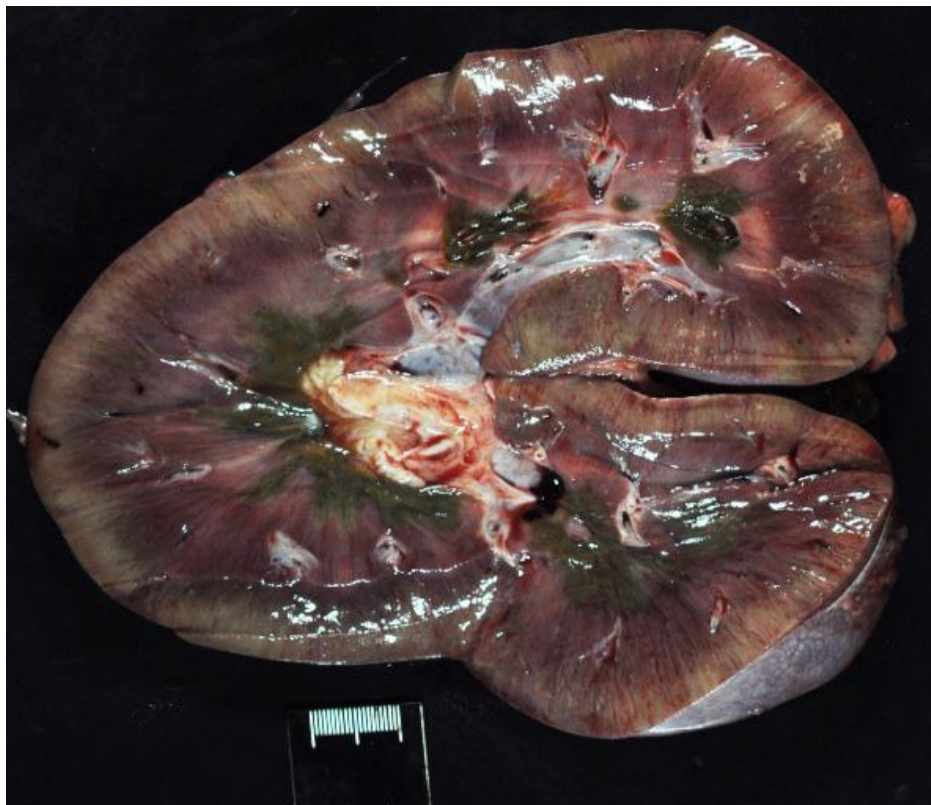







PATHOGENESIS

NSAIDs → inhibition COX 2 →

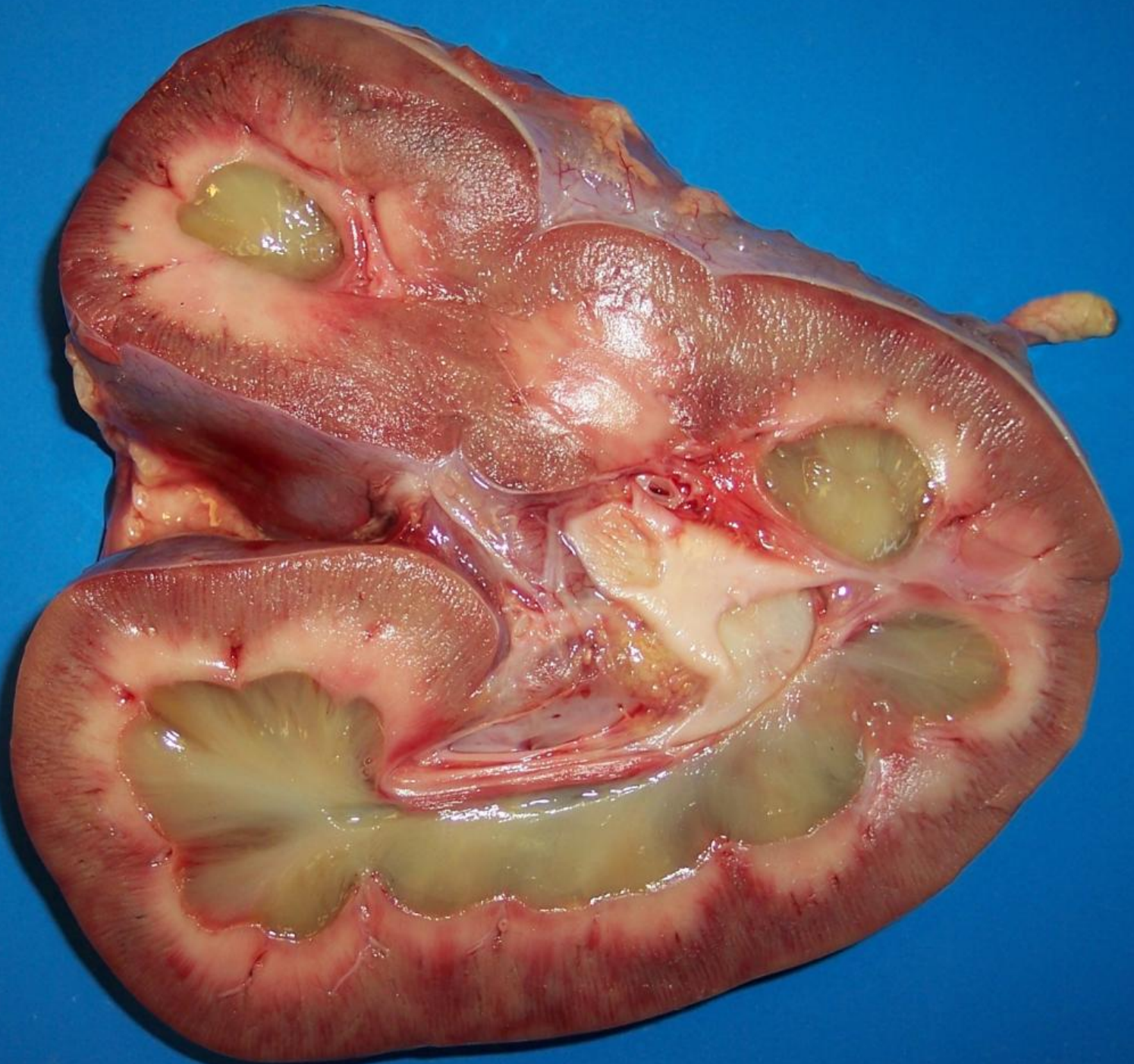
reduction Pg E₂ production →

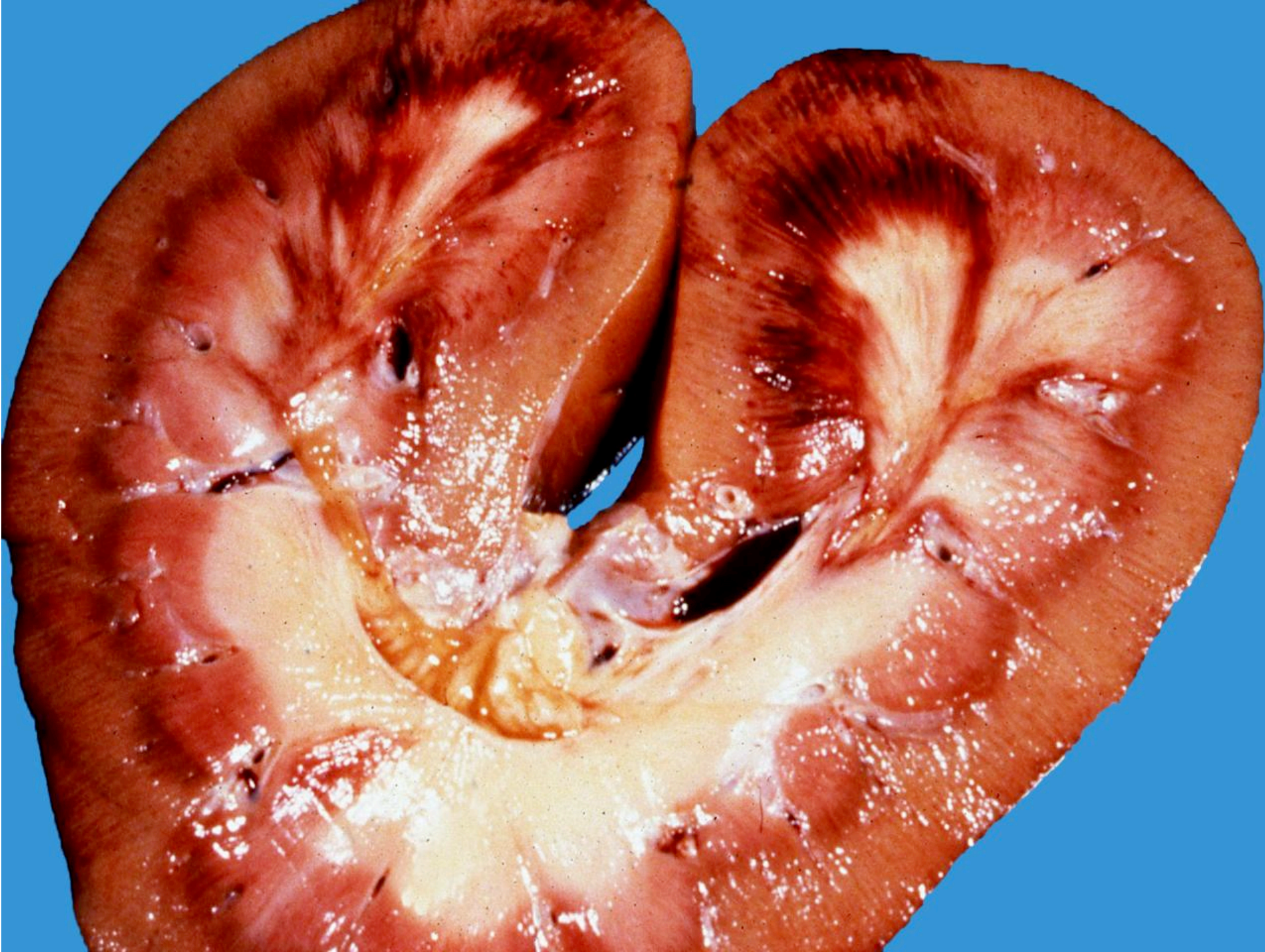ischemia →

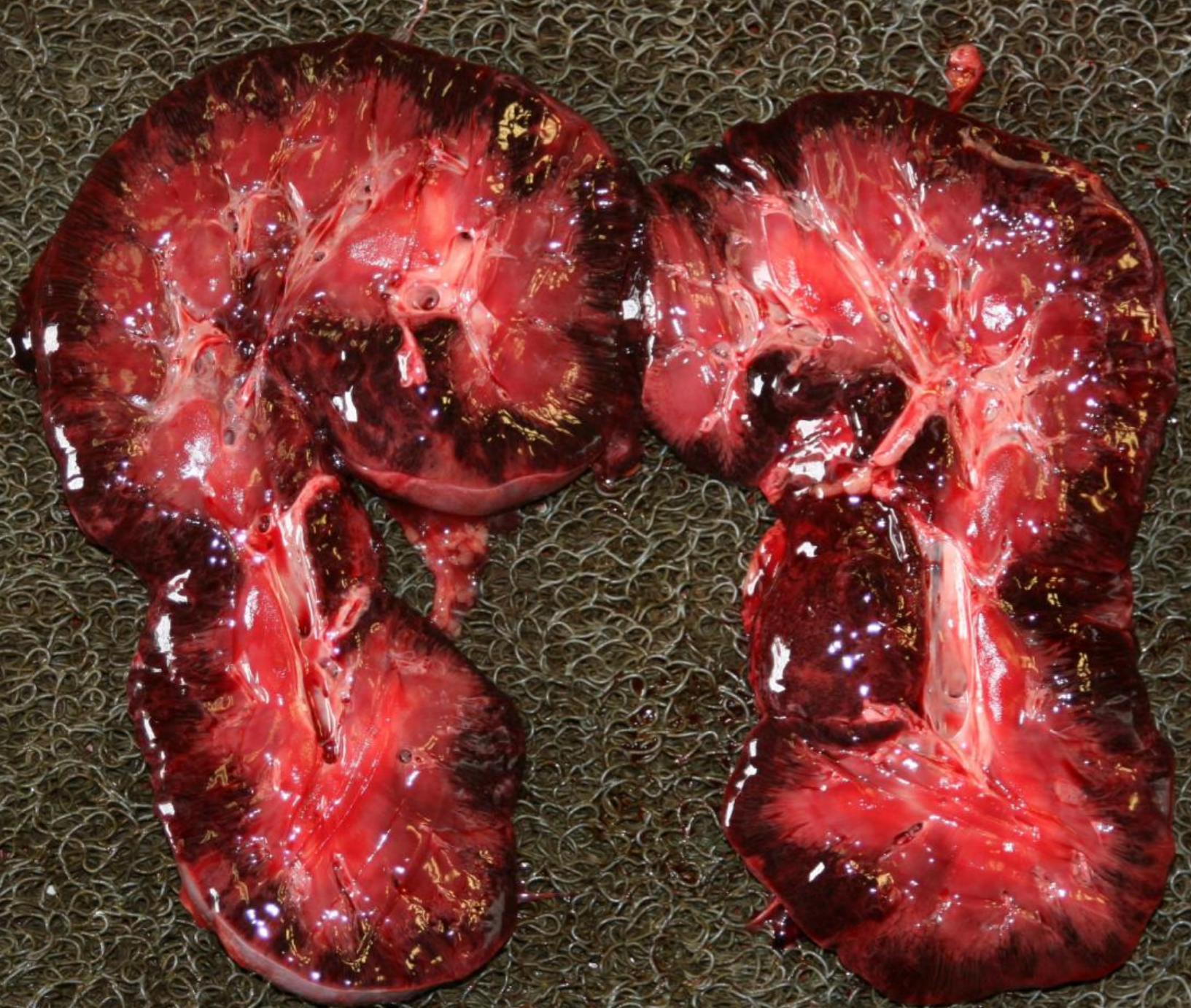
necrosis, ulceration

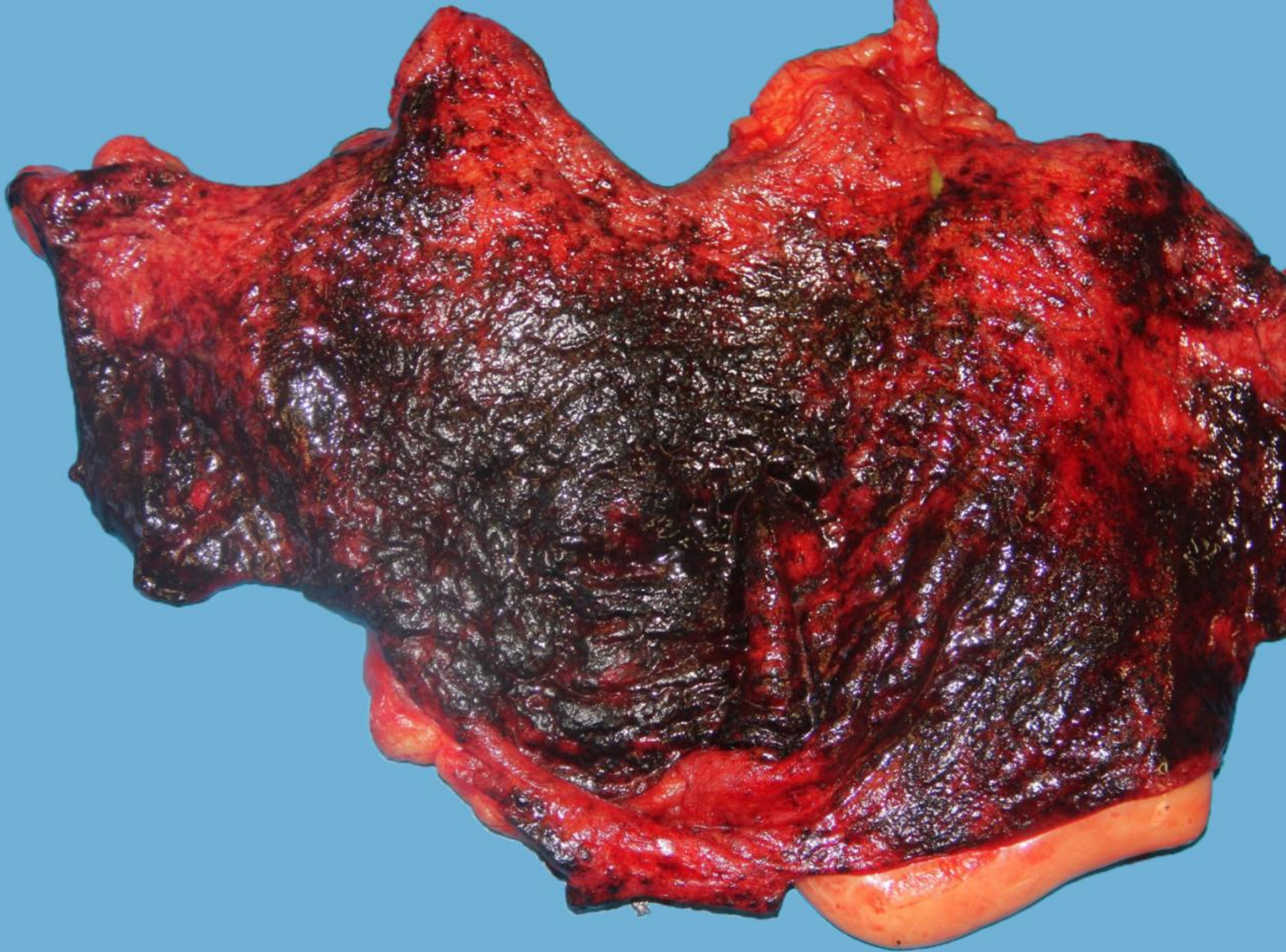
NSAIDs

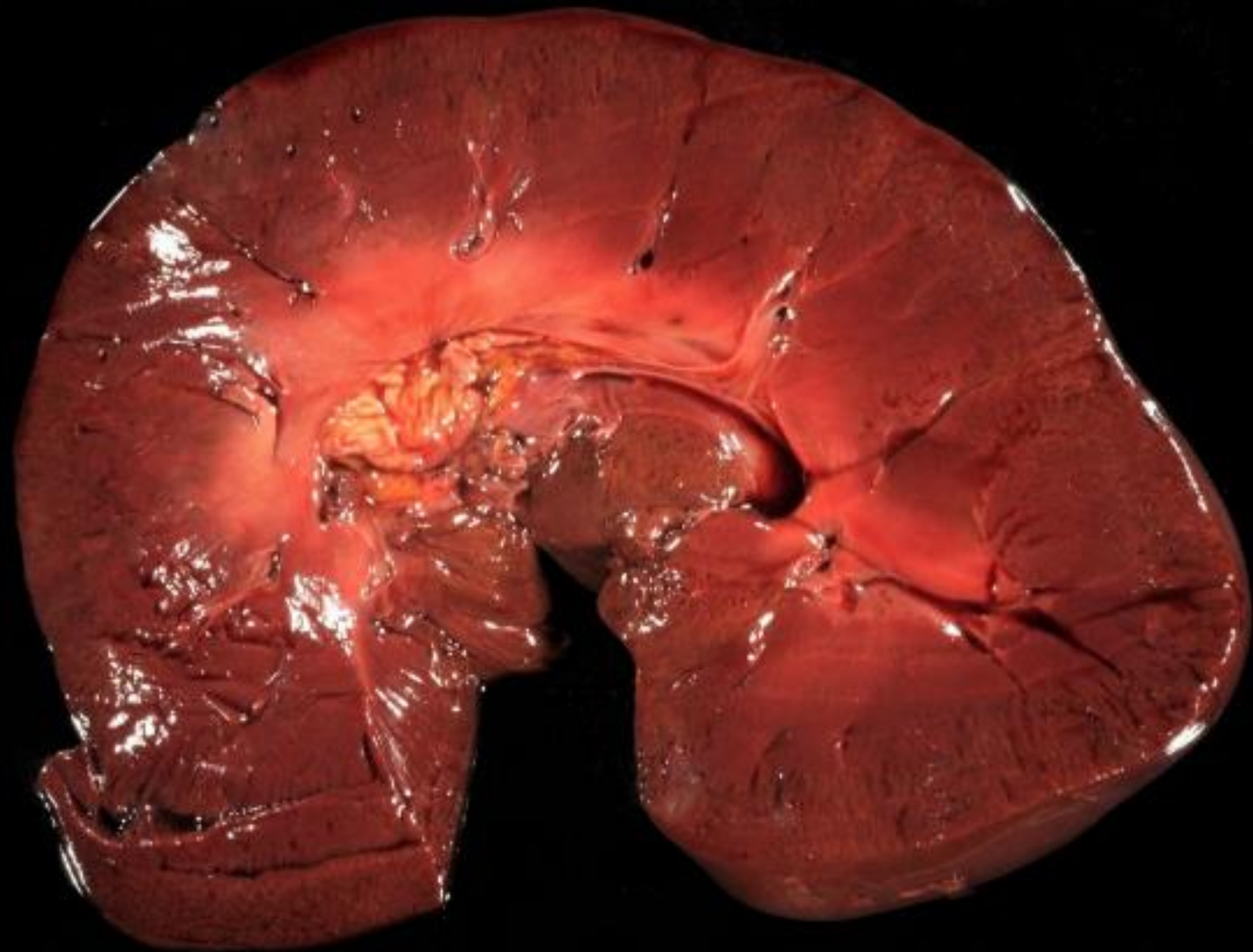- *Right dorsal colitis**
- *Renal papillary necrosis**
- *Gastric ulceration**

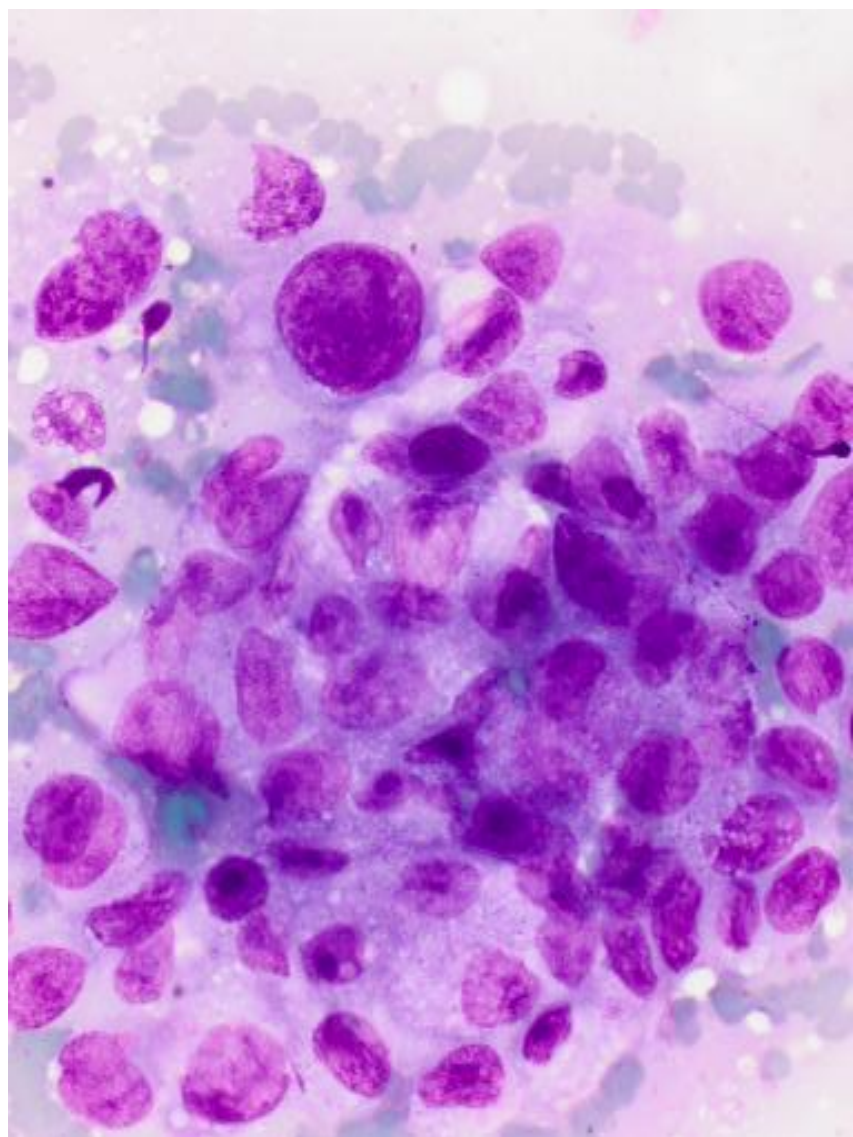
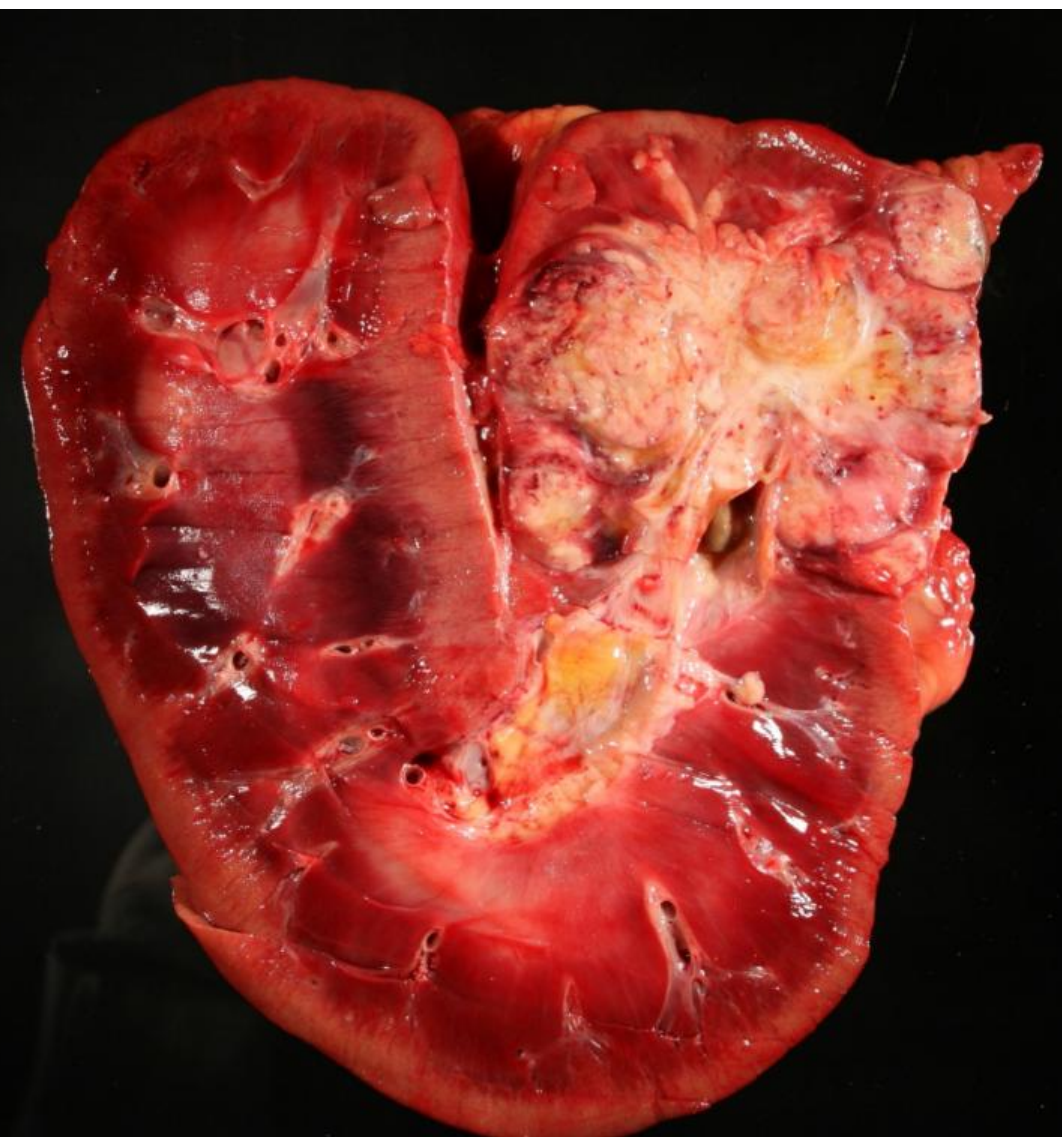


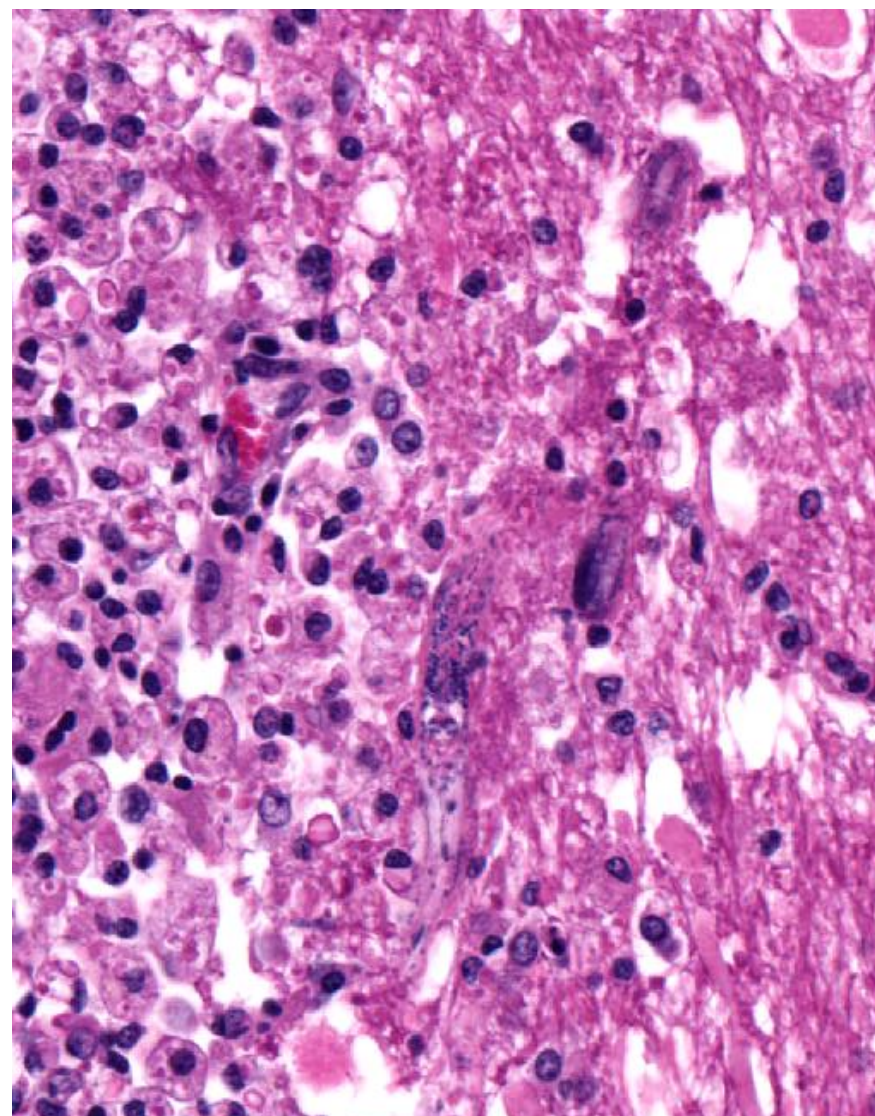
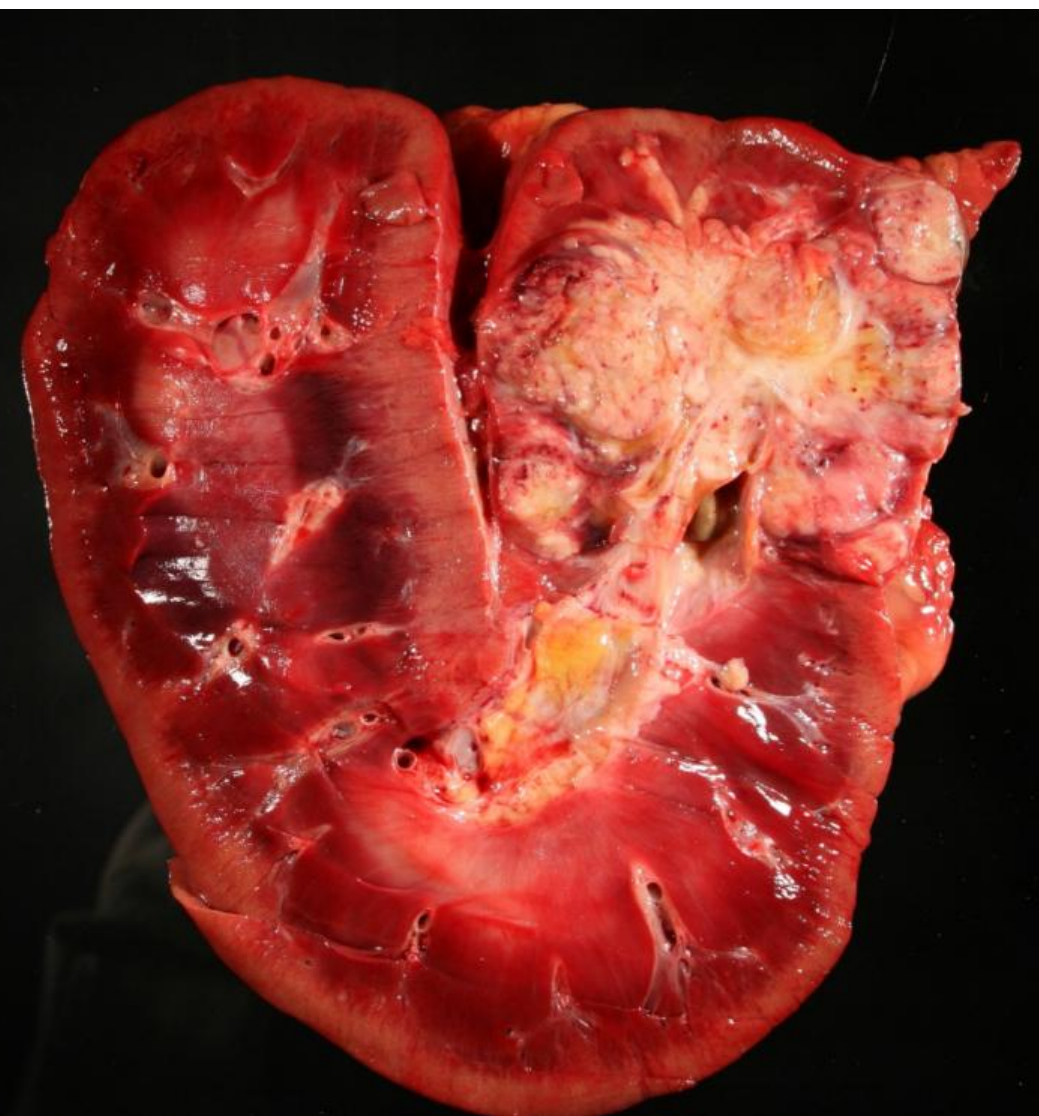












Thank you!!!

