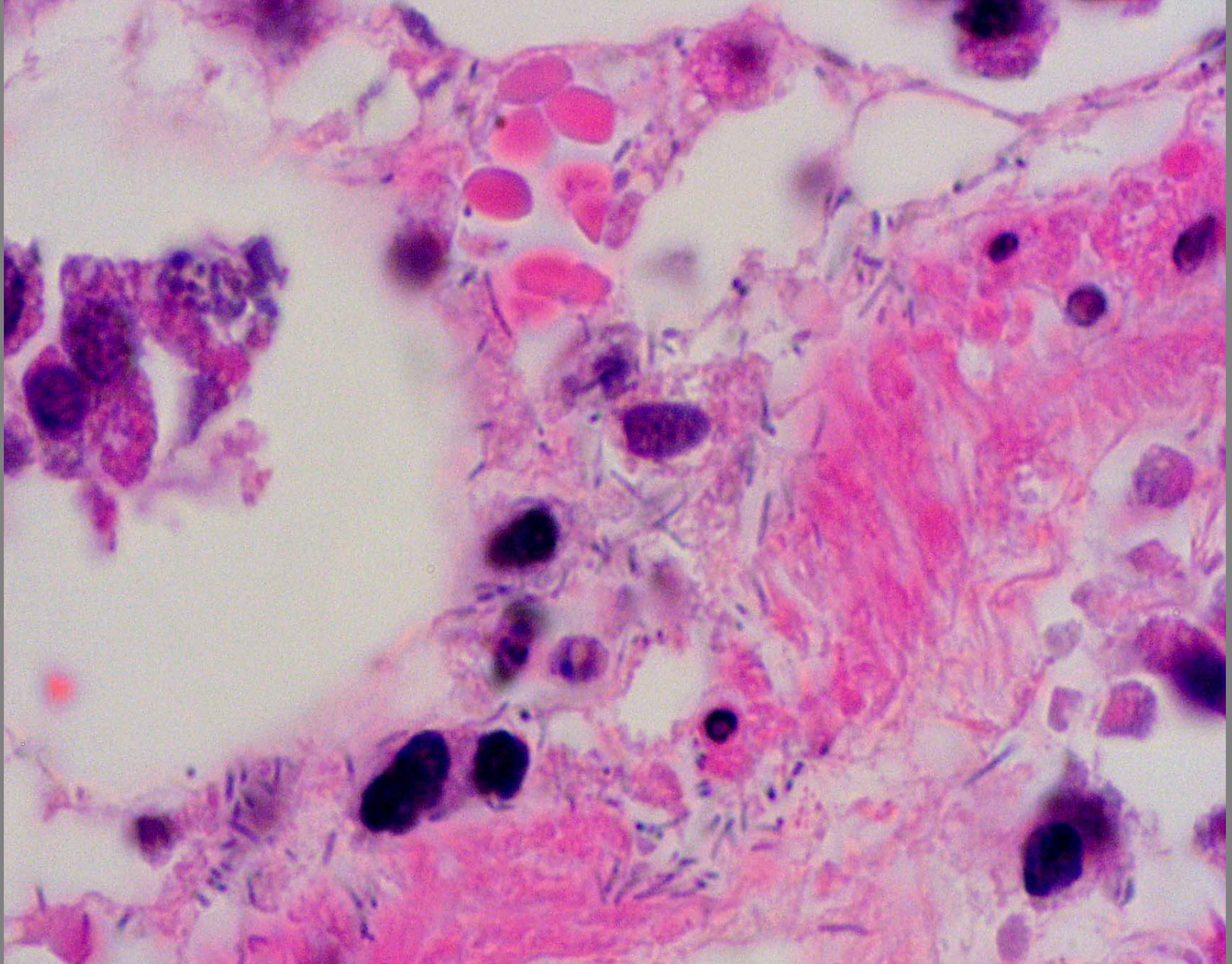
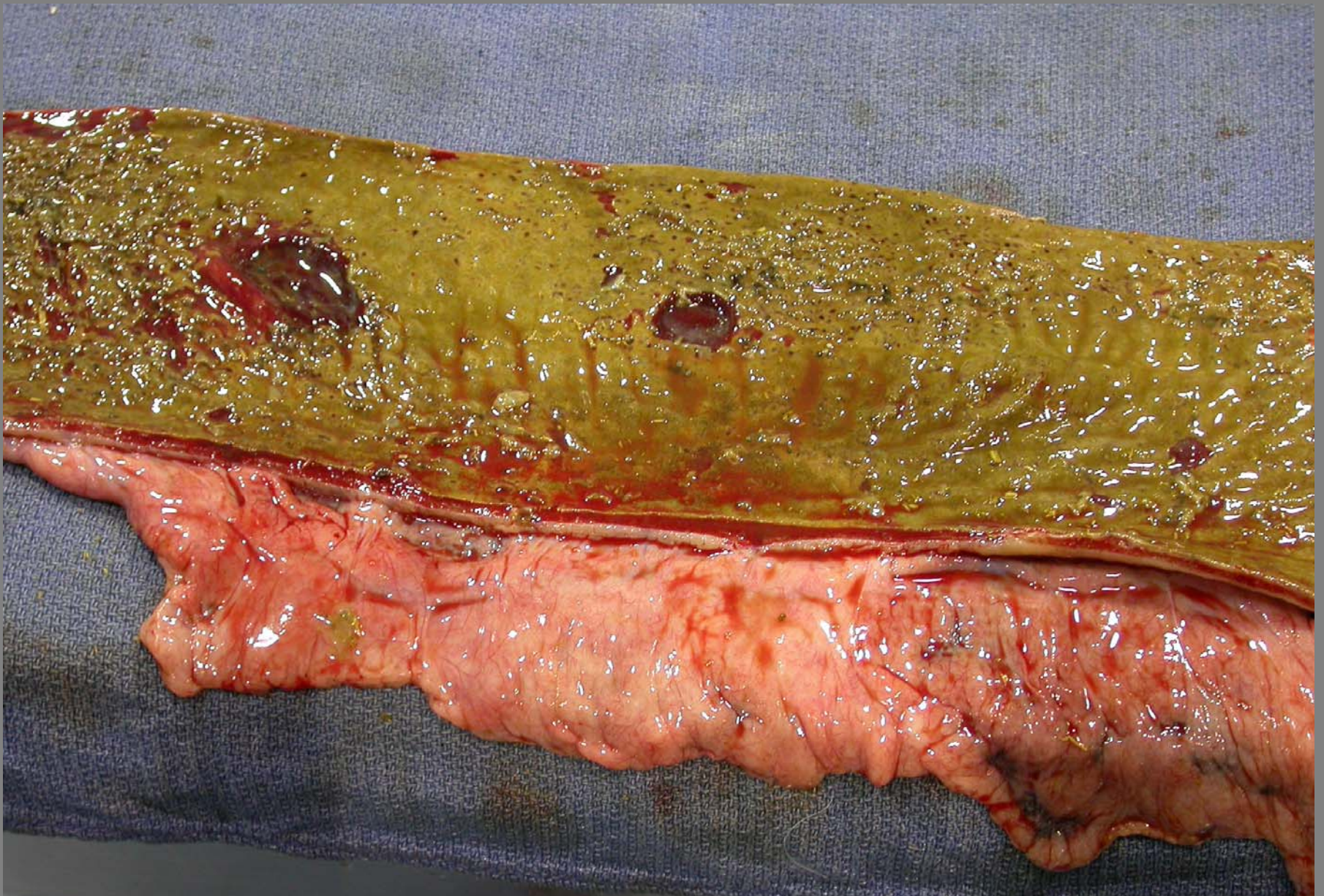




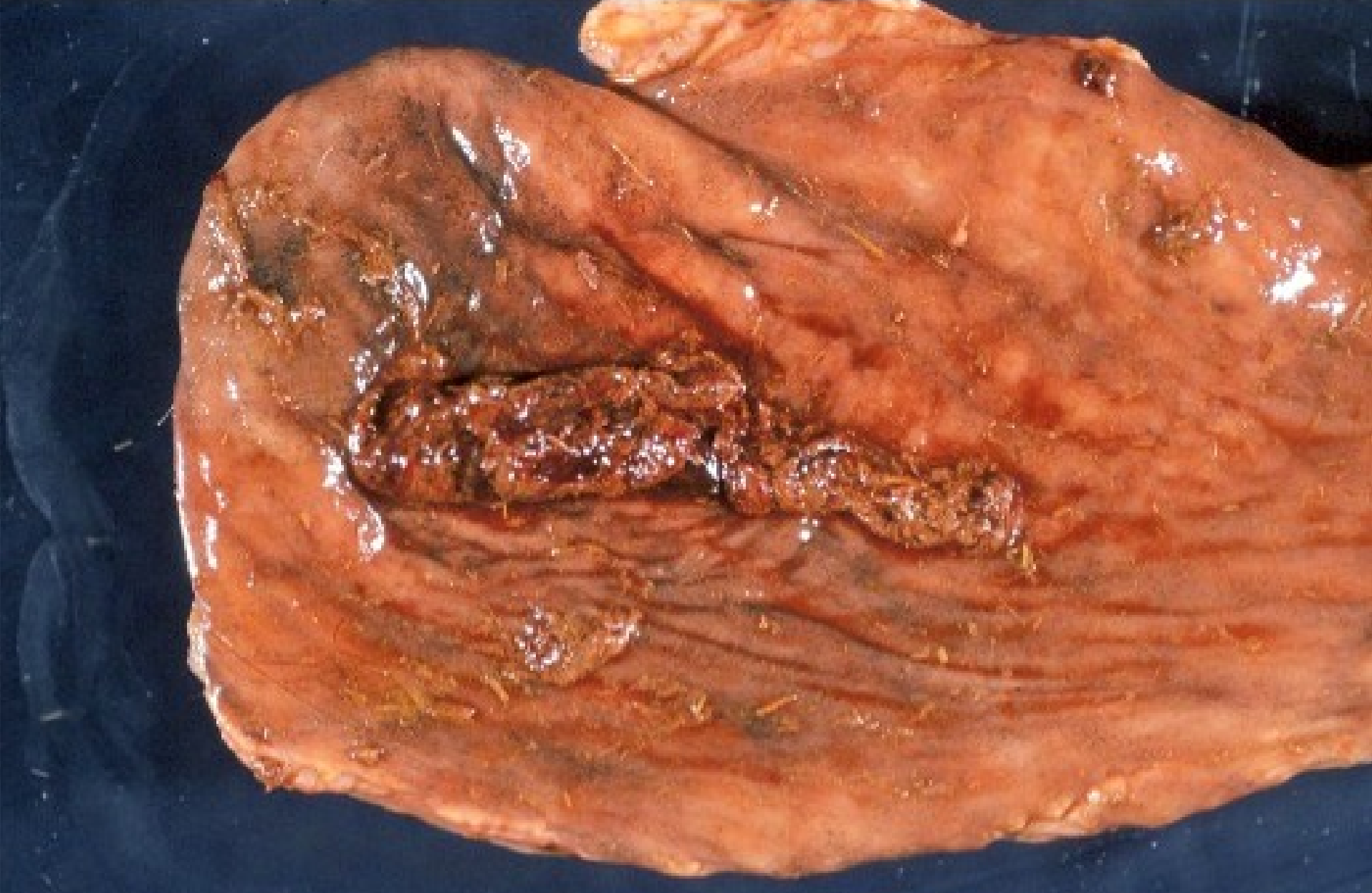
**Small intestine – acute hemorrhagic necrotic and fibrinous enteritis – *Clostridium* spp.**



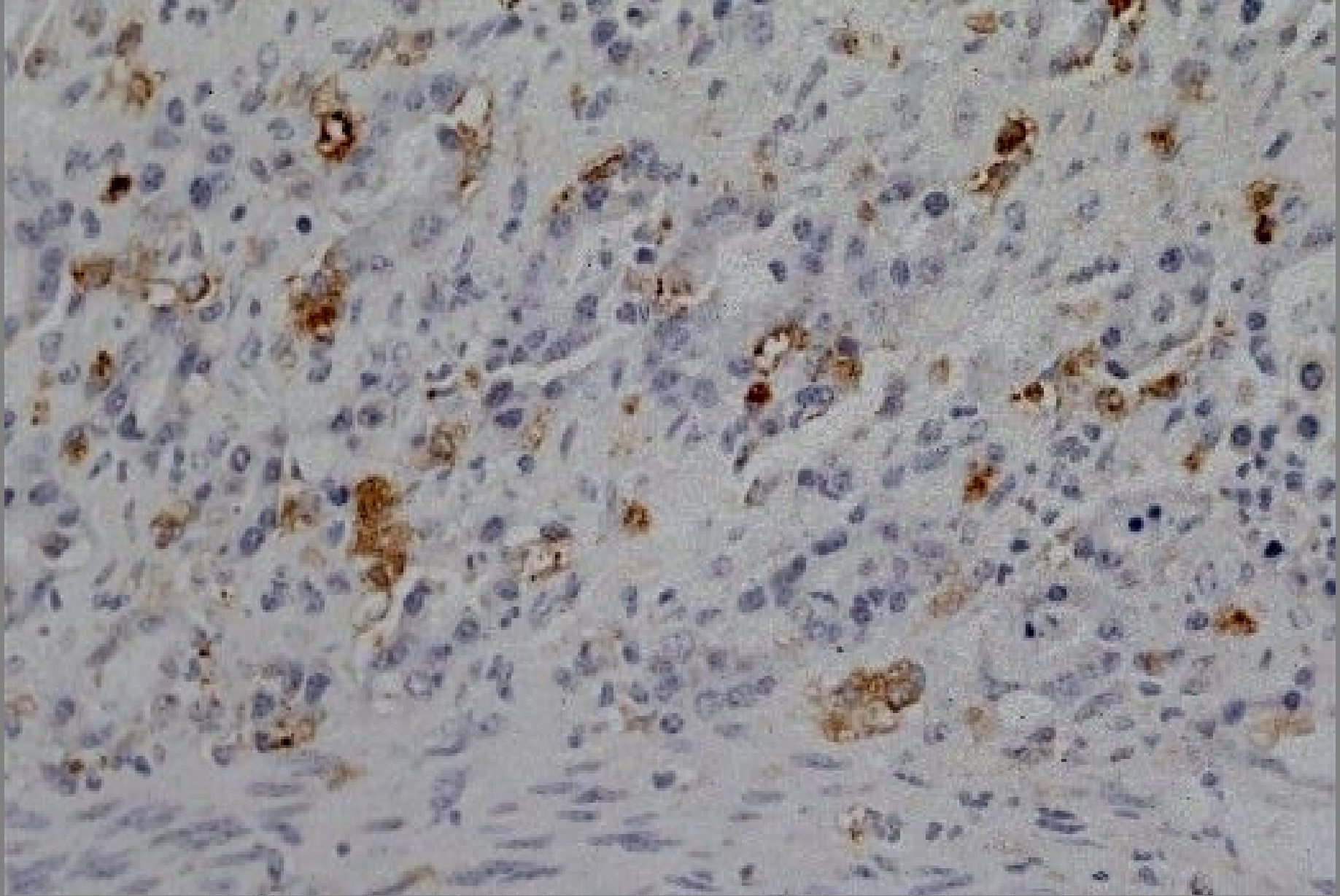
Small intestine – acute hemorrhagic necrotic and fibrinous enteritis – *Clostridium* spp.



**Alpaca – subacute necrotic and fibrinous (diphtheritic enterotyphlocolitis) – *Salmonella* spp. + *Clostridium* spp.**



**Cecum – fibrinous and necrotizing typhlitis with intraluminal cast - mucosal disease – BVD pestivirus**



**Intestine - crypt necrosis - mucosal disease – BVD  
pestivirus- IPIHC**