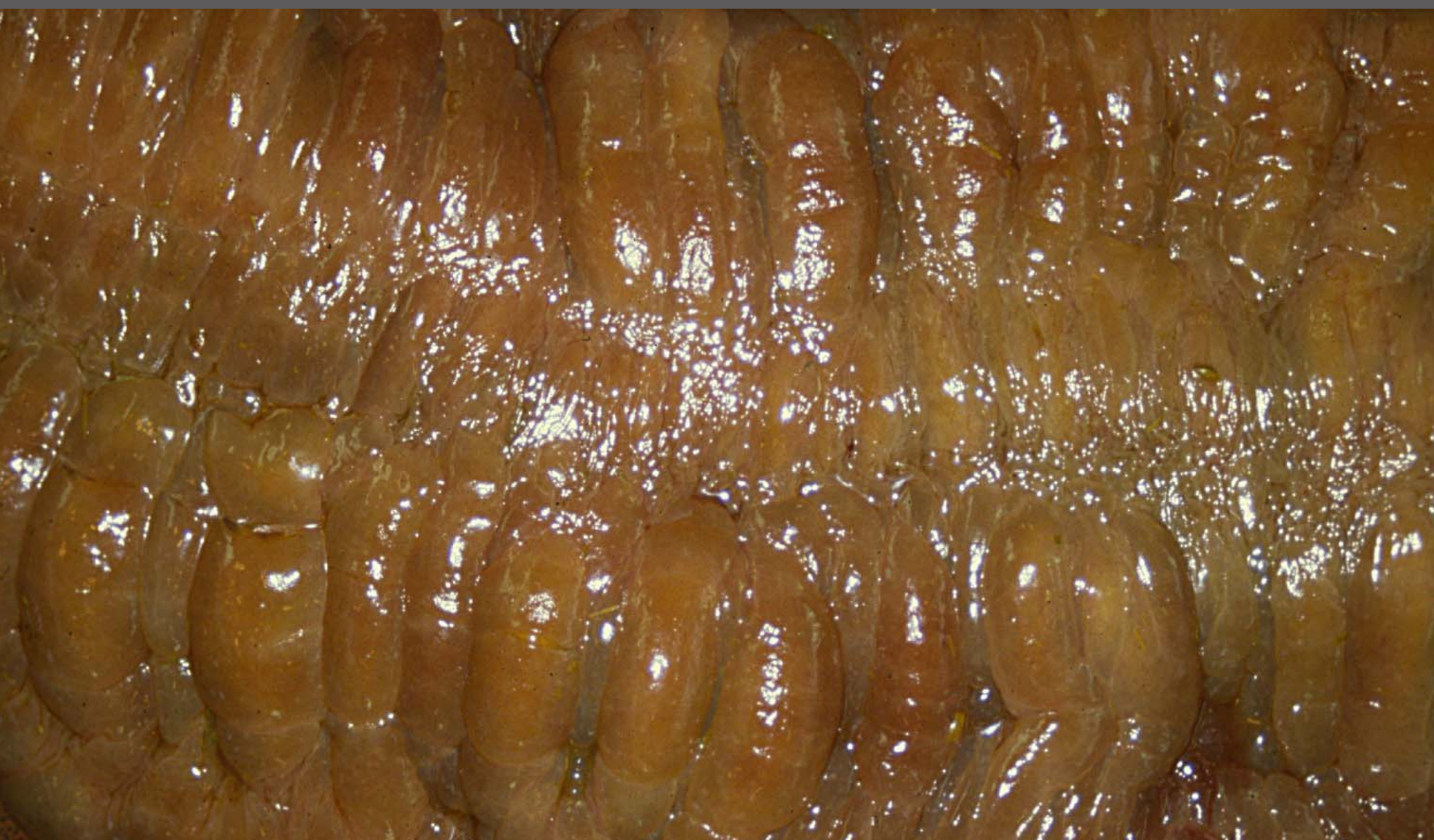
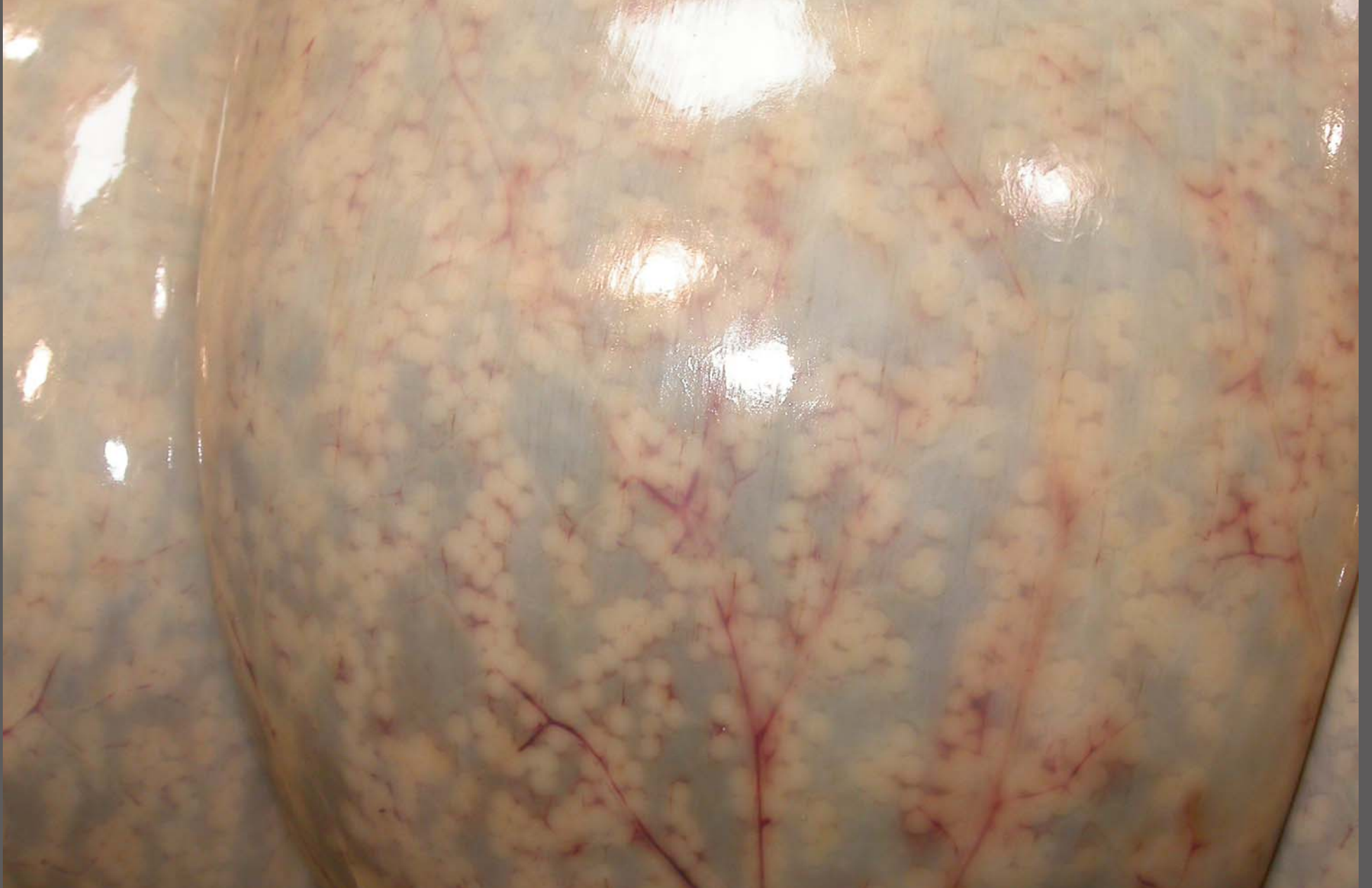


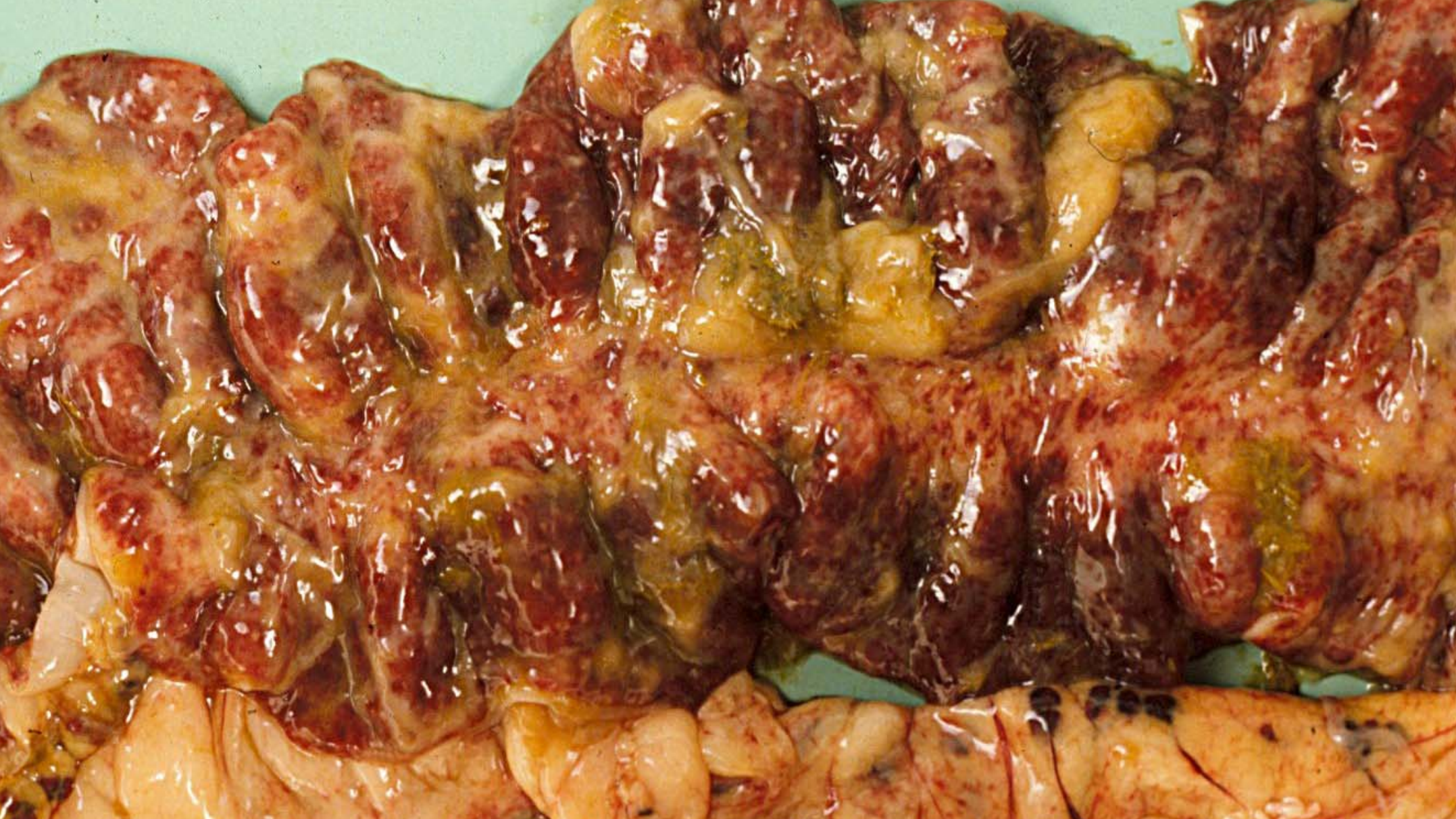Colon – severe edema – DD: displacement; Potomac horse fever; Salmonella; hypoproteinemia





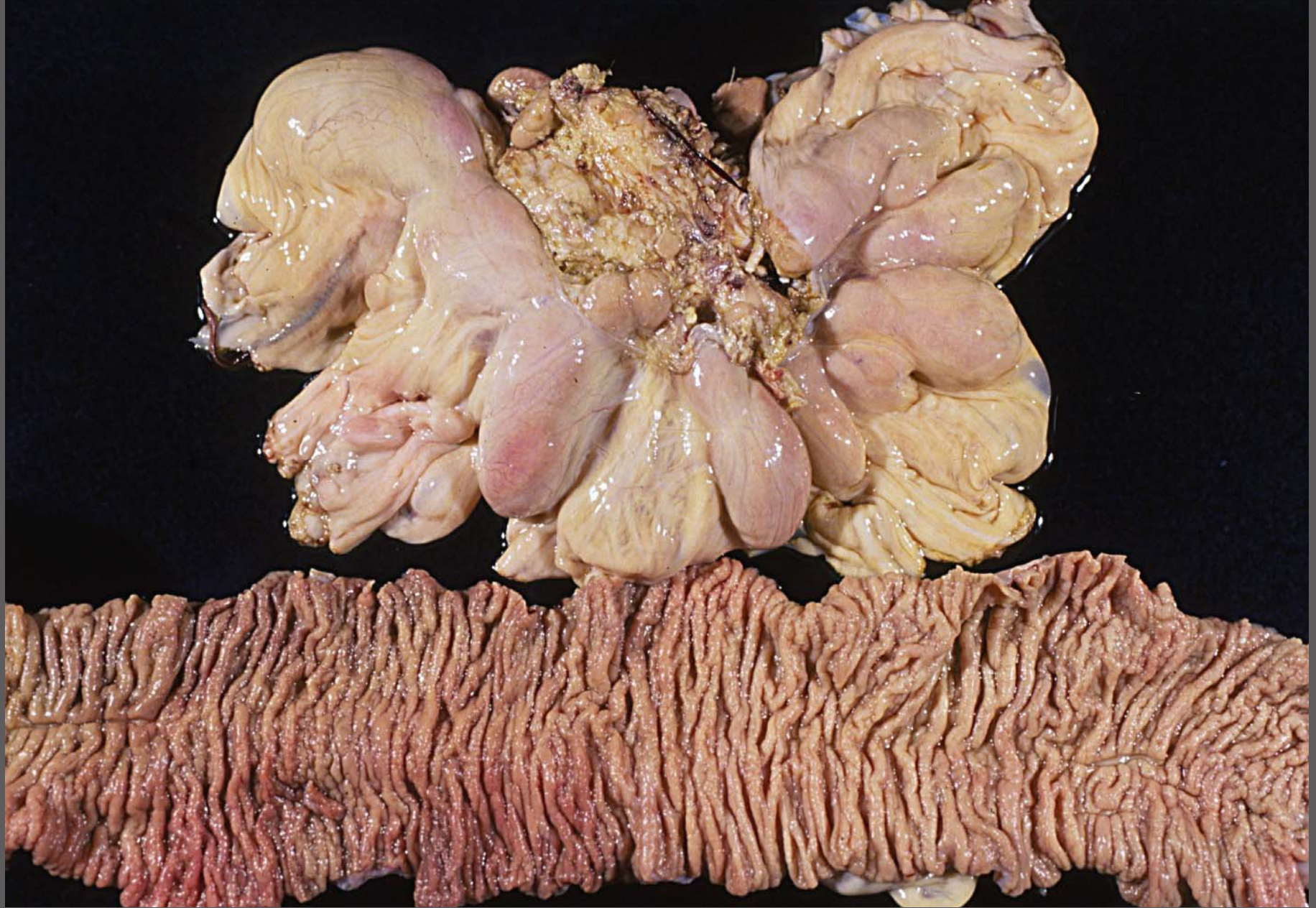
Foal – Large intestine – GALT hyperplasia – DD: unknown; chronic infection; Salmonella.





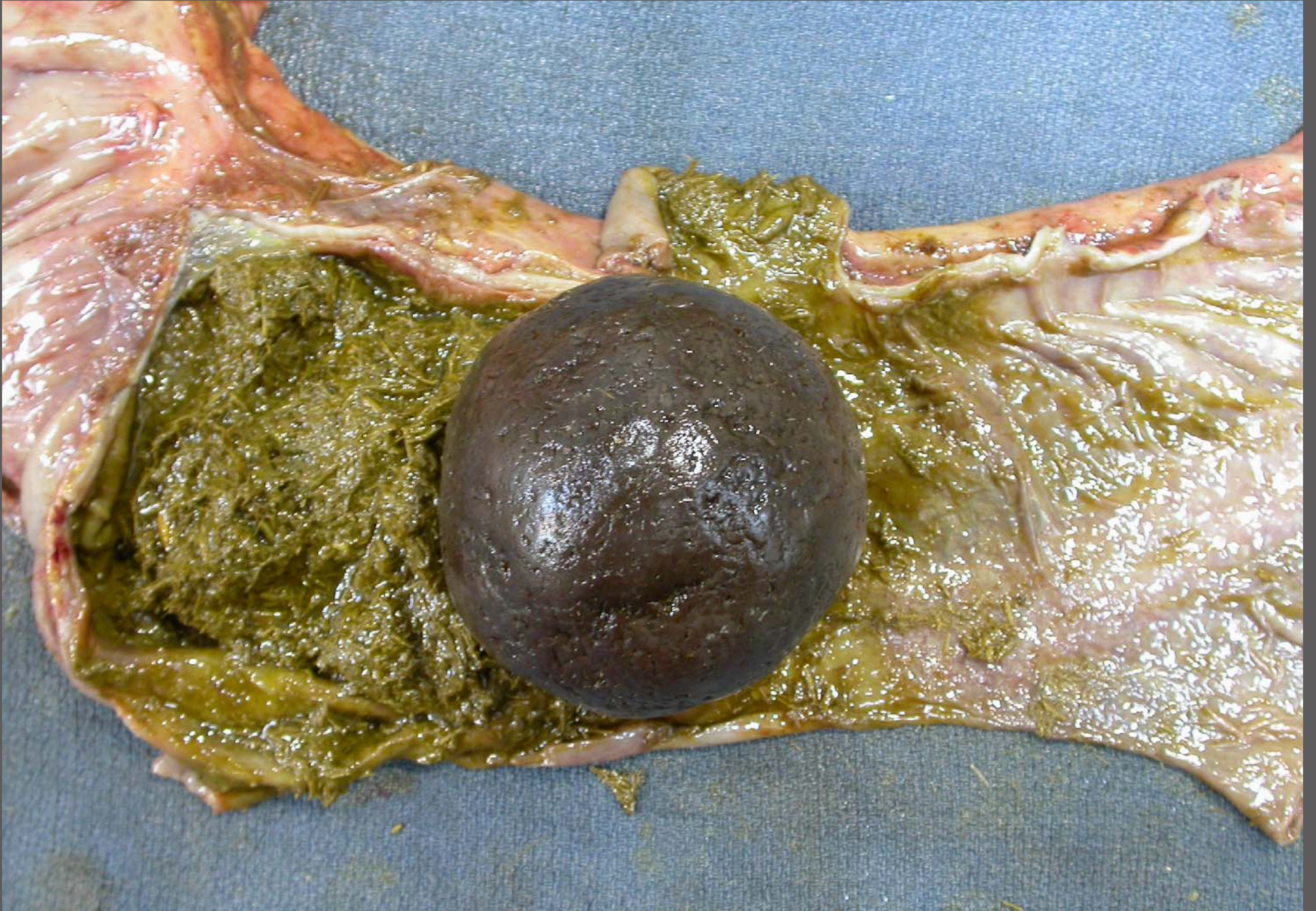Foal – Large intestine – severe acute systemic hemorrhage – purpura hemorrhagica (University of Milano – Prof. M. Finazzi)





Small intestine and mesenteric lymph nodes – lymphoma – DD:  
granulomatous enteritis





Pelvic flexure – lithobezoar with focal compression, necrosis and rupture