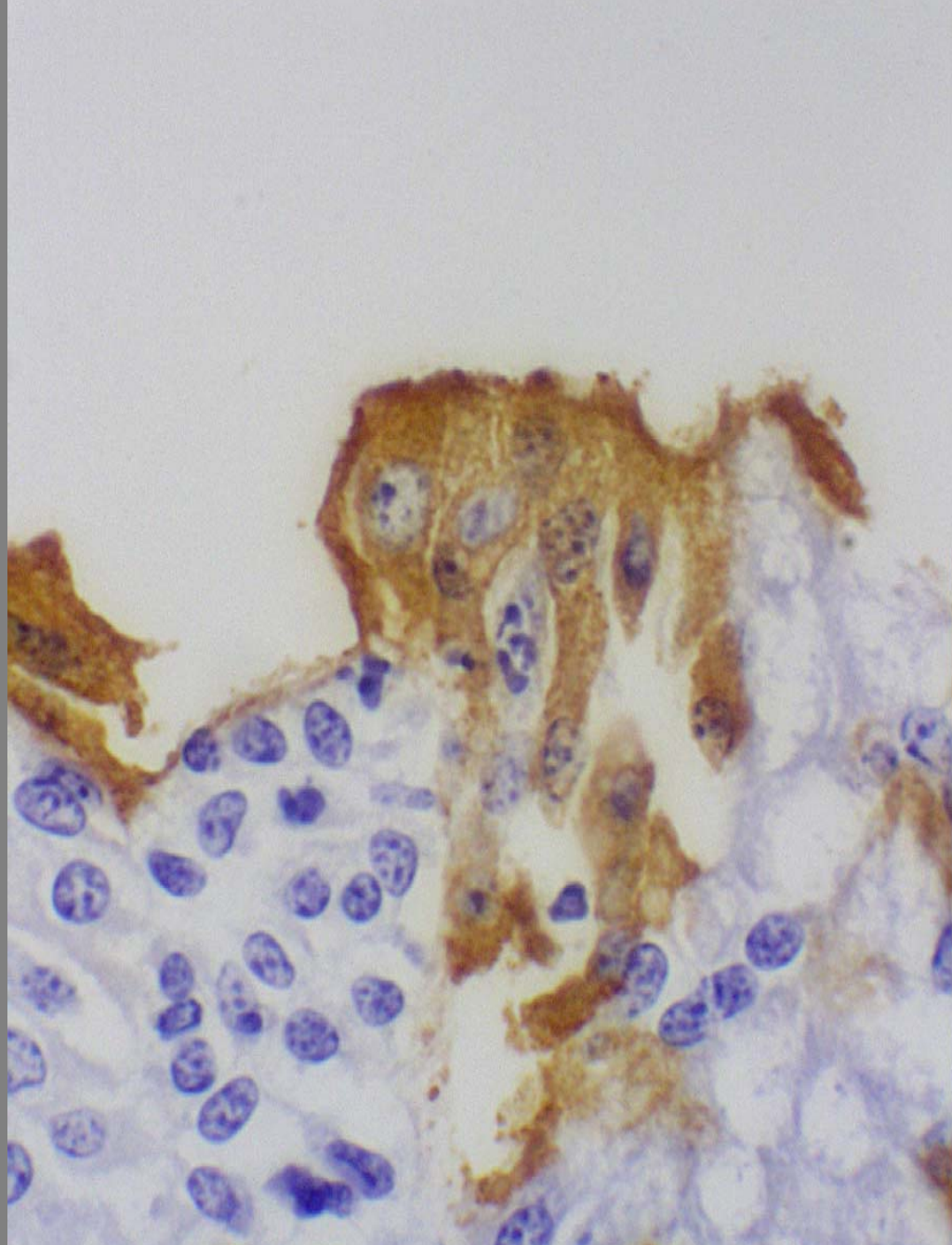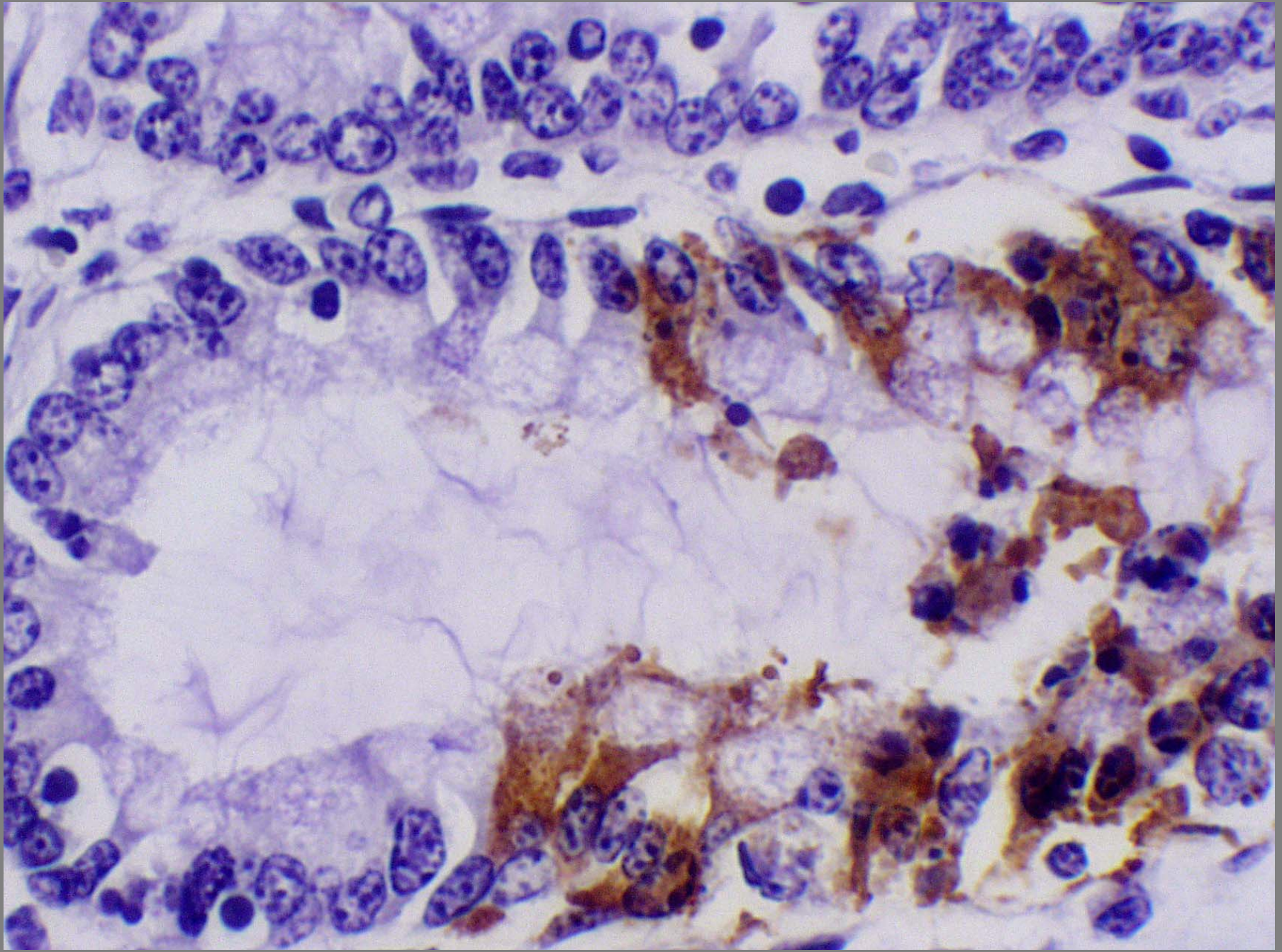
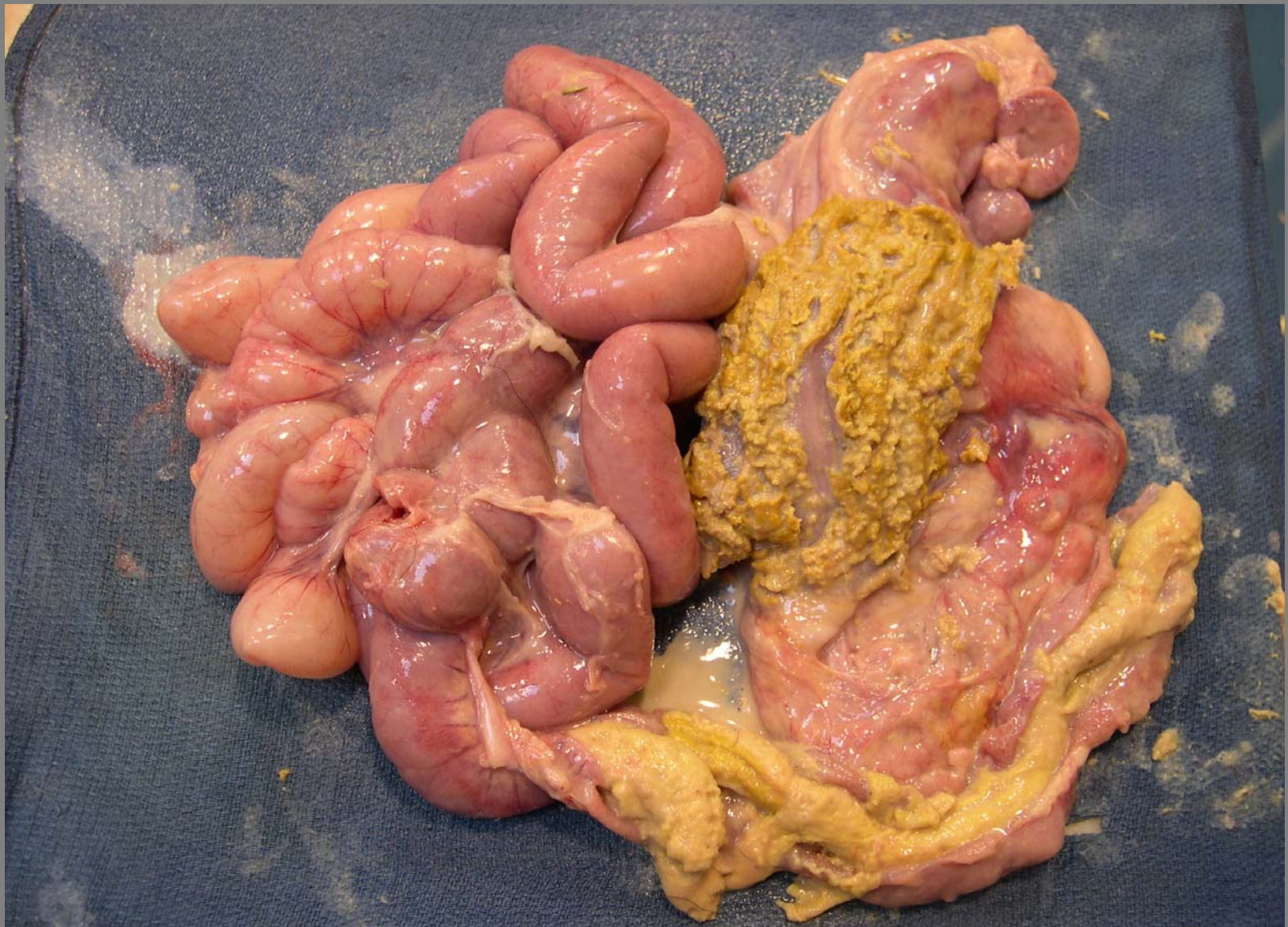


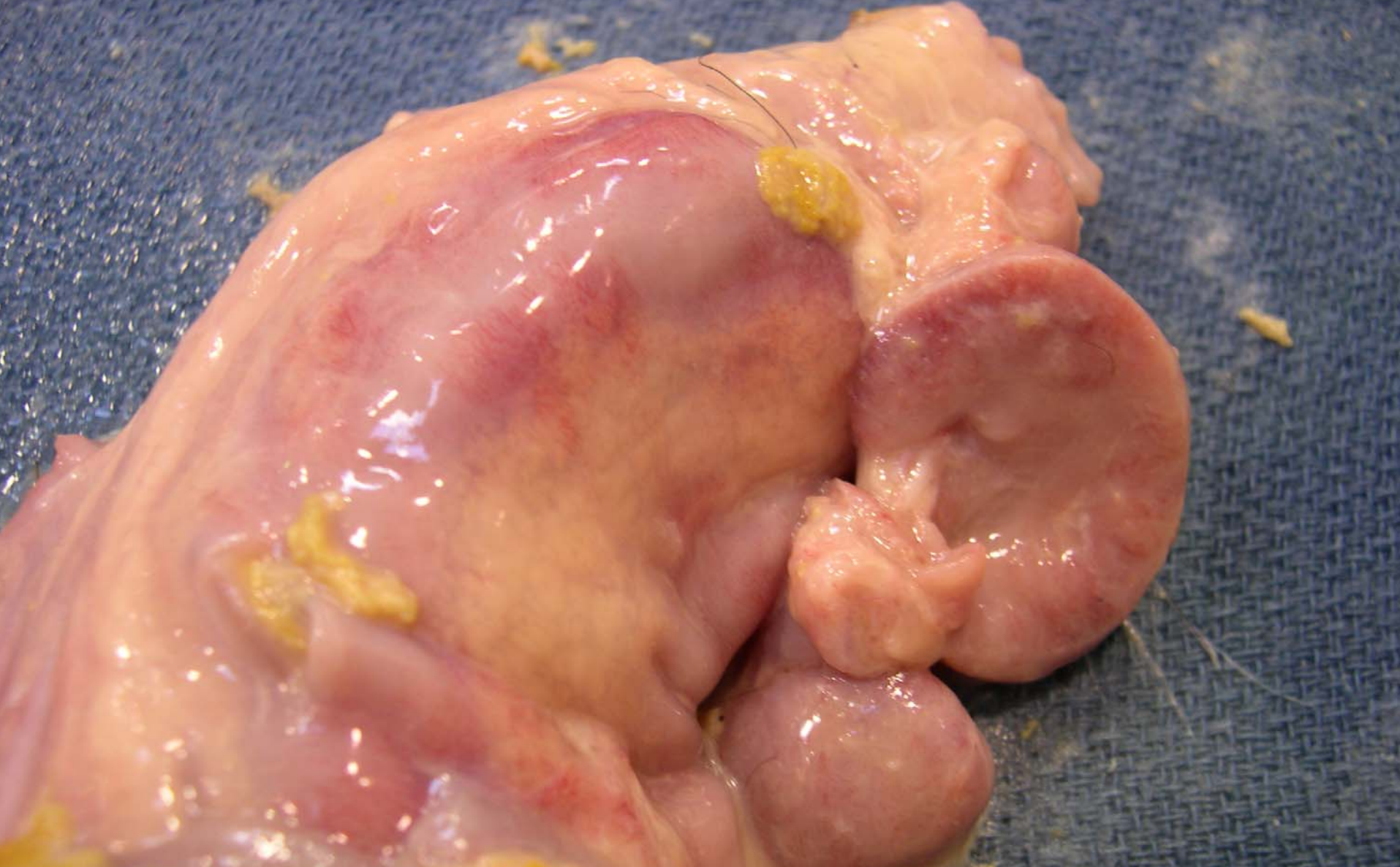Small intestine – rotavirus in apical enterocytes



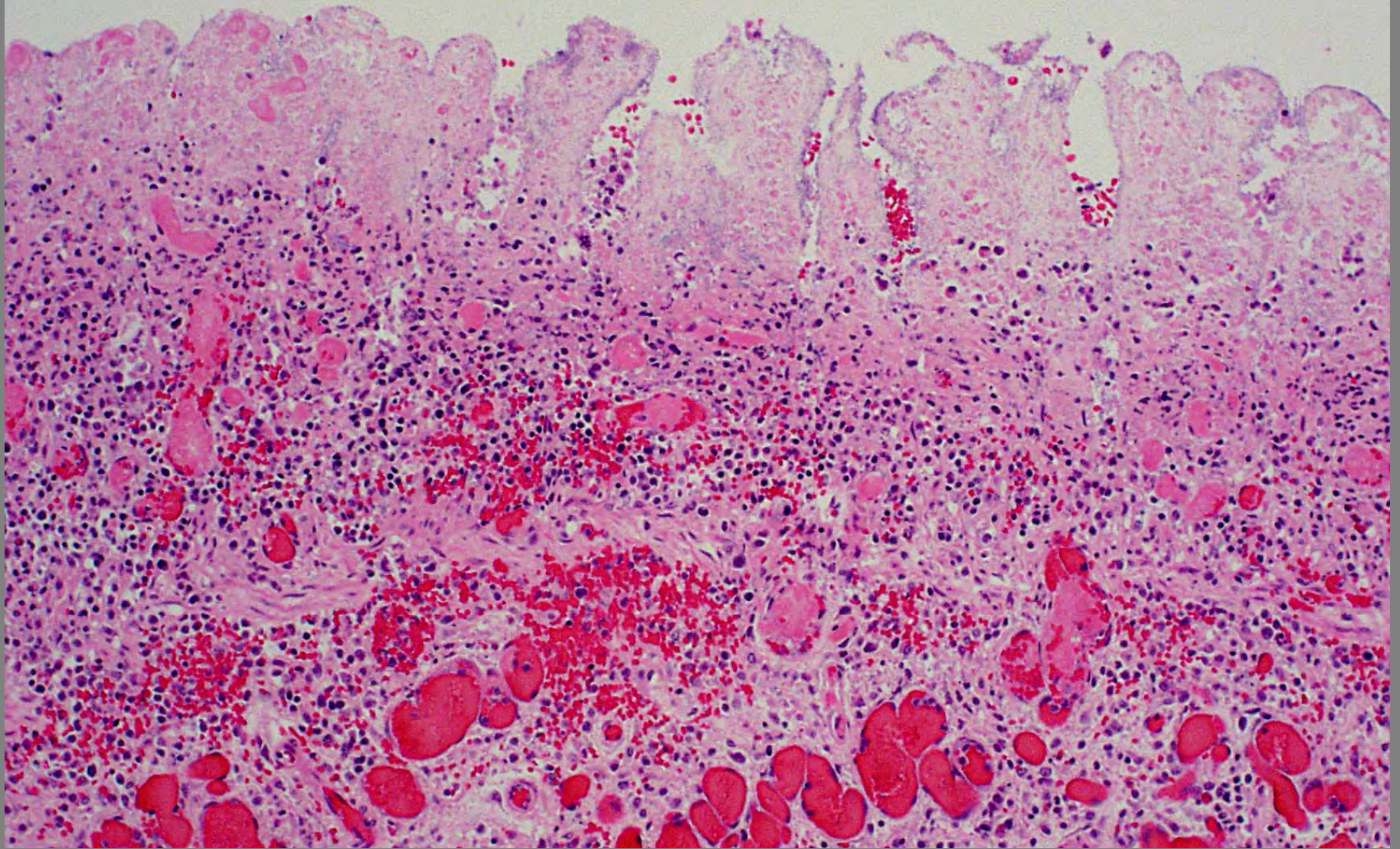
Large intestine – coronavirus in crypt enterocytes



Calf – fibrinonecrotic (diphtheritic) subacute to chronic enterotyphlocolitis with casts and lymphadenitis - *Salmonella enterica dublin* – 24 Dec 2005



Calf – fibrinonecrotic (diphtheritic) subacute to chronic enterotyphlocolitis with casts and lymphadenitis - *Salmonella enterica dublin* – 24 Dec 2005



Small intestine – necrotizing enteritis with thrombi
Salmonella