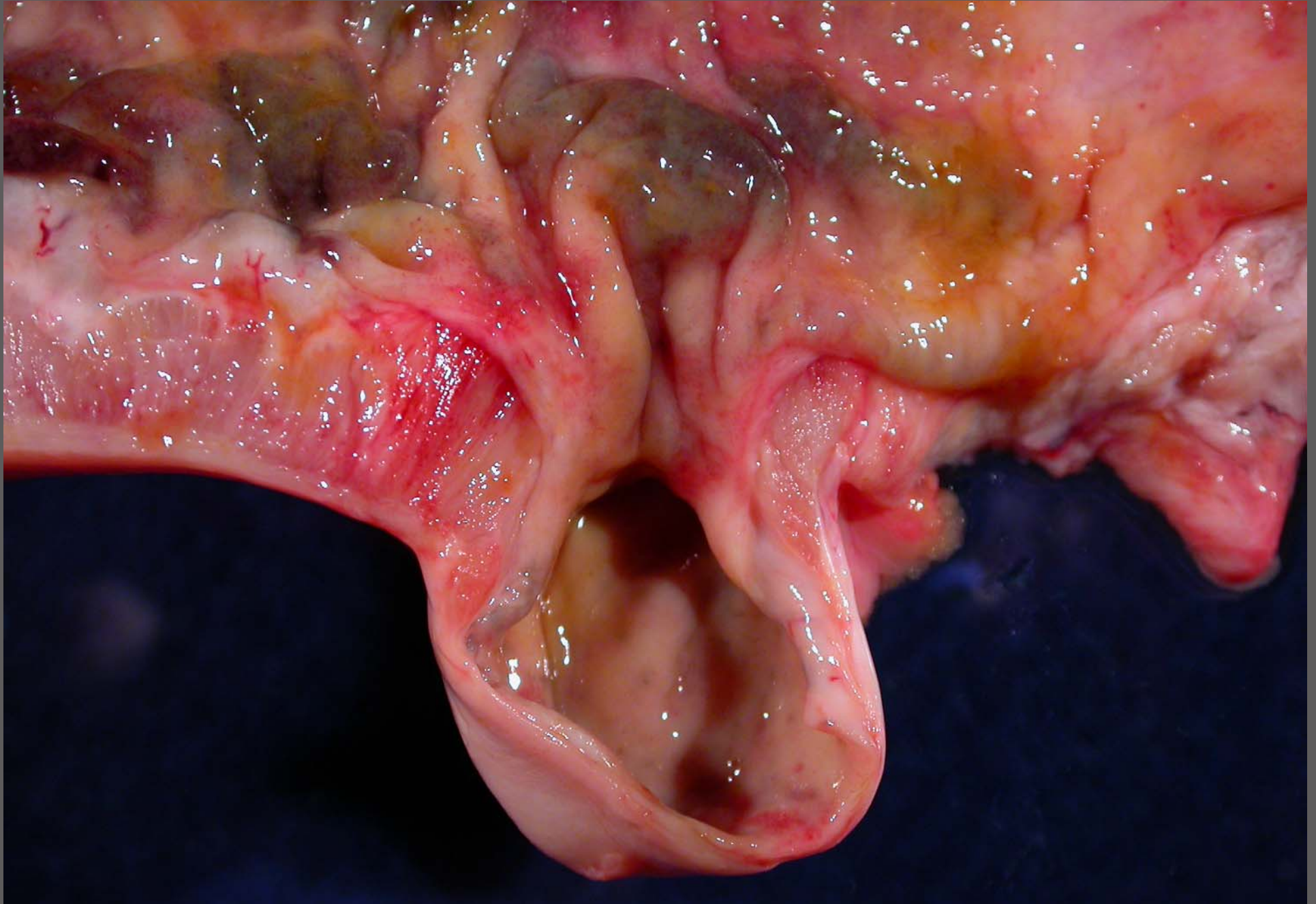
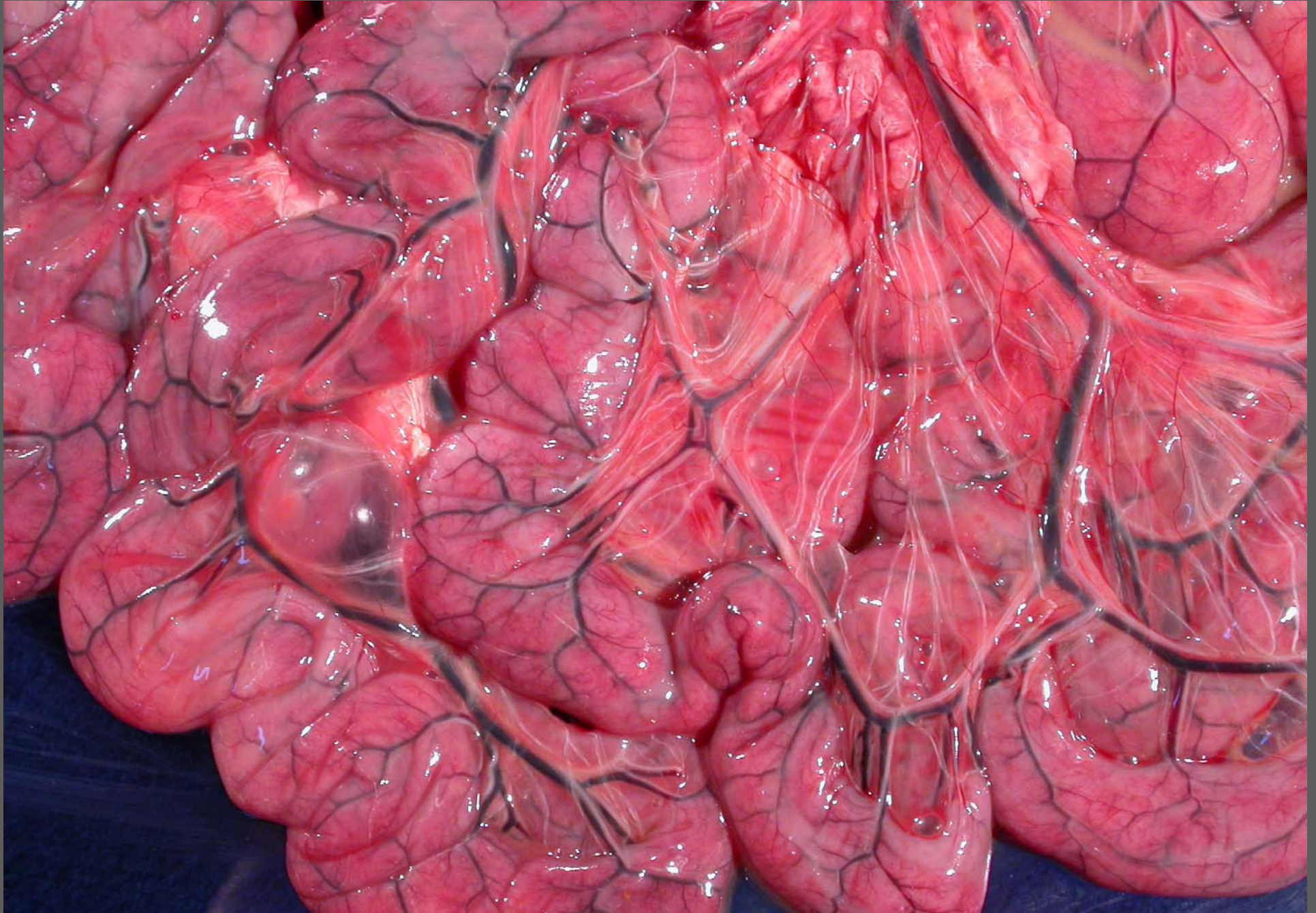


Ileum – hypertrophy/hyperplasia with diverticulum formation



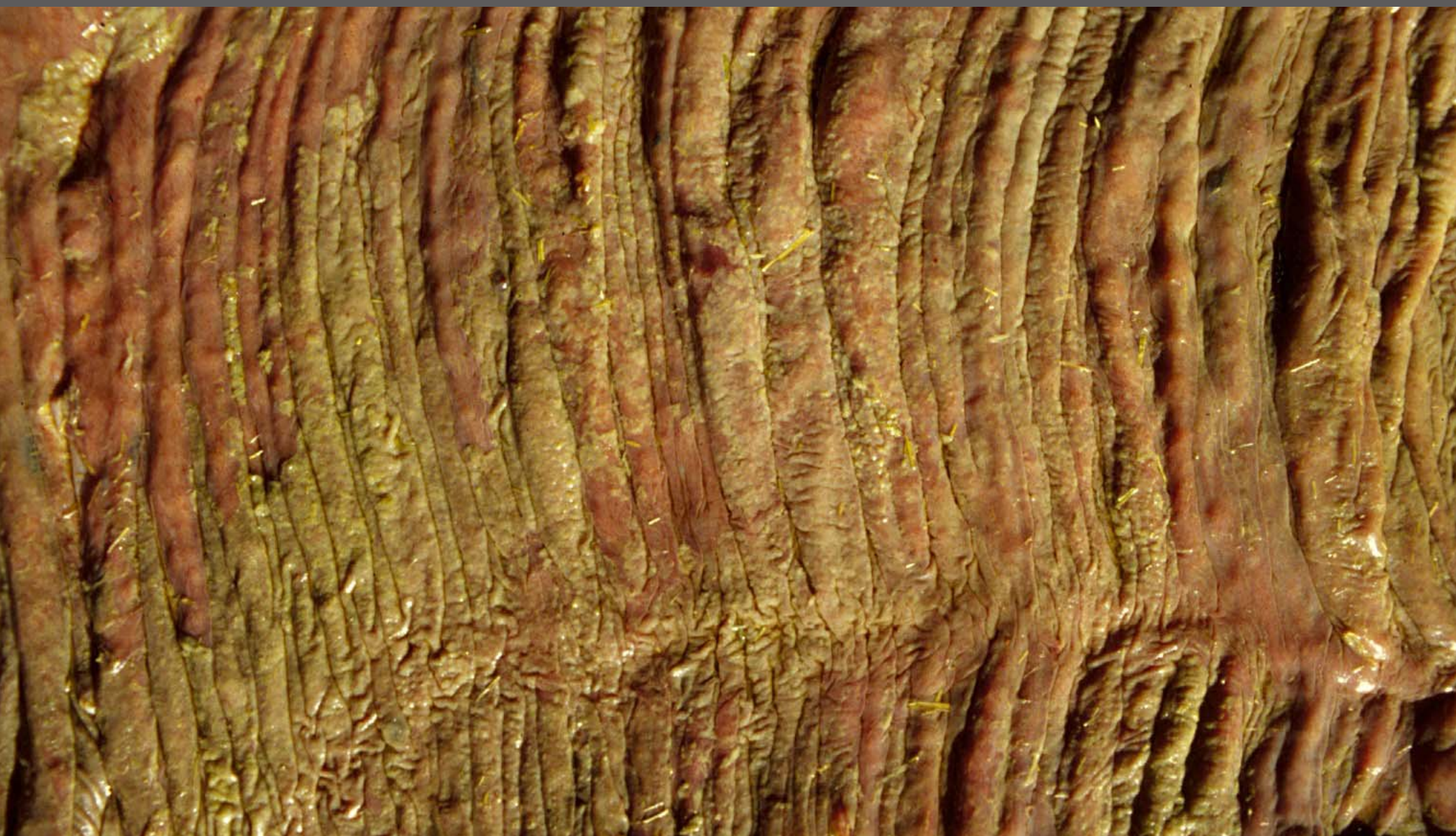
Foal – catarrhal and fibrinous enteritis – *Salmonella* spp.



Foal – catarrhal and fibrinous enteritis – *Salmonella* spp.



Large intestine – chronic necrotizing typhlocolitis –  
*Salmonella* spp.



Colon – necrotizing fibrinous colitis – DD: antimicrobial, *Salmonella* spp., *Clostridium* spp., other bacteria