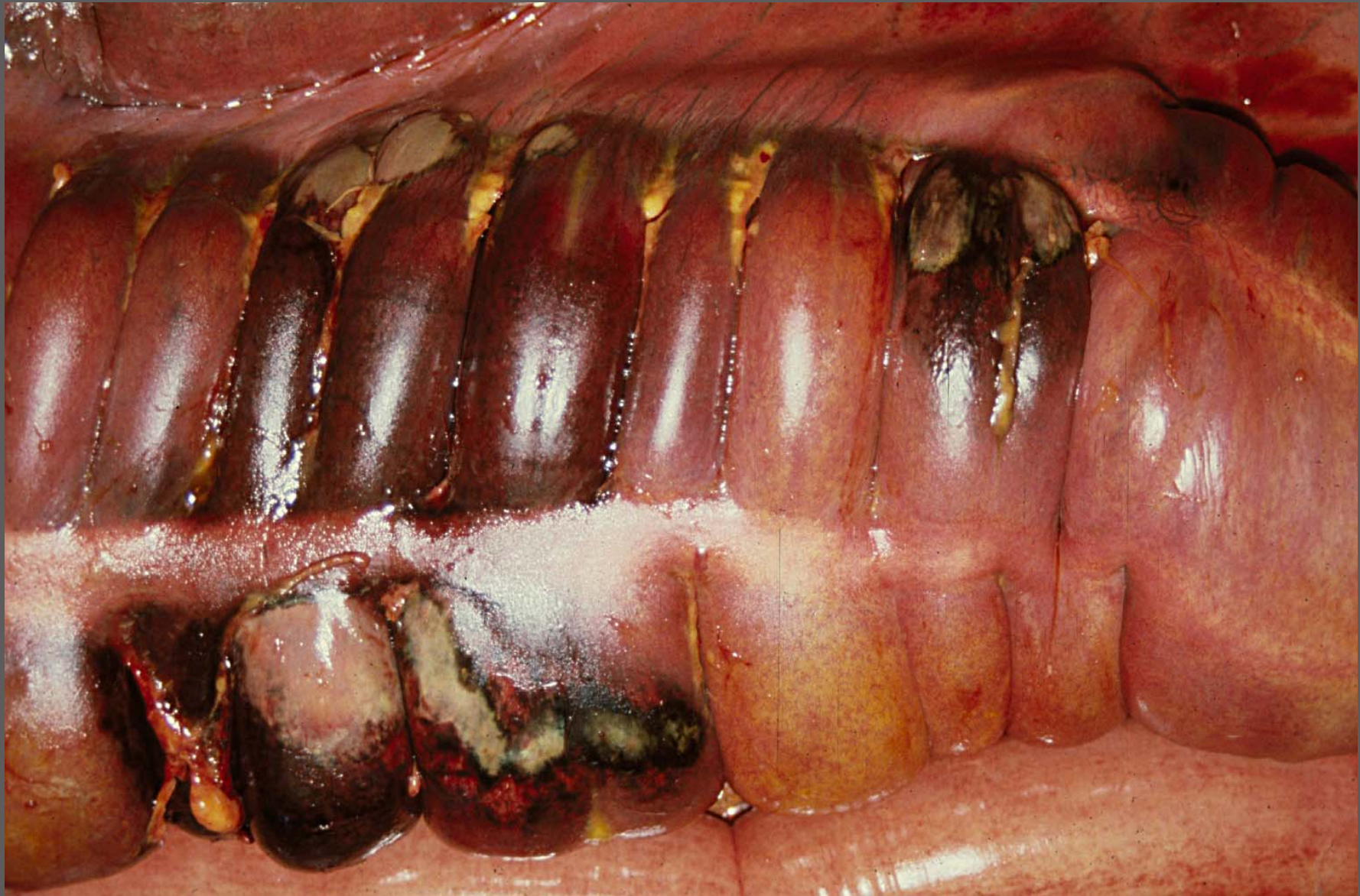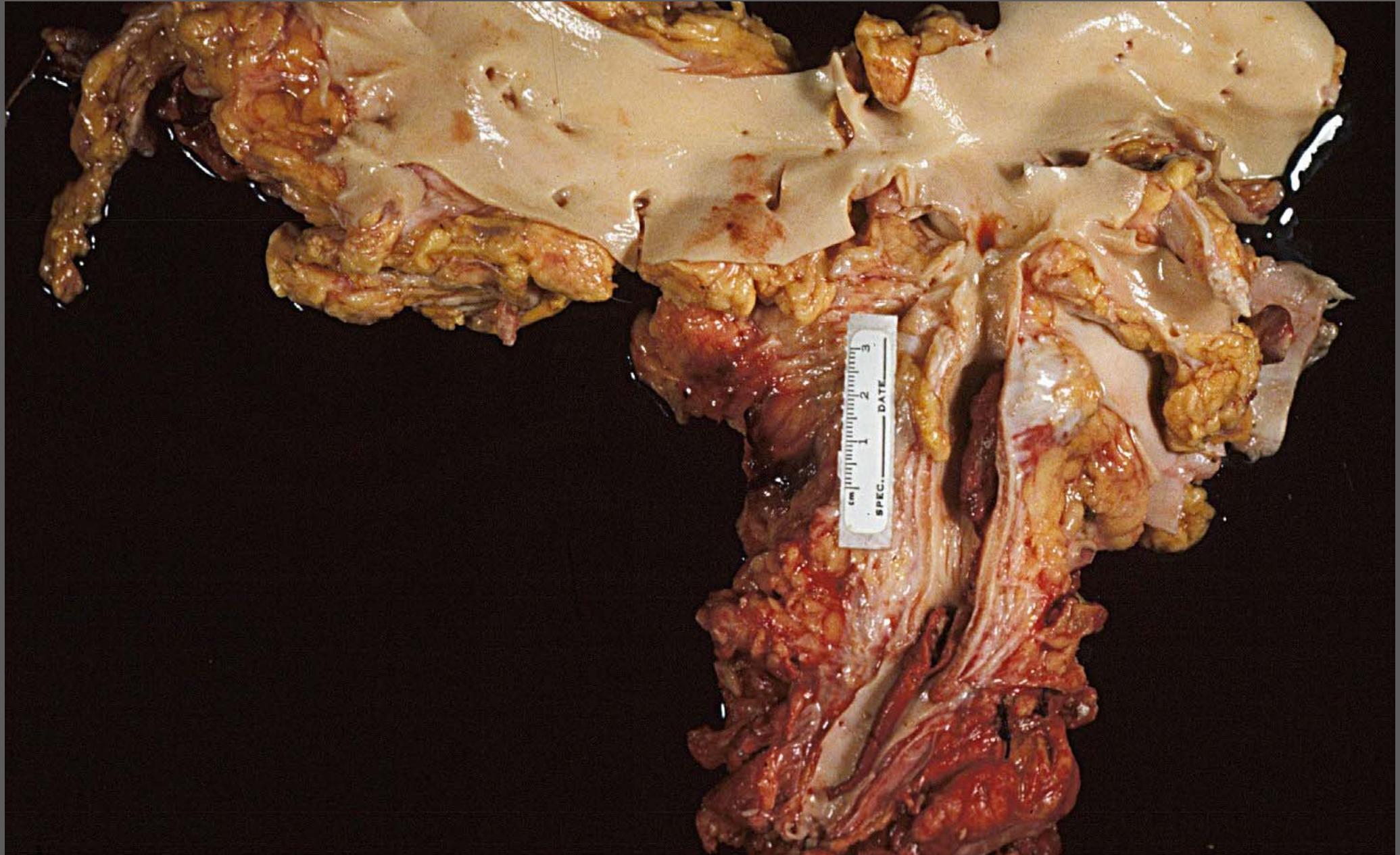
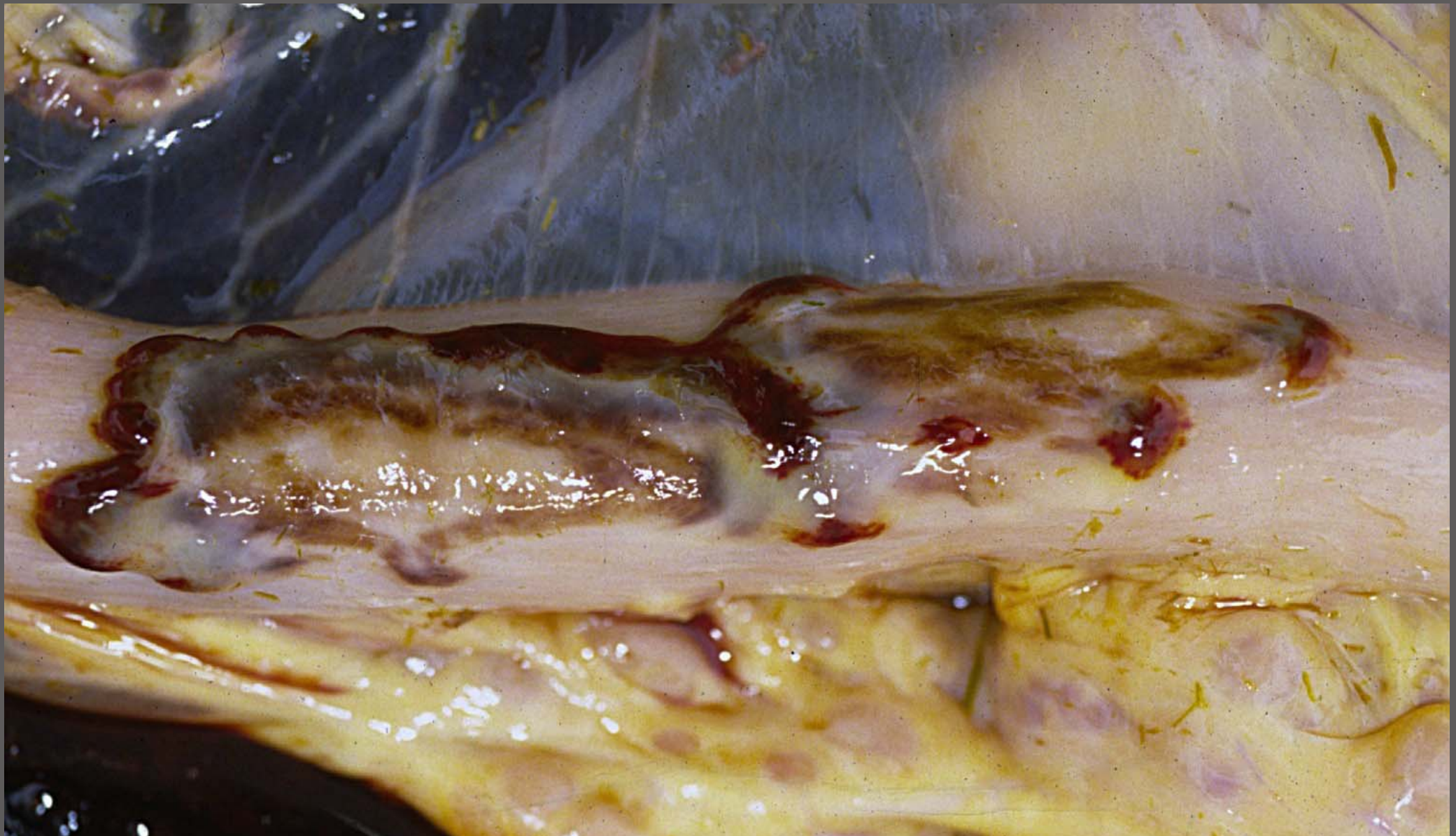




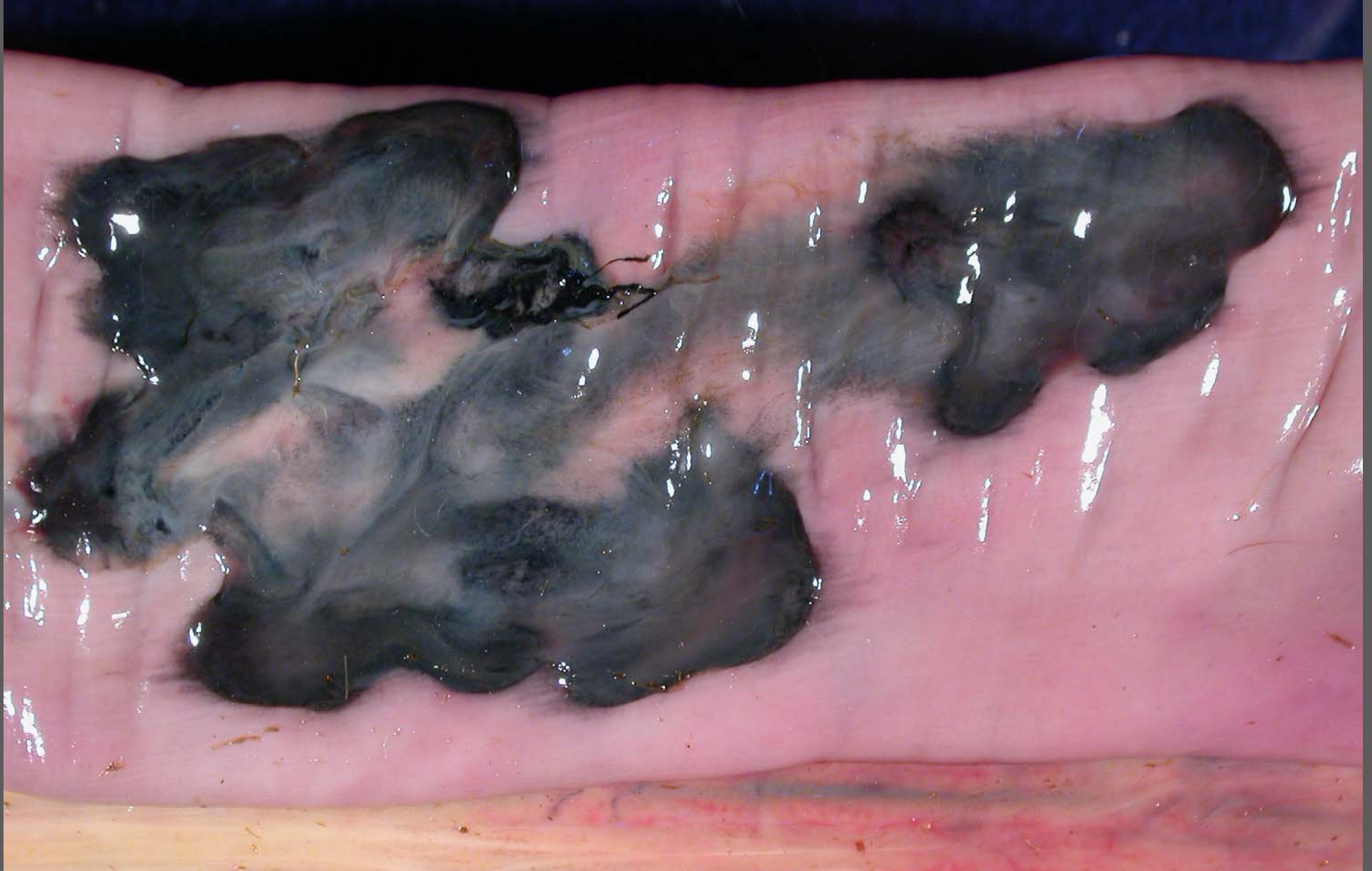Colon – infarcts – *Salmonella* spp. necrotizing colitis with thrombosis (DD: strongyle larvae; pyrrolizidine alkaloids hepatopathy)

Cranial mesenteric artery endoarteritis and thrombosis – *Strongylus vulgaris* larvae L4, L5

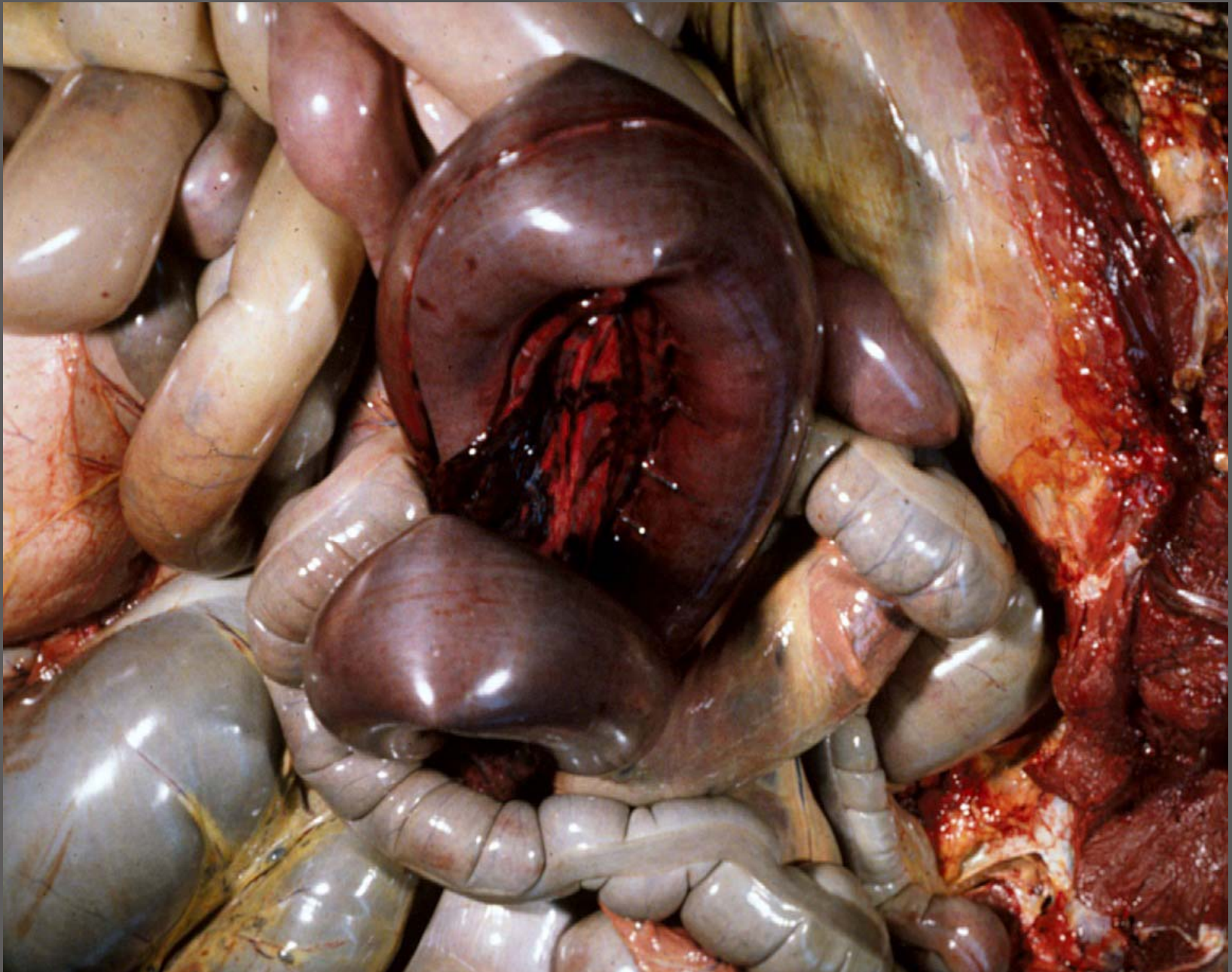




Ileum – Chronic subserosal fibrosing serpiginous hemorrhage (hemomelasma ilei) – cause unknown



Ileum – Chronic subserosal fibrosing serpiginous hemorrhage with pseudomelanosis (heamomelasma ilei) – cause unknown



Jejunum – volvulus with hemorrhagic (ischemic) necrosis