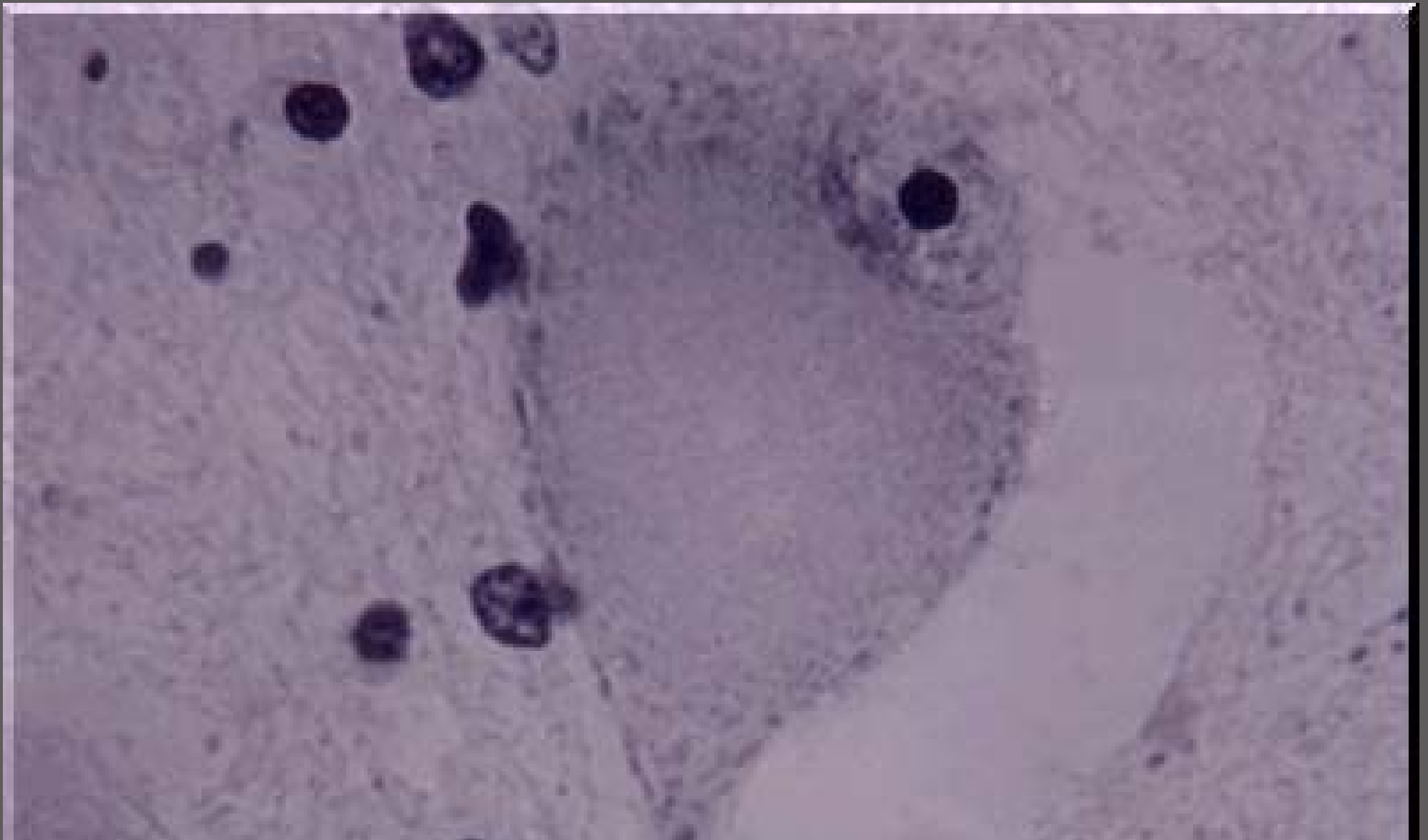
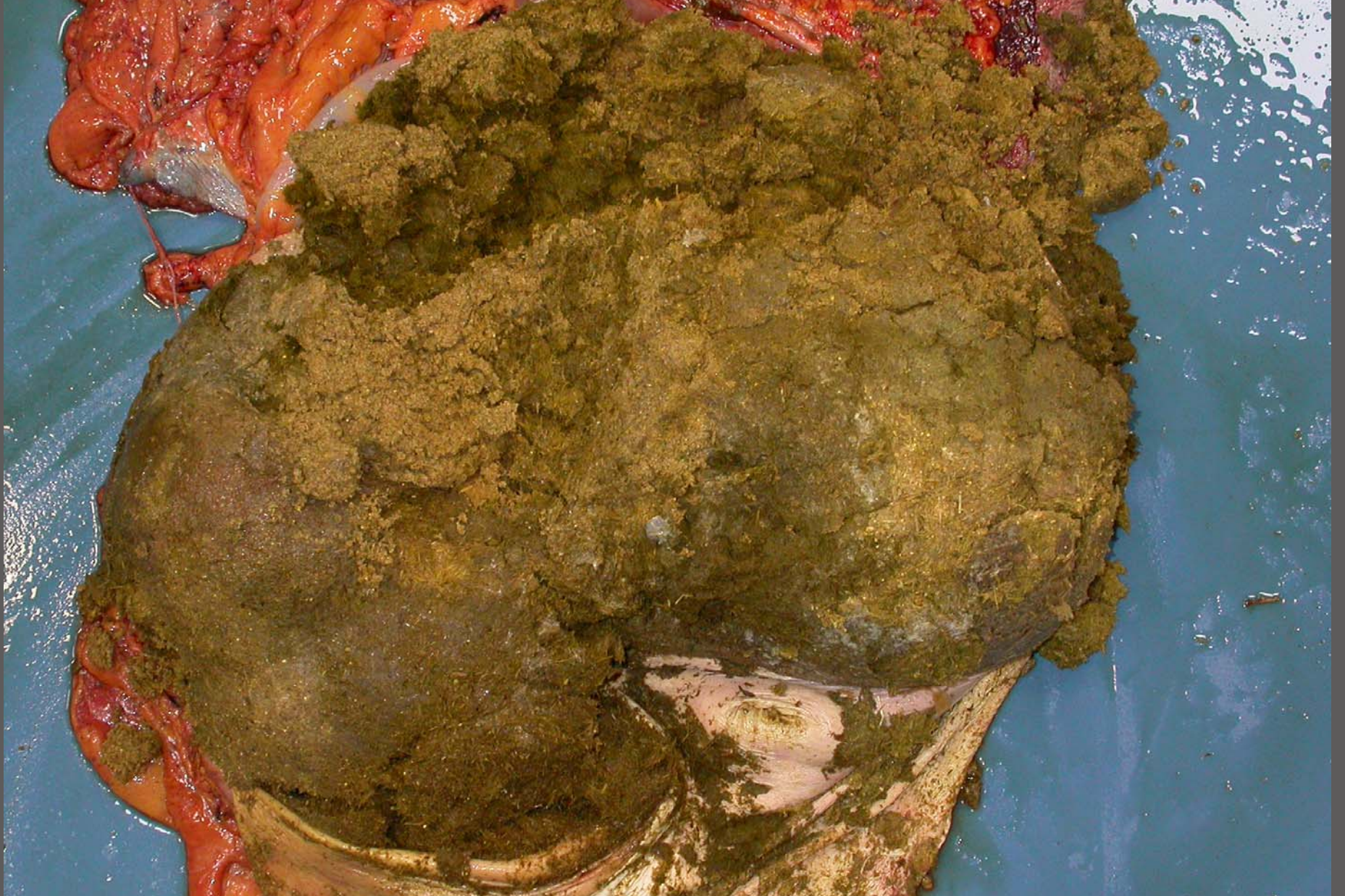
Neuronal chromatolysis – acute grass sickness-like lesions (from internet, unknown location)



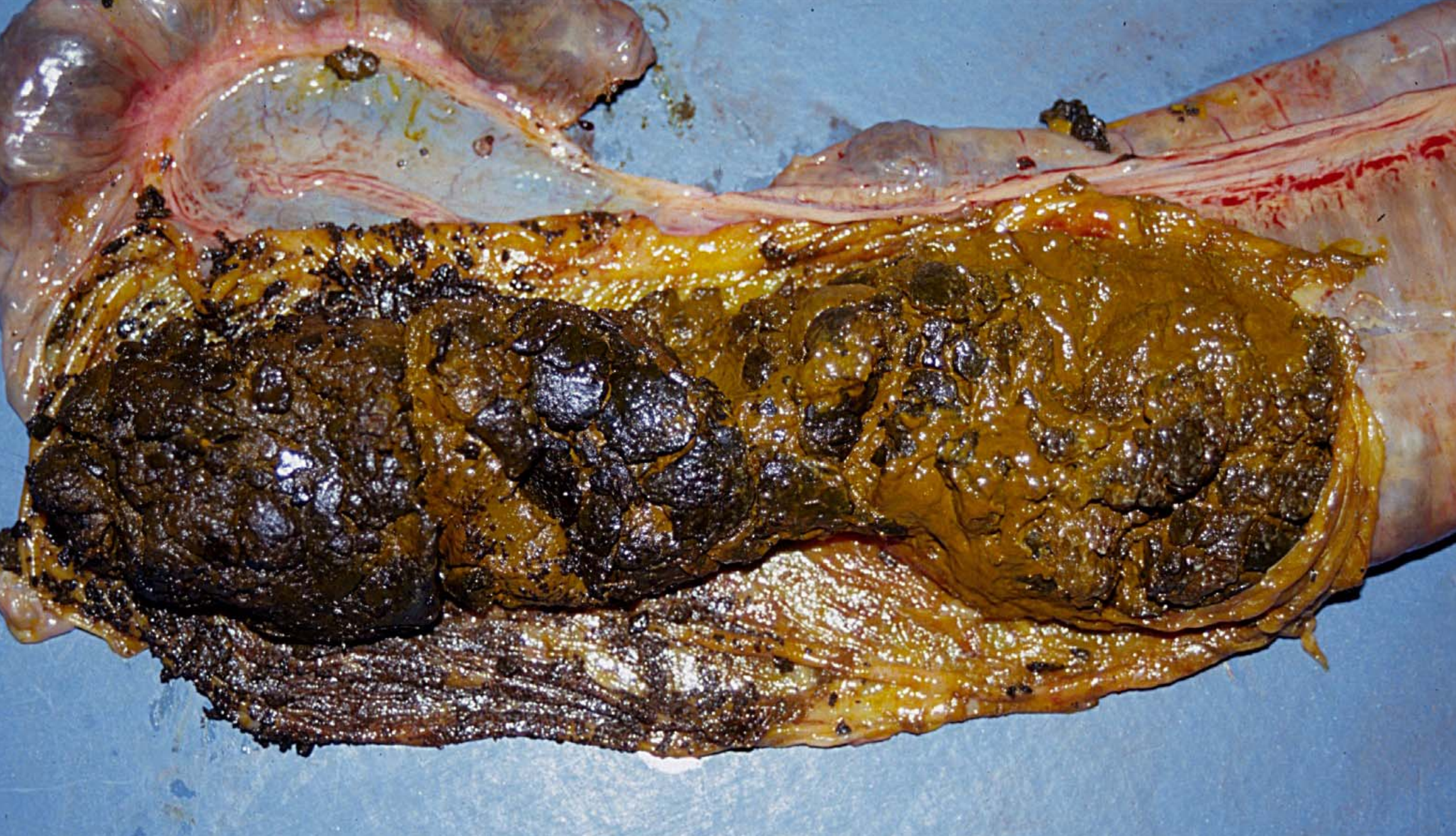Stomach – idiopathic impaction with smooth muscle hypertrophy and hyperplasia





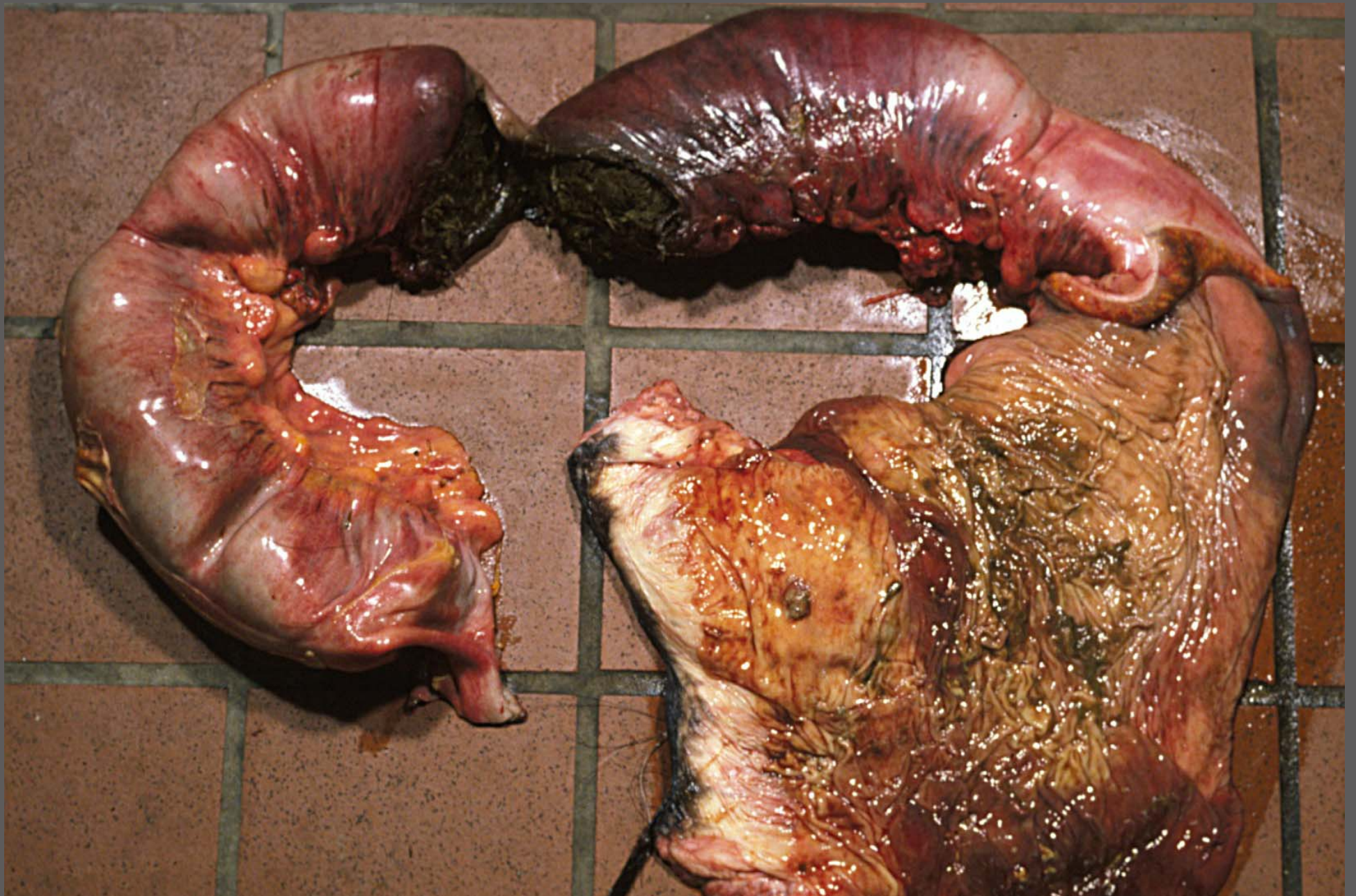
Overo foal – colonic aganglionosis (Hirschsprung disease) – prominent diffuse hypopigmentation





Overo foal – colonic aganglionosis (Hirschprung disease) – severe meconium impaction





Distal colon – trauma → infarction → necrosis → rupture