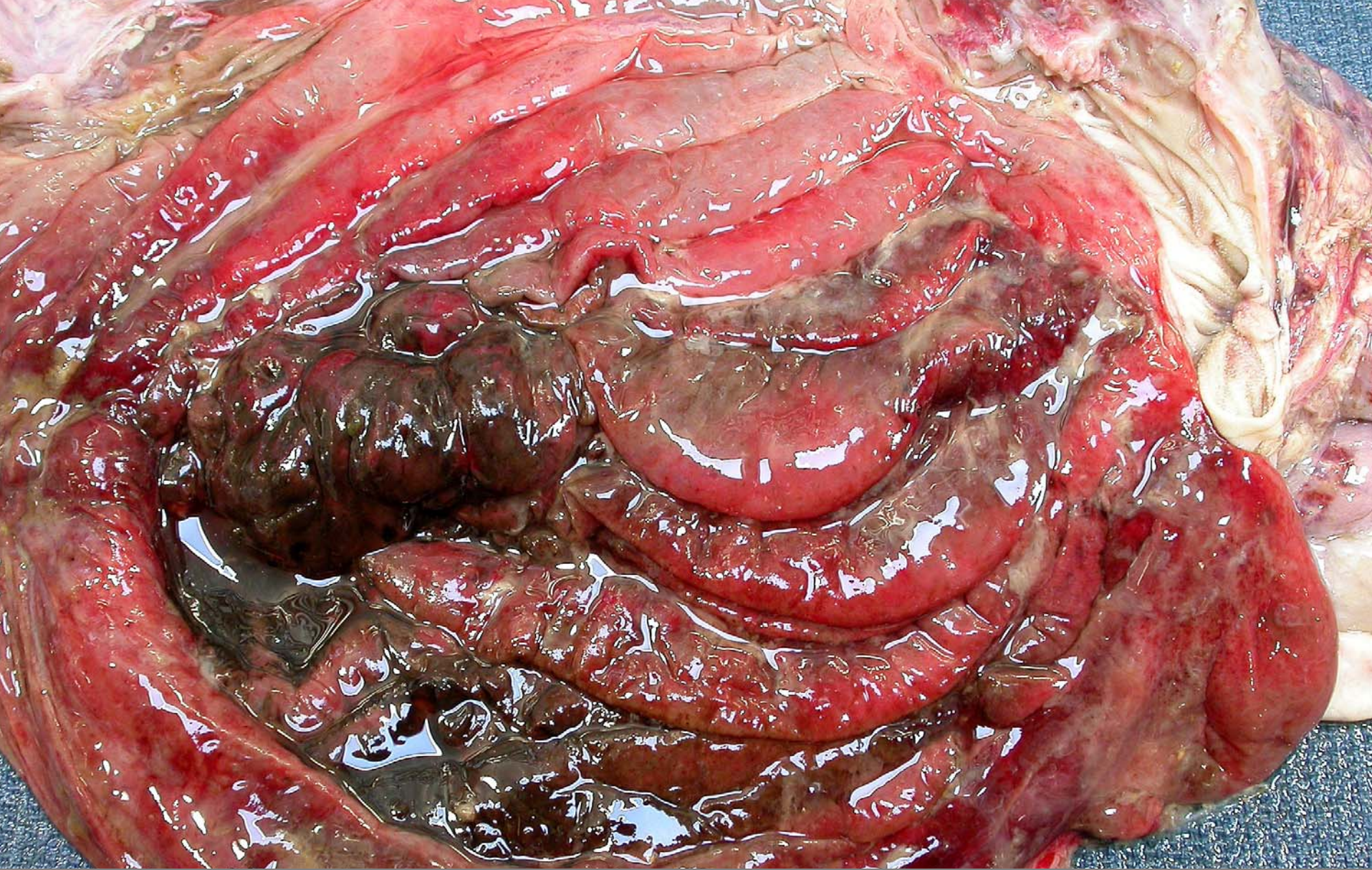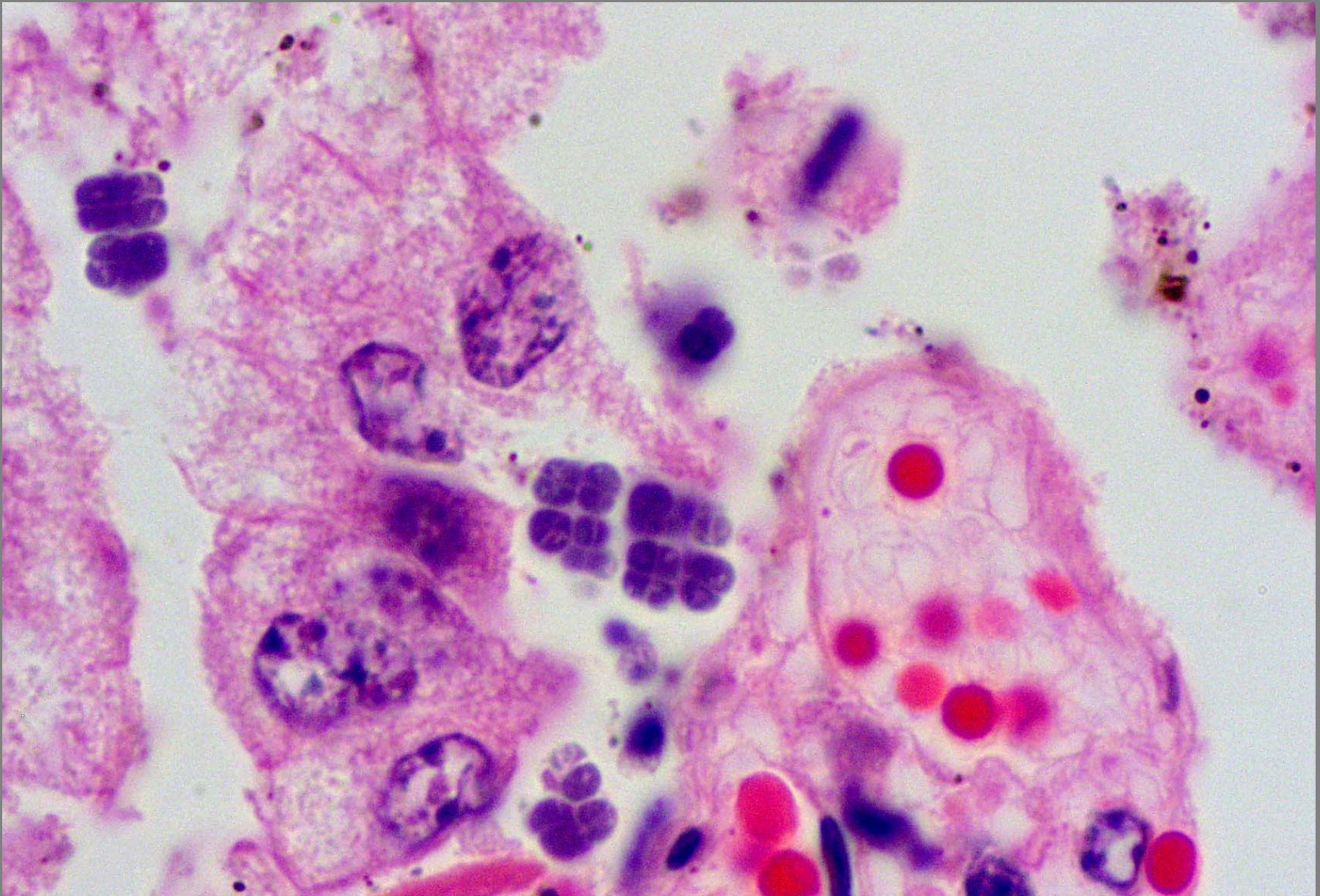




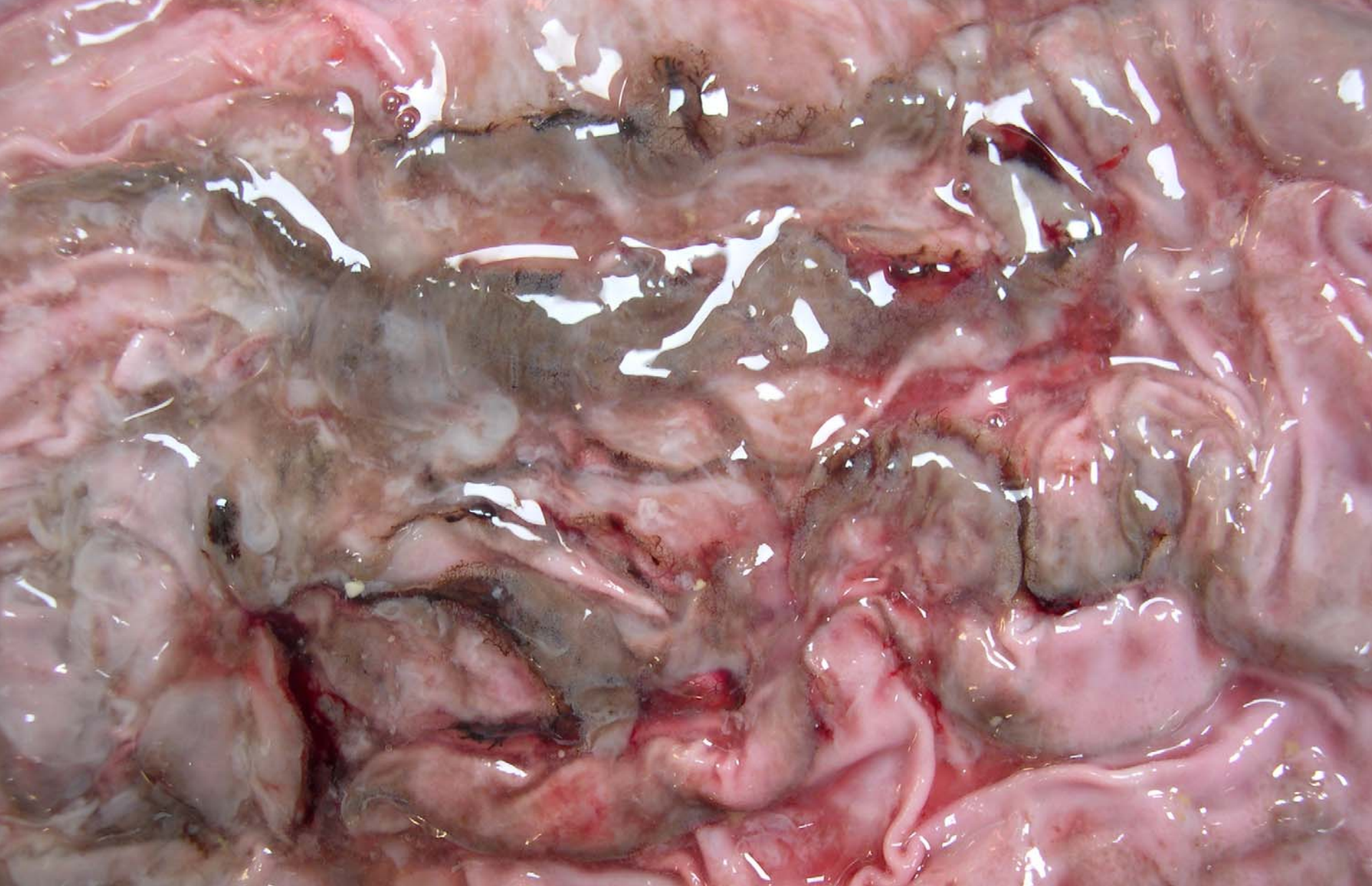Rumen – hypertrophic papillae - less fiber in diet



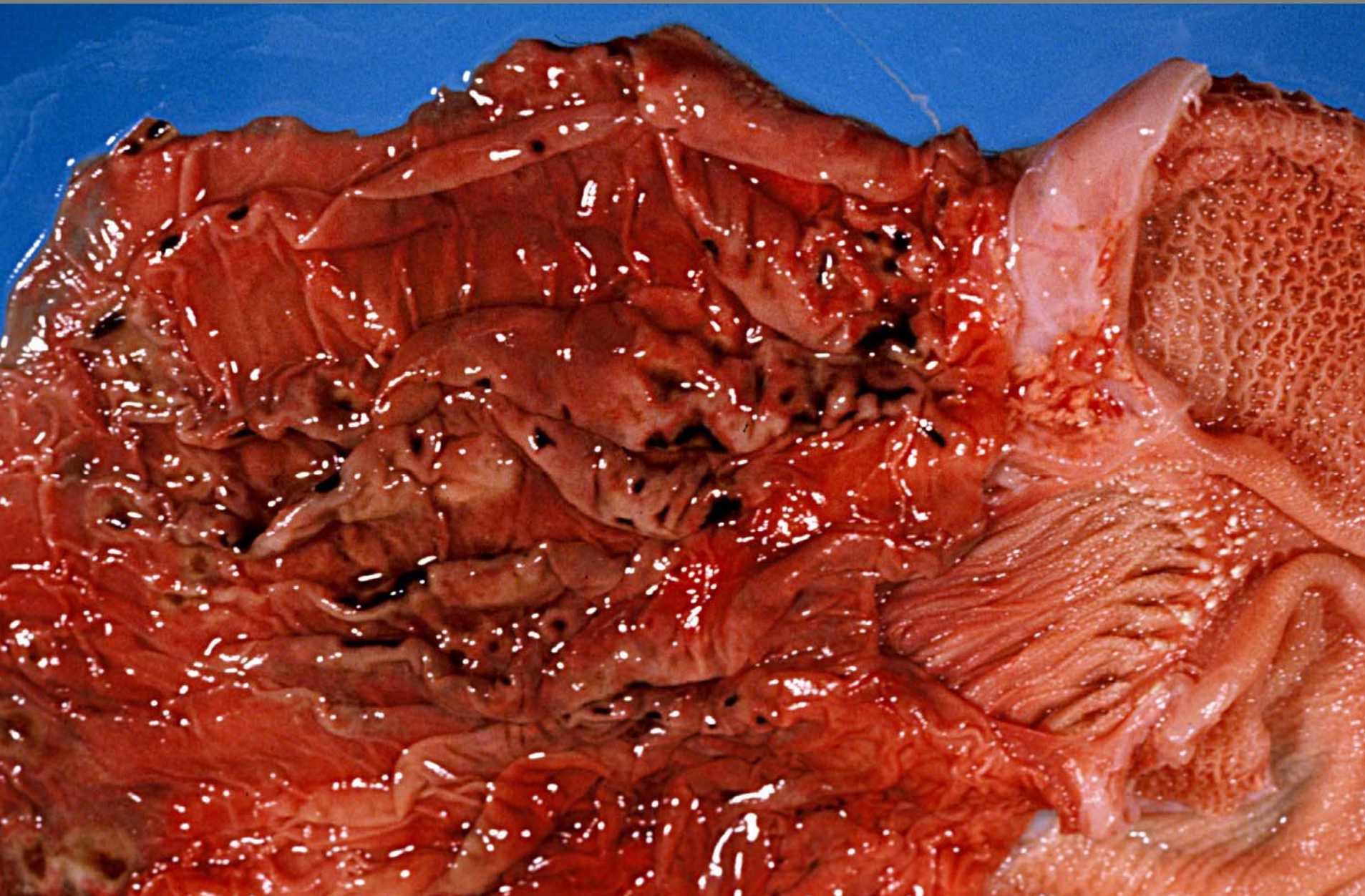
Calf - abomasum – hemorrhagic necrosis with perforation – Braxy-like – *Clostridium* spp. (presumptive) and *Sarcina* spp.



Calf - Abomasum - Hemorrhagic necrosis, extreme edema with perforation – Braxy-like – *Clostridium* spp. (presumptive) and ***Sarcina* spp.**



Calf - Abomasum – Linear ulcers and edema – sepsis, inanition, stress, other



Abomasum – Ulcers.