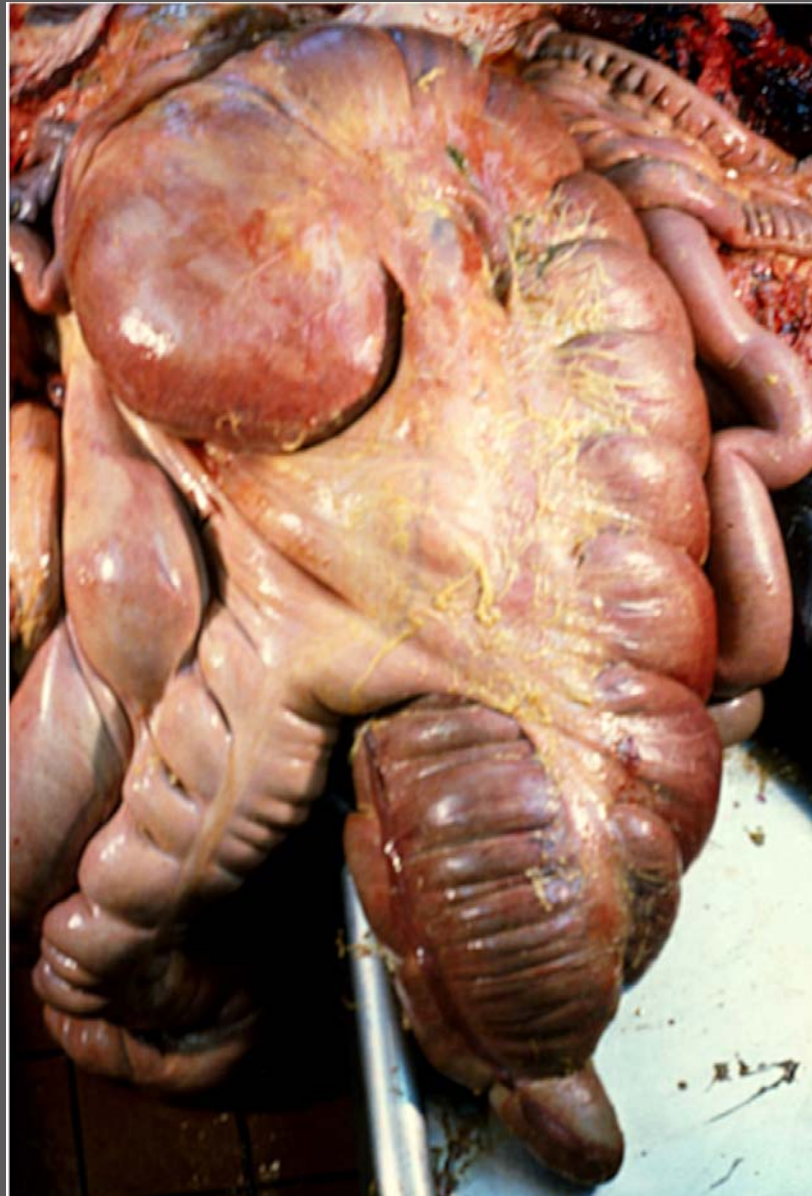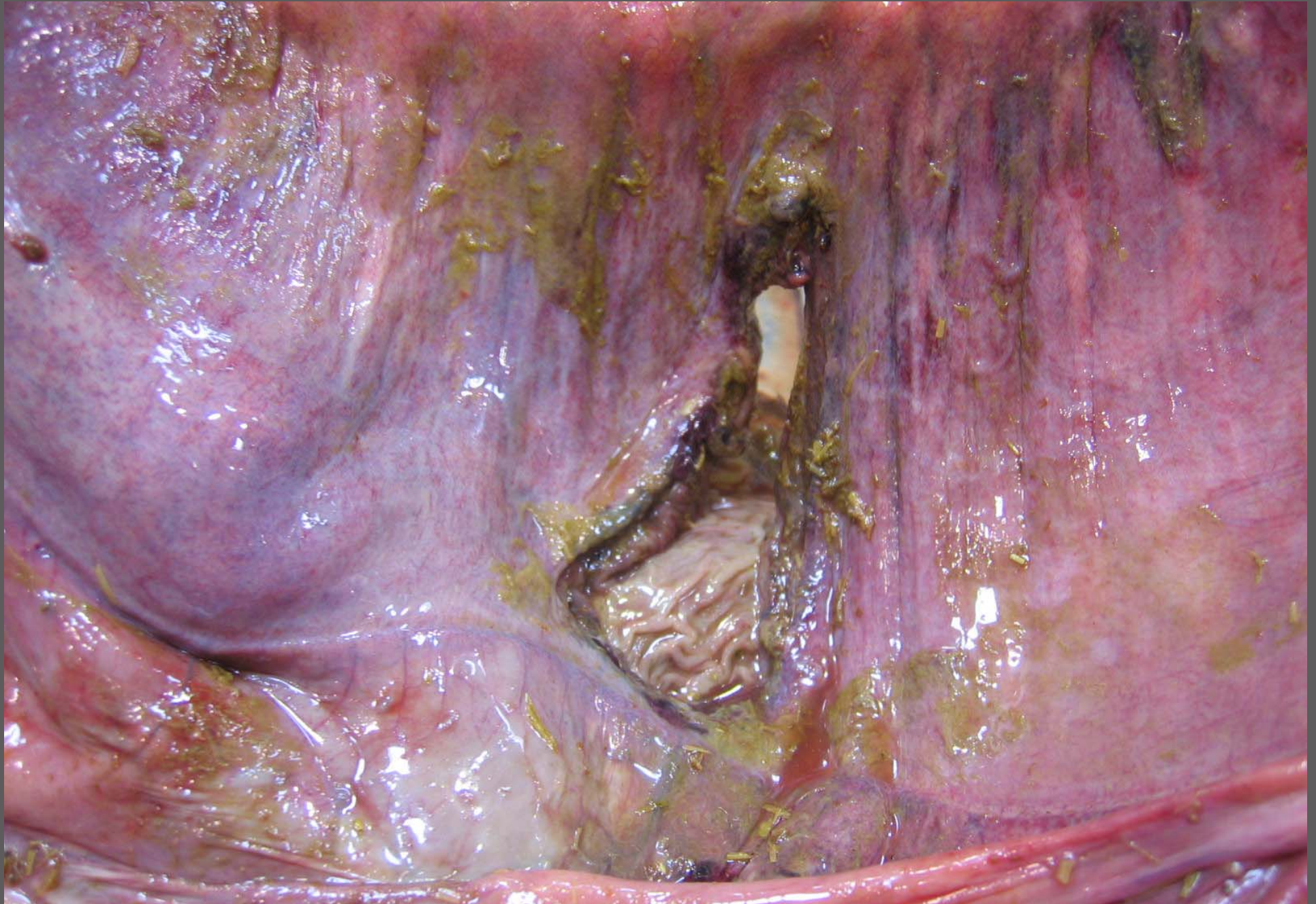

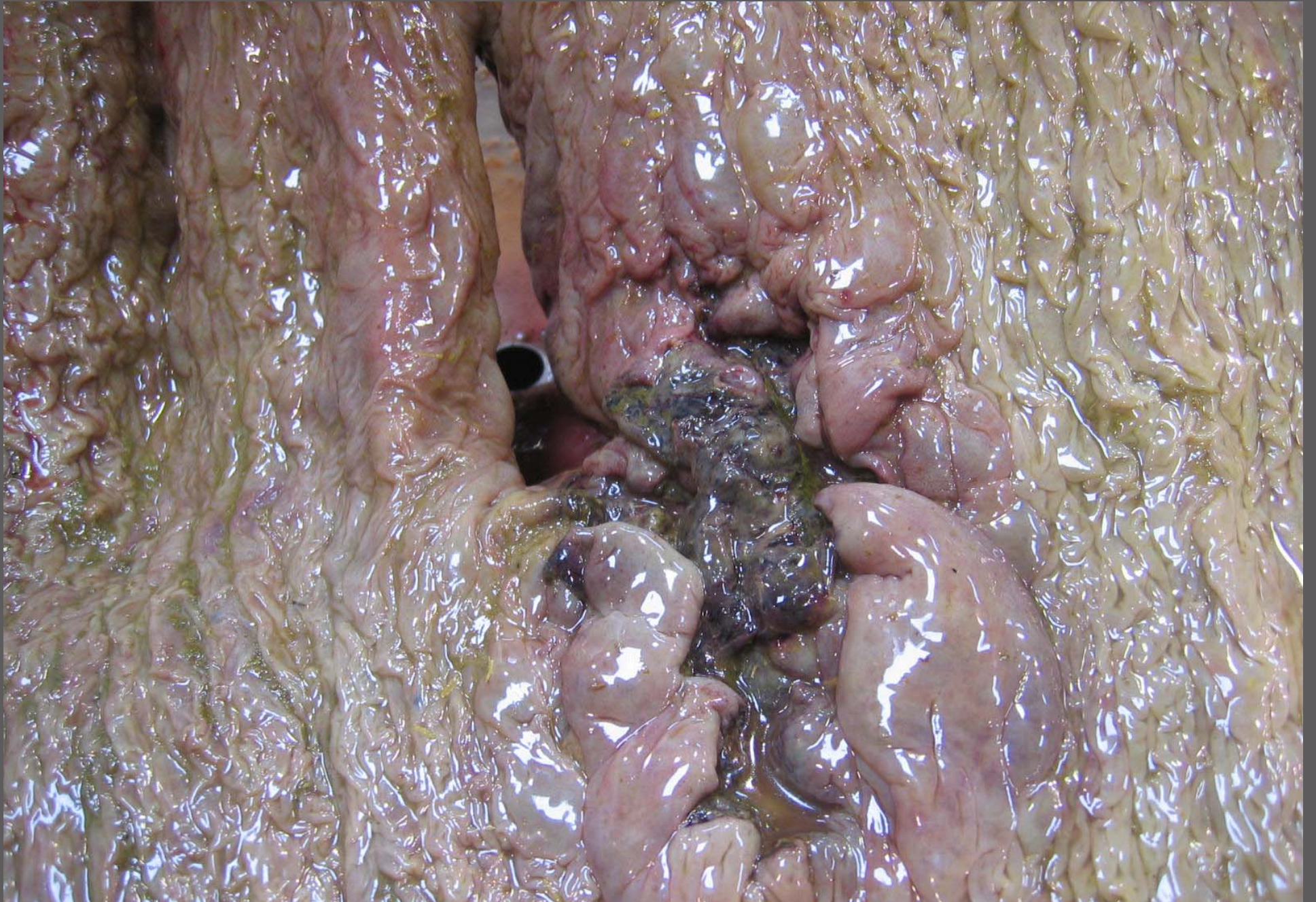


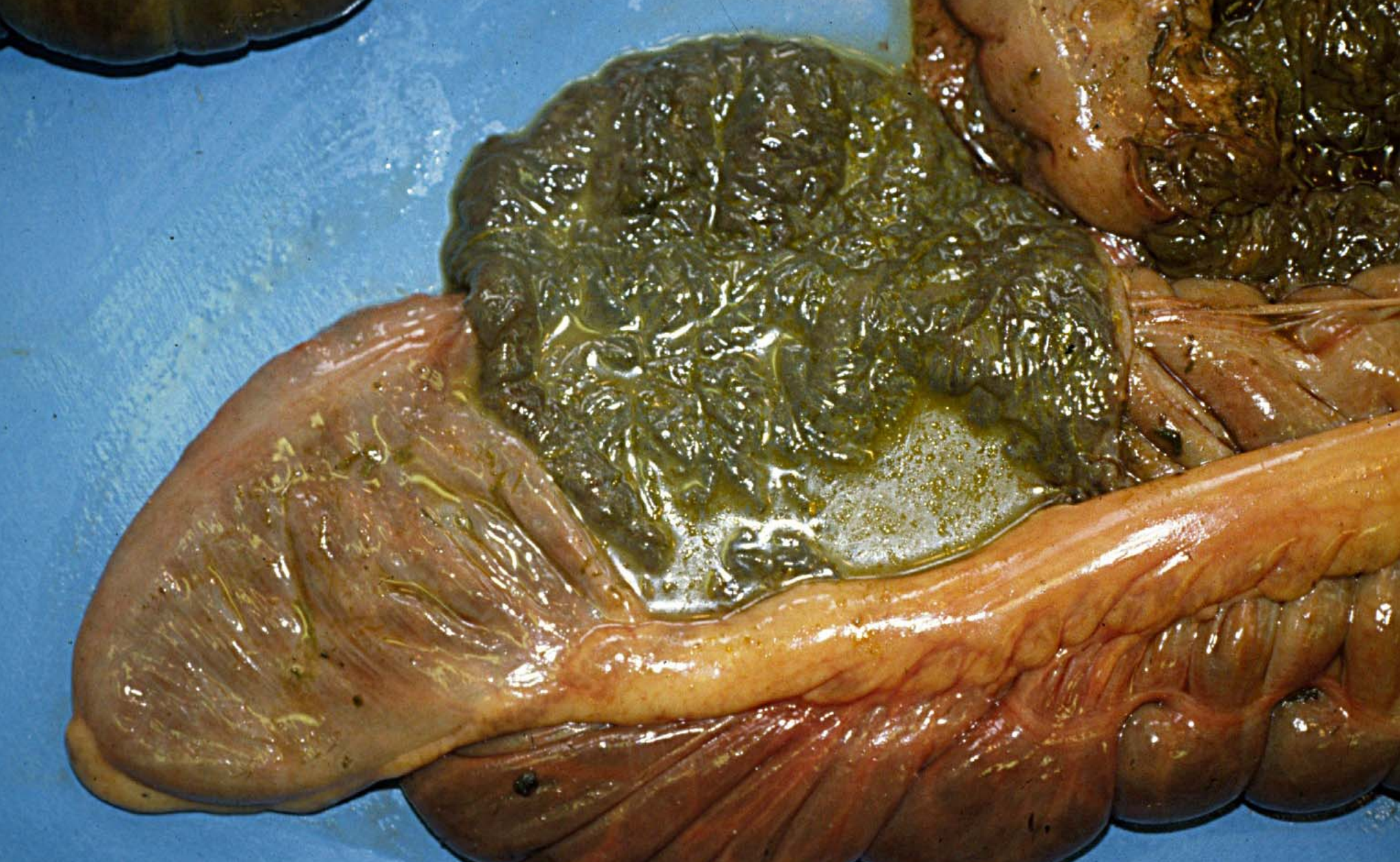
Cecum – idiopathic chronic dilatation, atony, muscular hypertrophy/hyperplasia and fibrinous cecal peritonitis



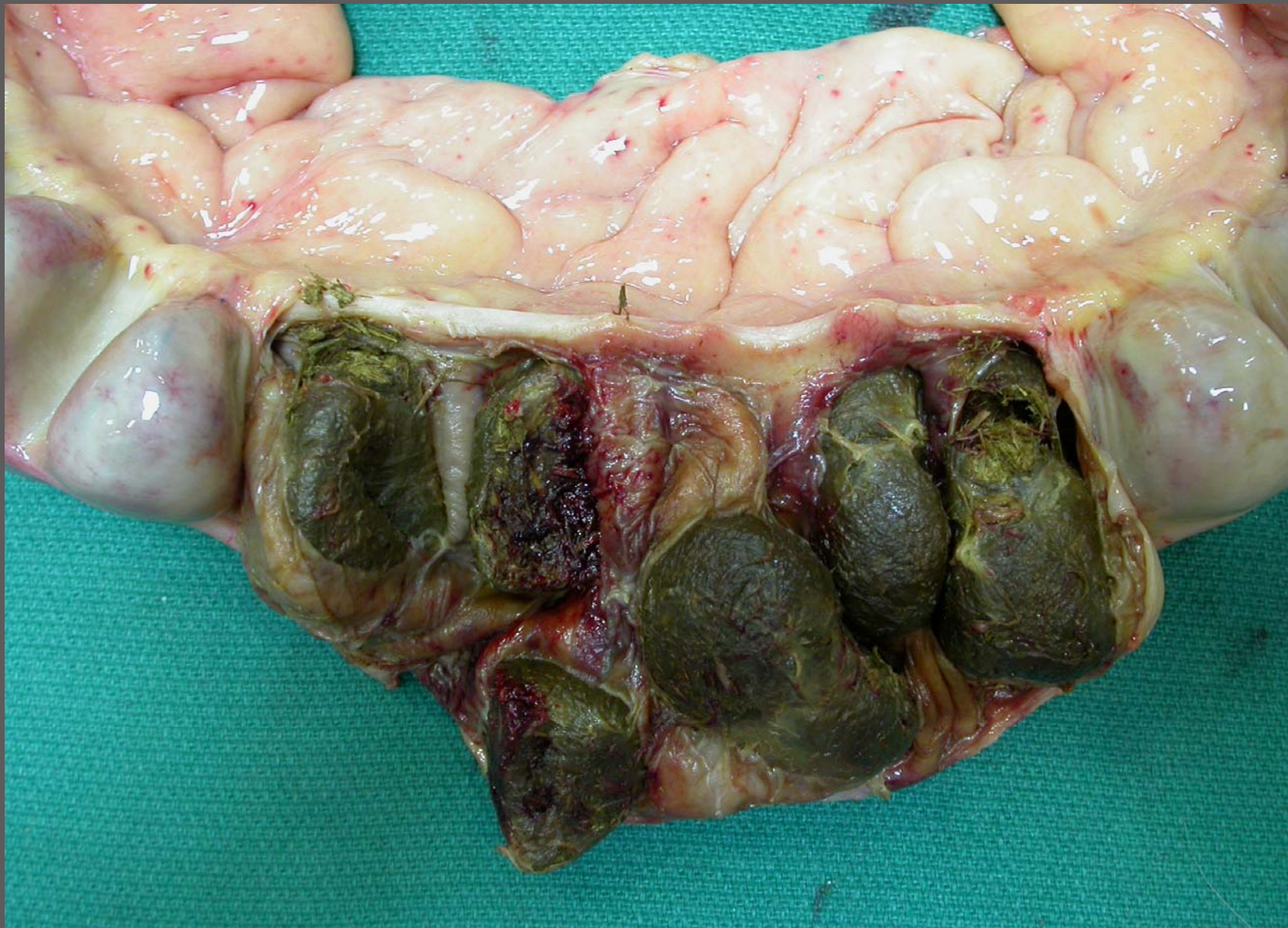
Colon rupture with secondary septic peritonitis (serosal side)



Colon rupture with secondary septic peritonitis (mucosal side)



Dysautonomia (grass sickness) – foamy abnormal digesta



Dysautonomia (grass sickness) like lesion – impaction with dry digesta