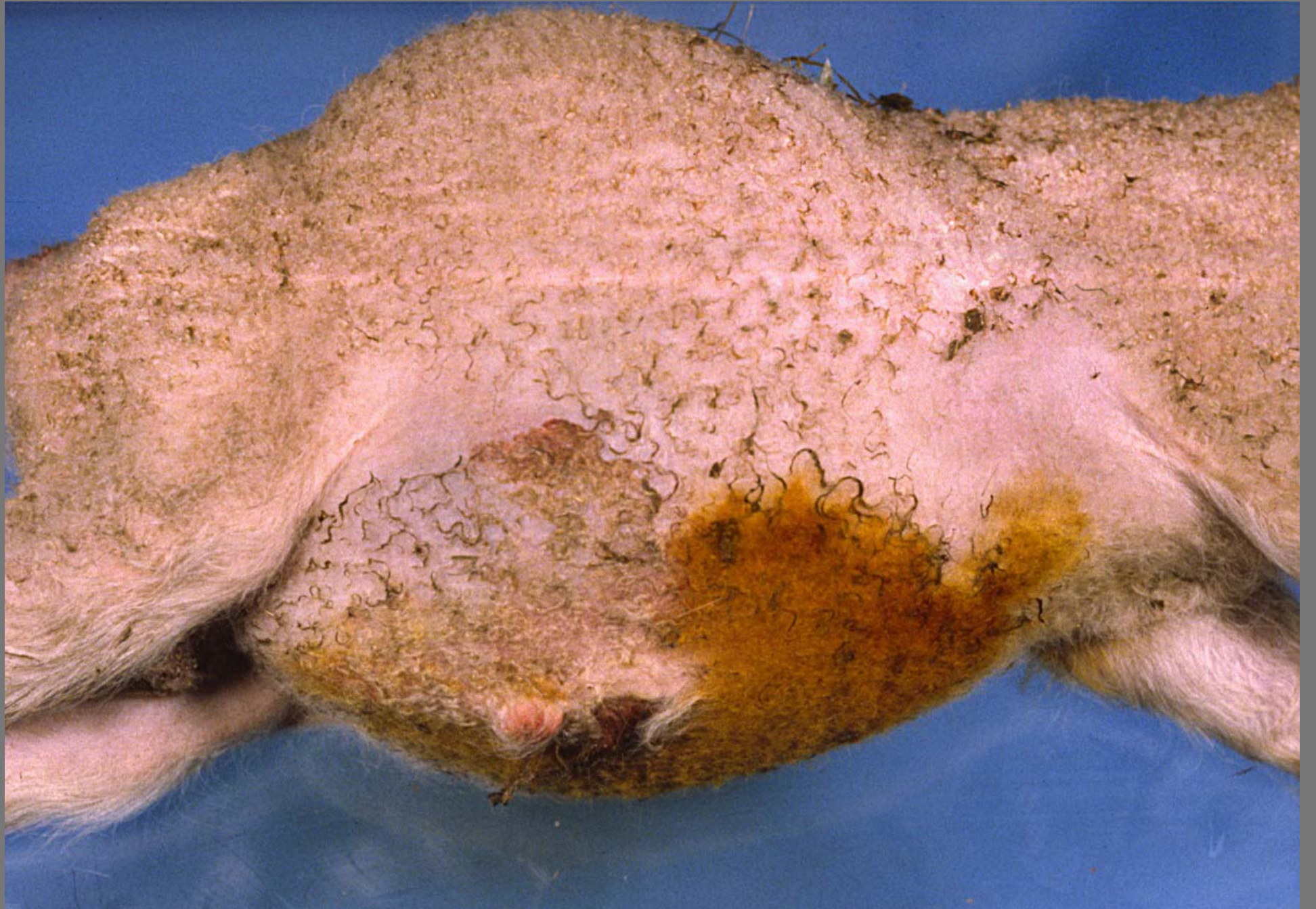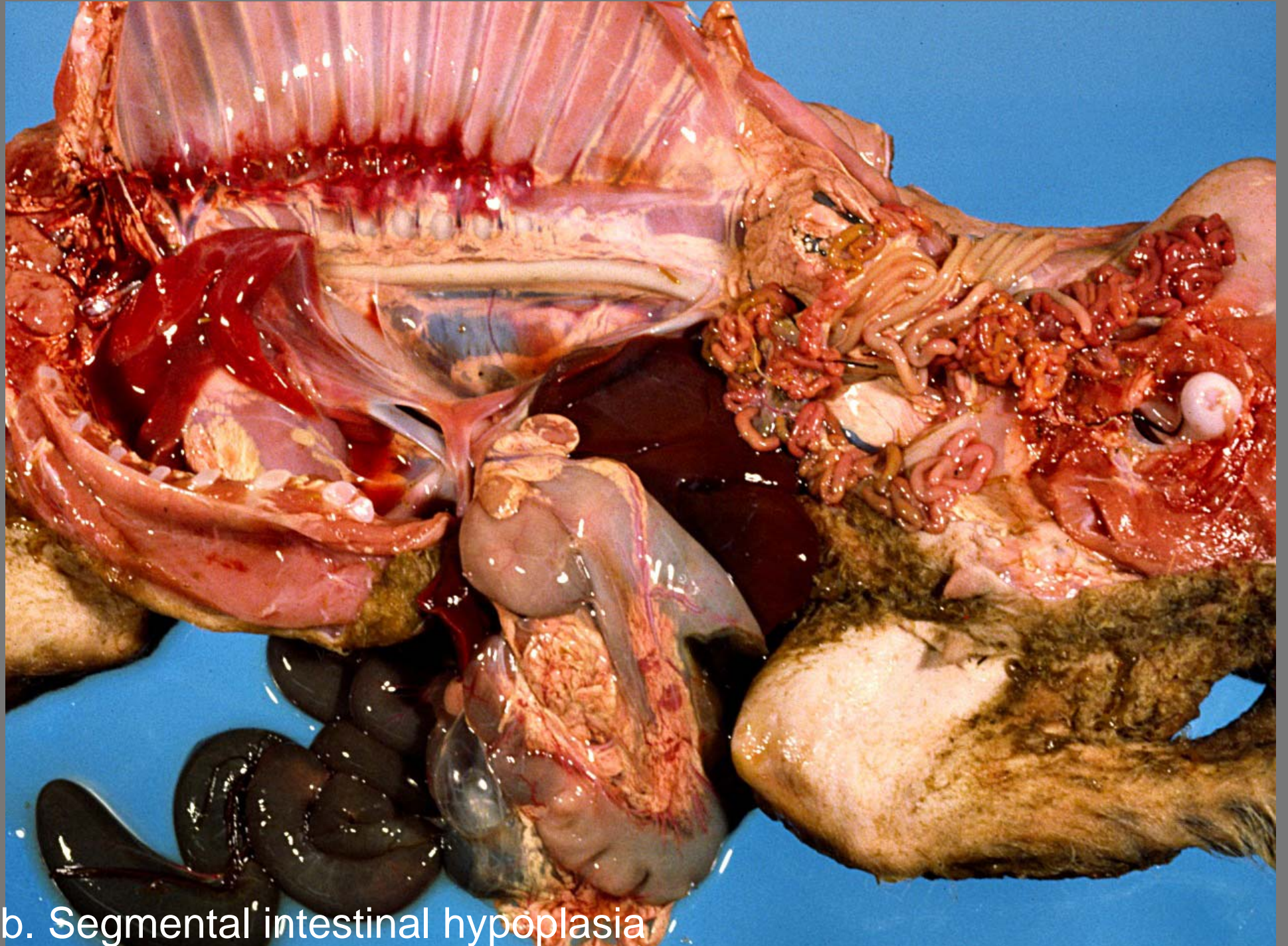


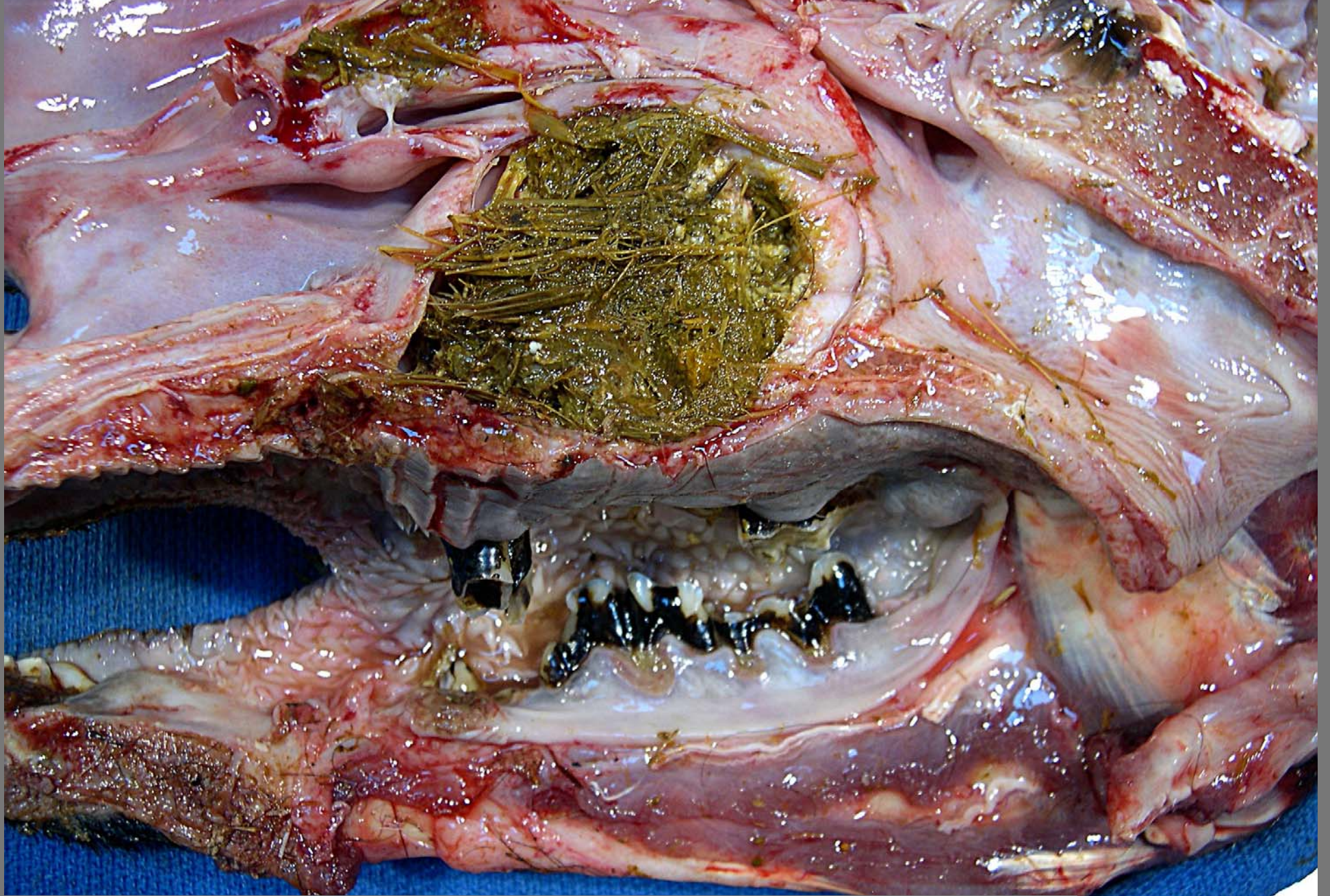Lamb: anal atresia induced intestinal digesta accumulation





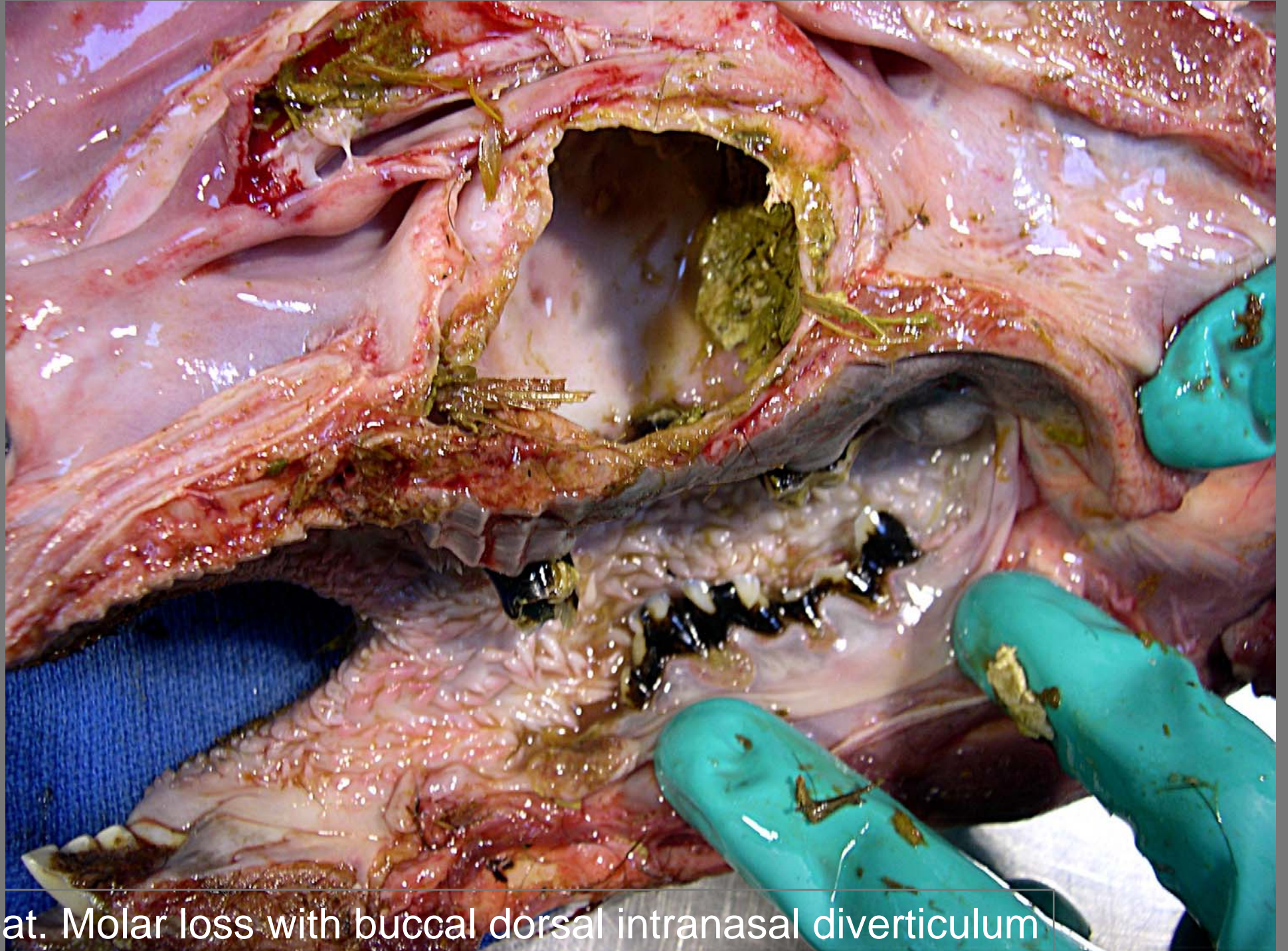
Lamb. Segmental intestinal hypoplasia





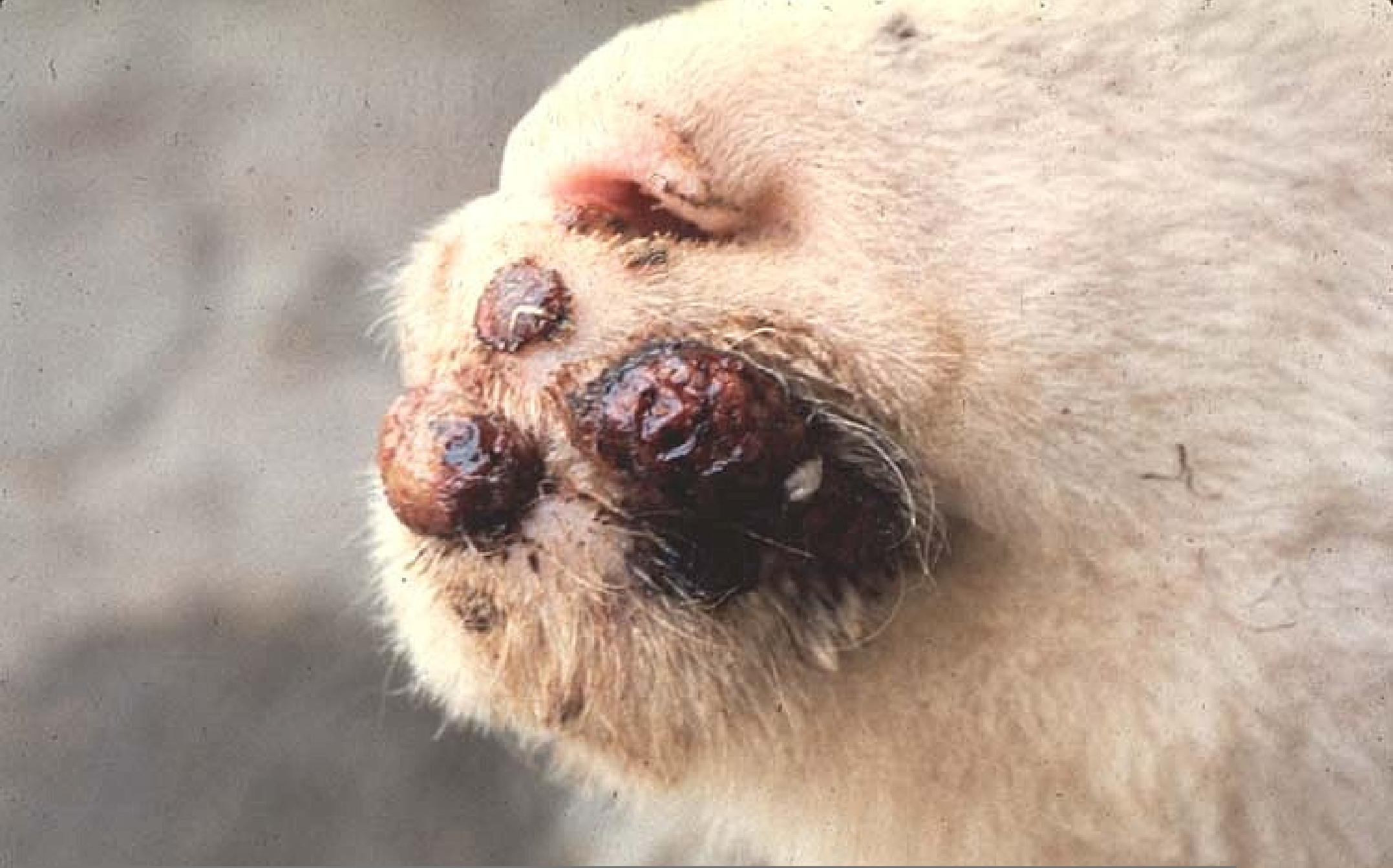Goat. Molar loss with buccal dorsal intranasal diverticulum





Goat. Molar loss with buccal dorsal intranasal diverticulum





Goat. Papular cheilitis. Contagious echthyma (orf) - parapoxvirus