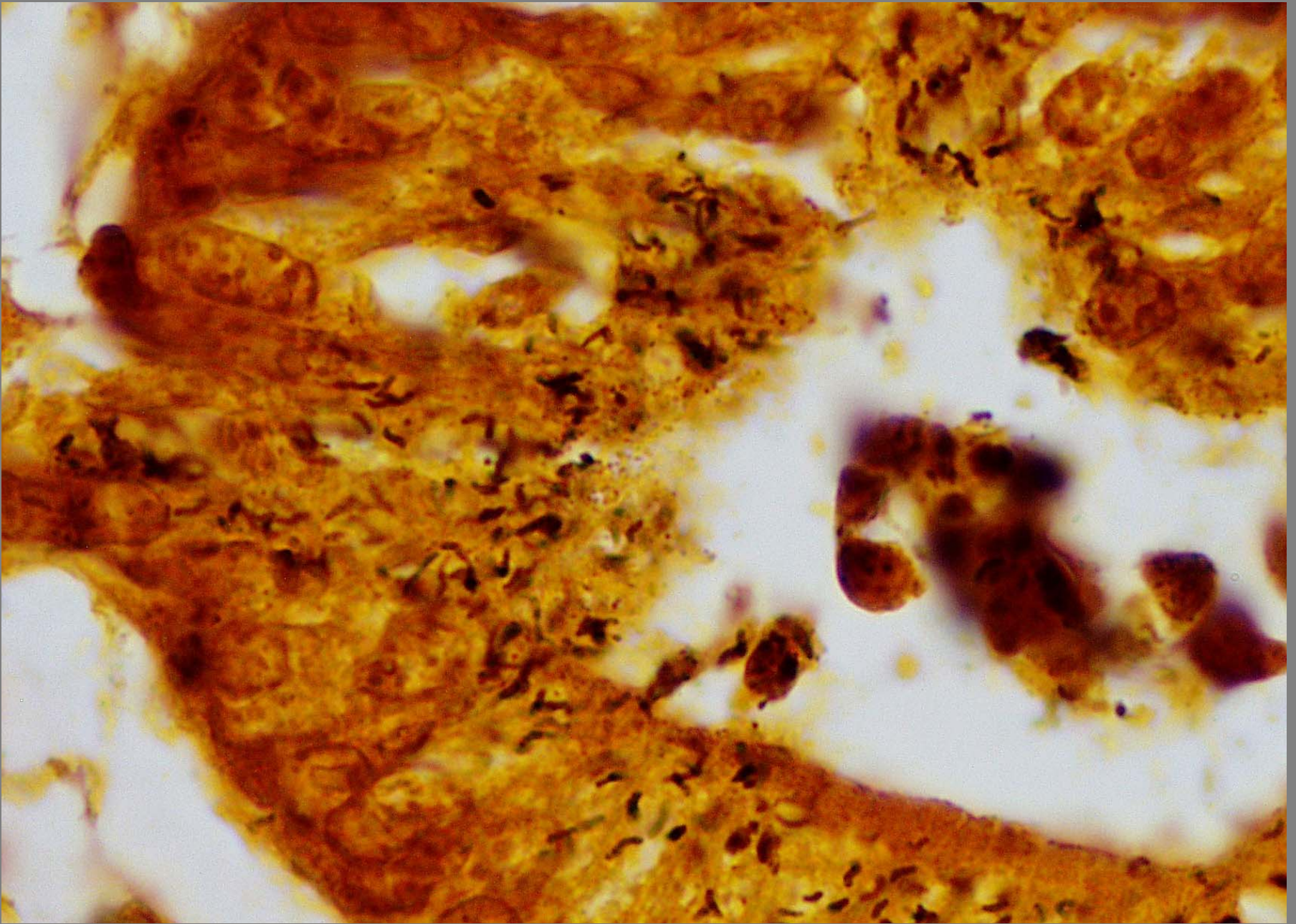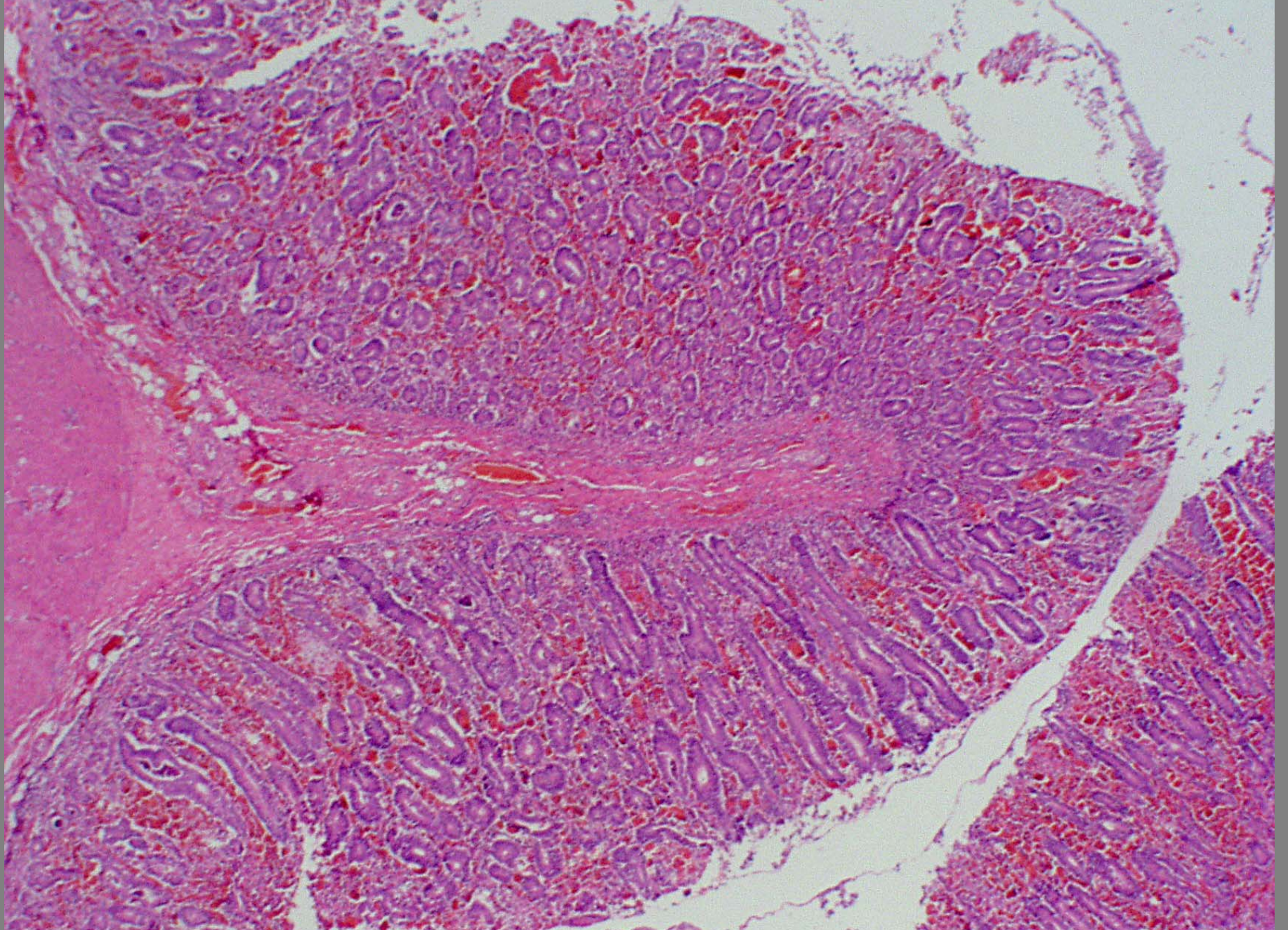


Intestine – proliferative distal ileitis – *Lawsonia intracellulare* – Whartin Starry stain



Intestine – proliferative hemorrhagic distal ileitis – *Lawsonia intracellulare*