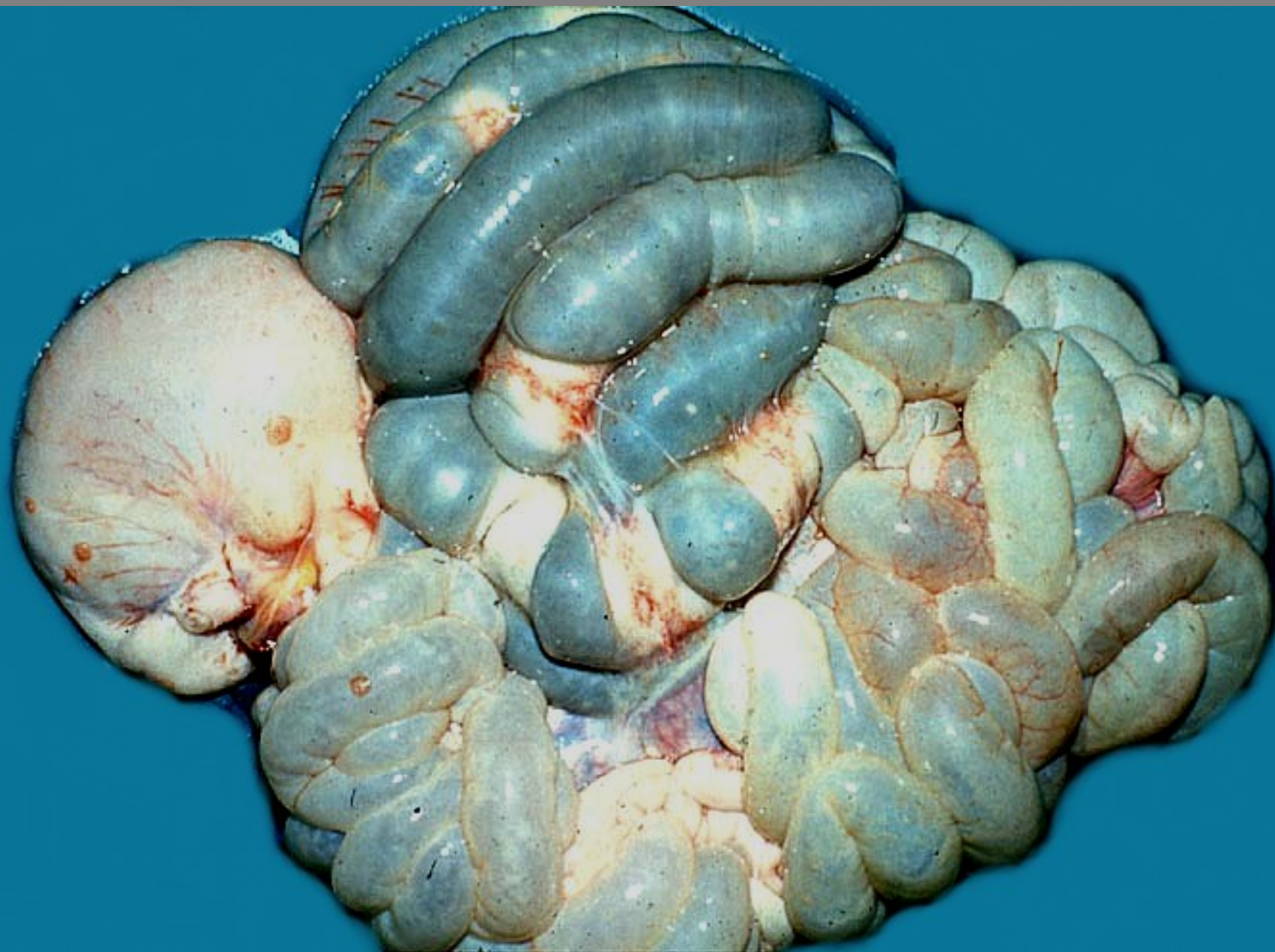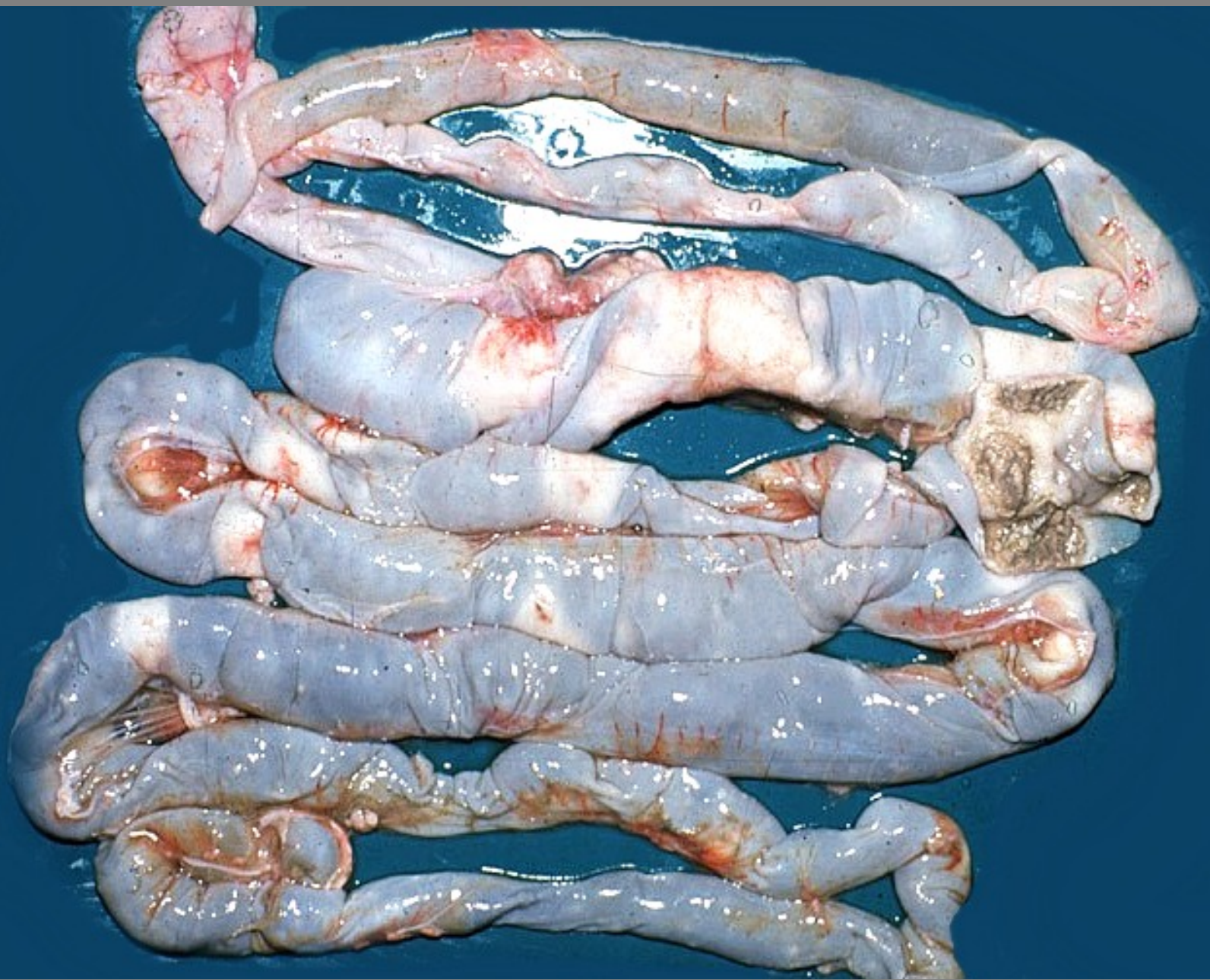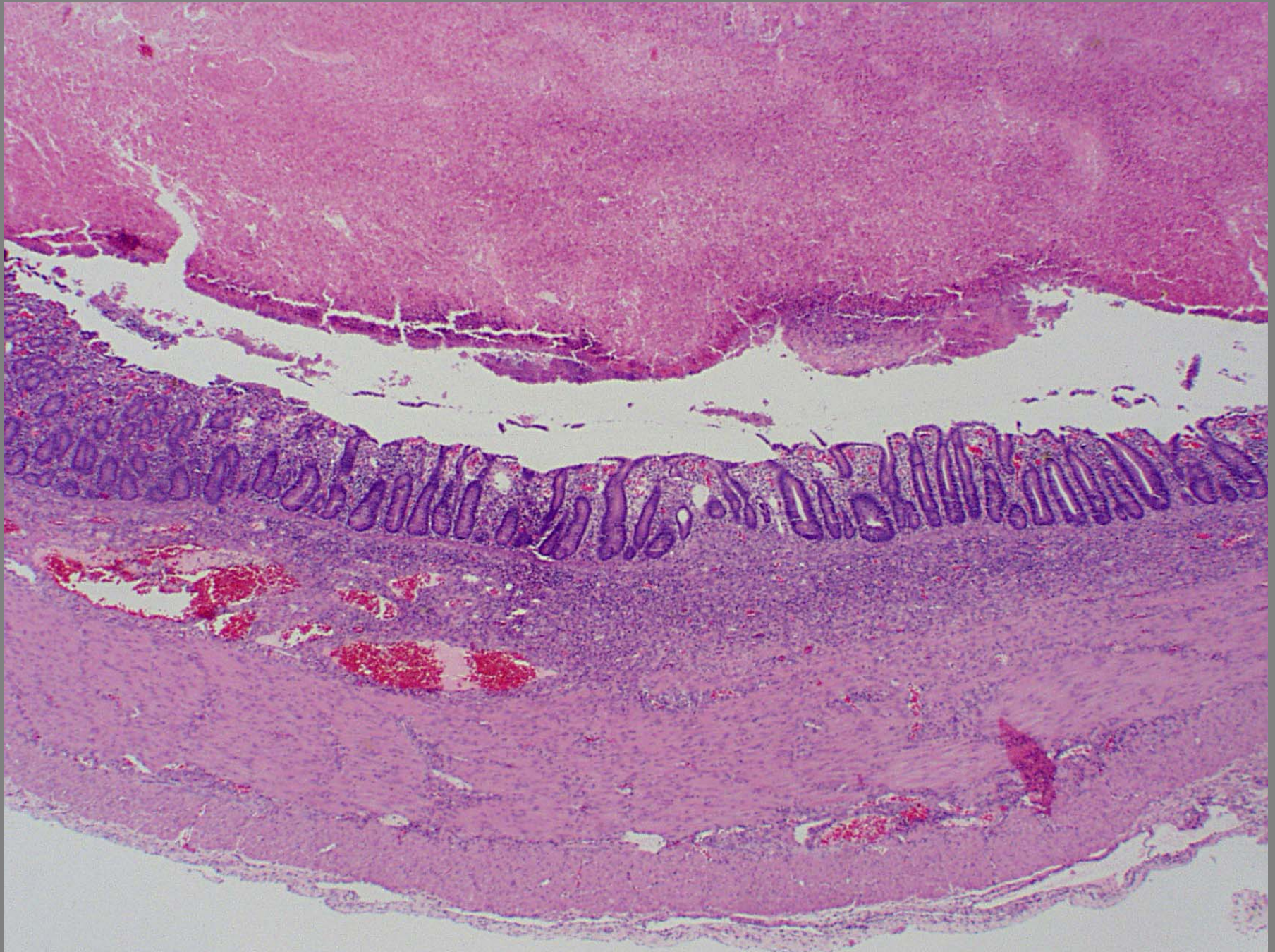


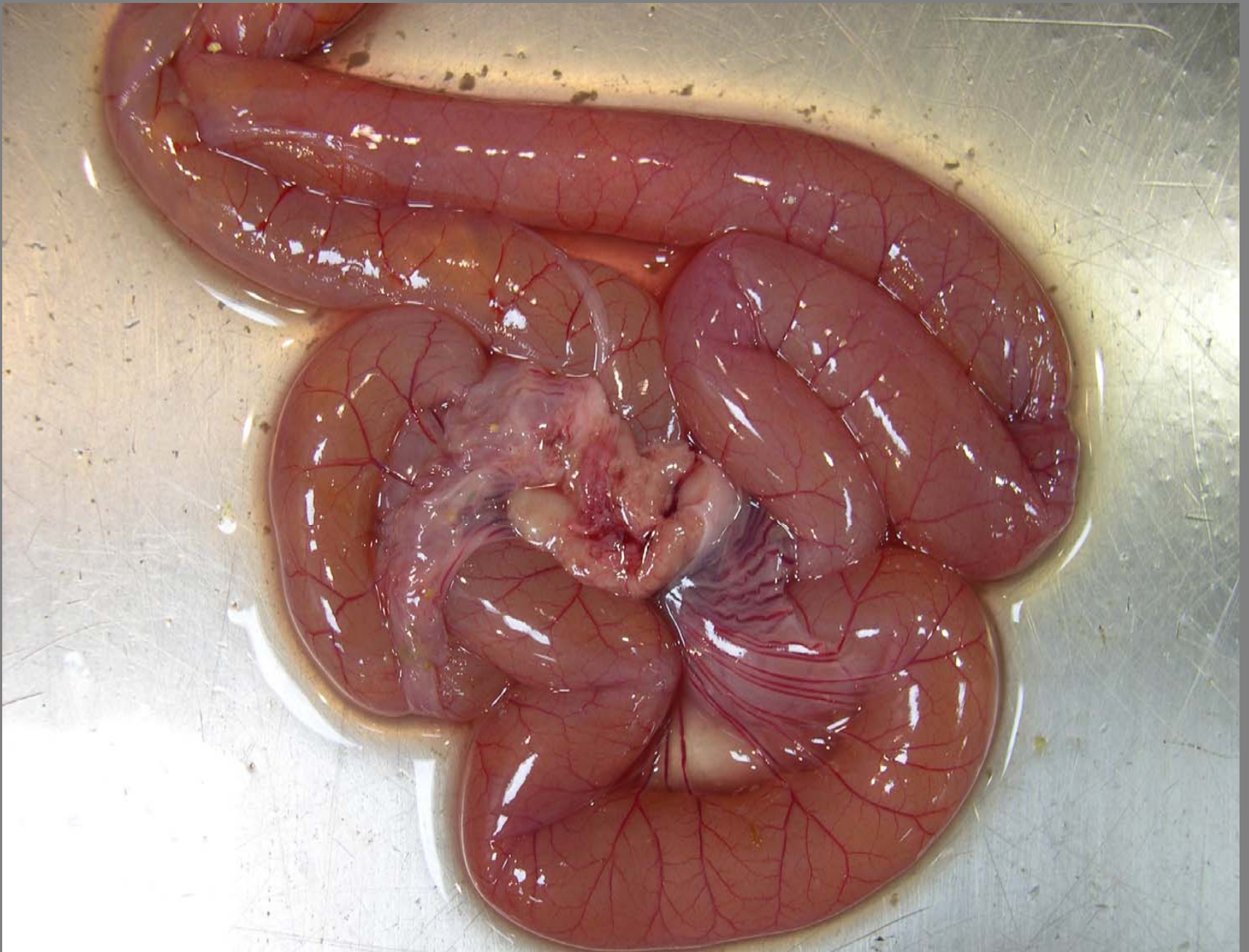
Intestine – segmental necrotizing enteritis – *Salmonella* spp.



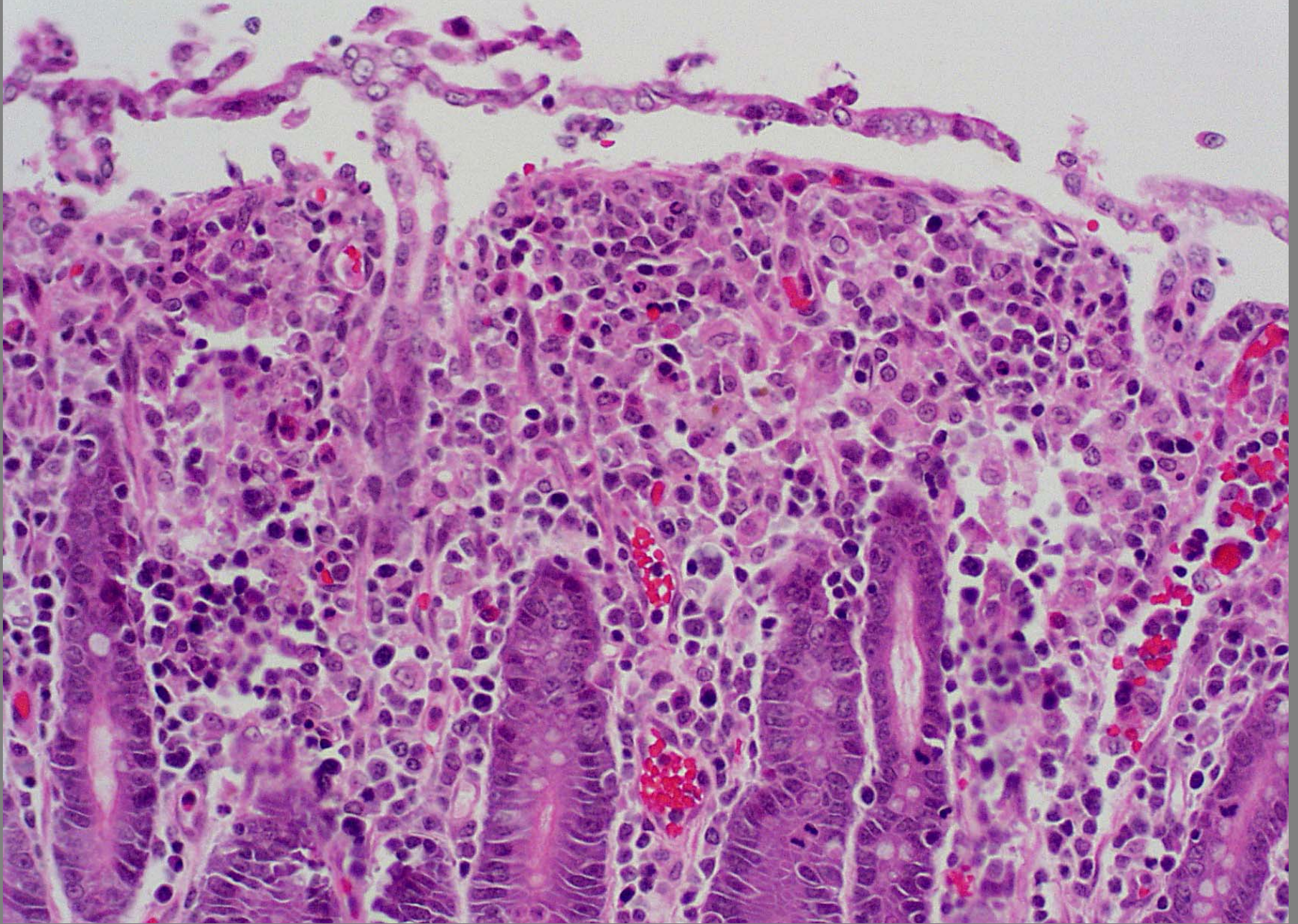
Intestine – segmental necrotizing enteritis – *Salmonella* spp.



Intestine – fibrinous croupal and diphtheritic enteritis – *Salmonella* spp.



Intestine – catarrhal enteritis – *Salmonella* spp. + *Isospora* + *Cryptosporidium* + *E. coli*



Intestine – chronic histiocytic, lymphocytic, plasmacytic enteritis – *Salmonella* spp. + *Cryptosporidium*.