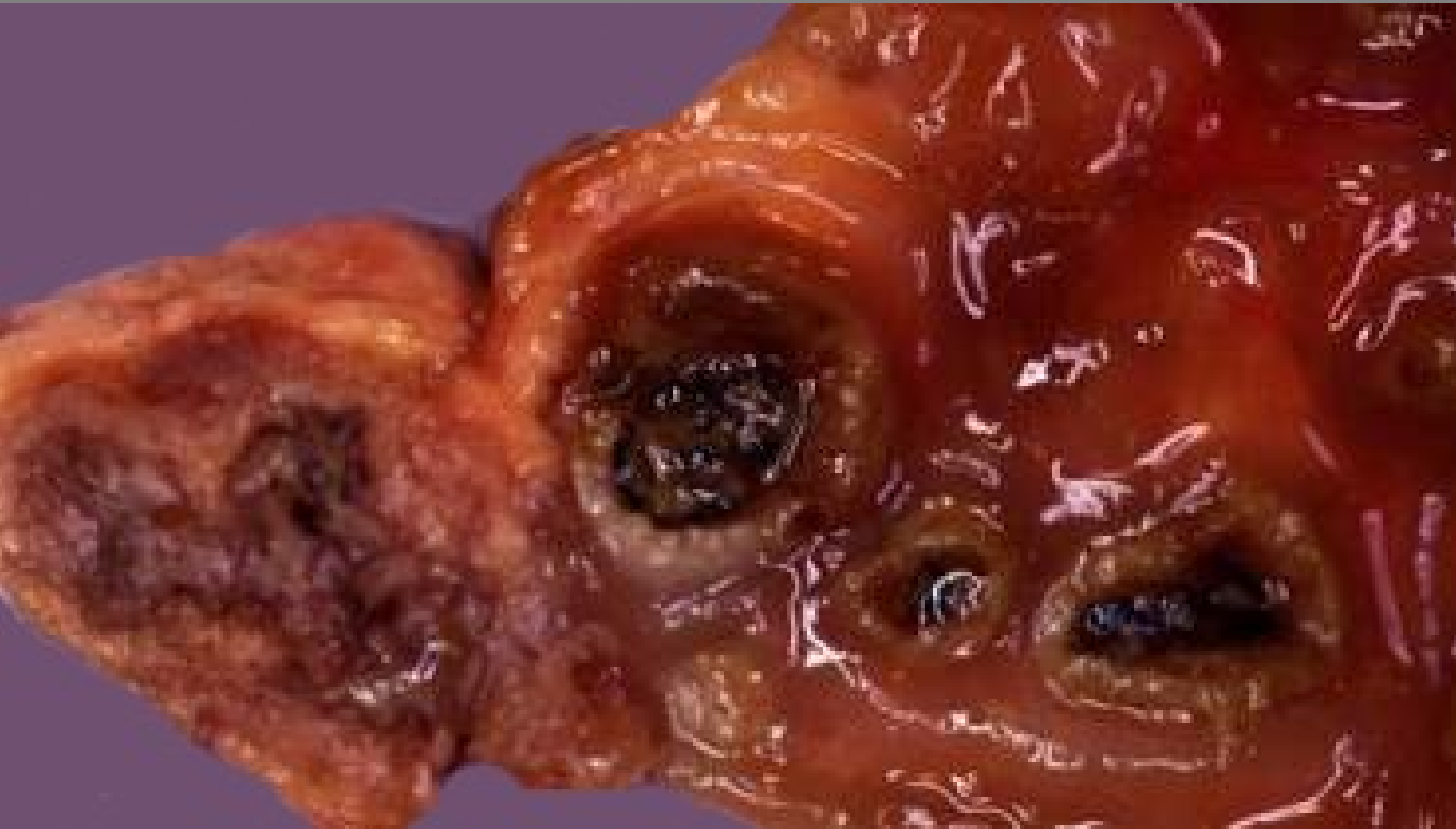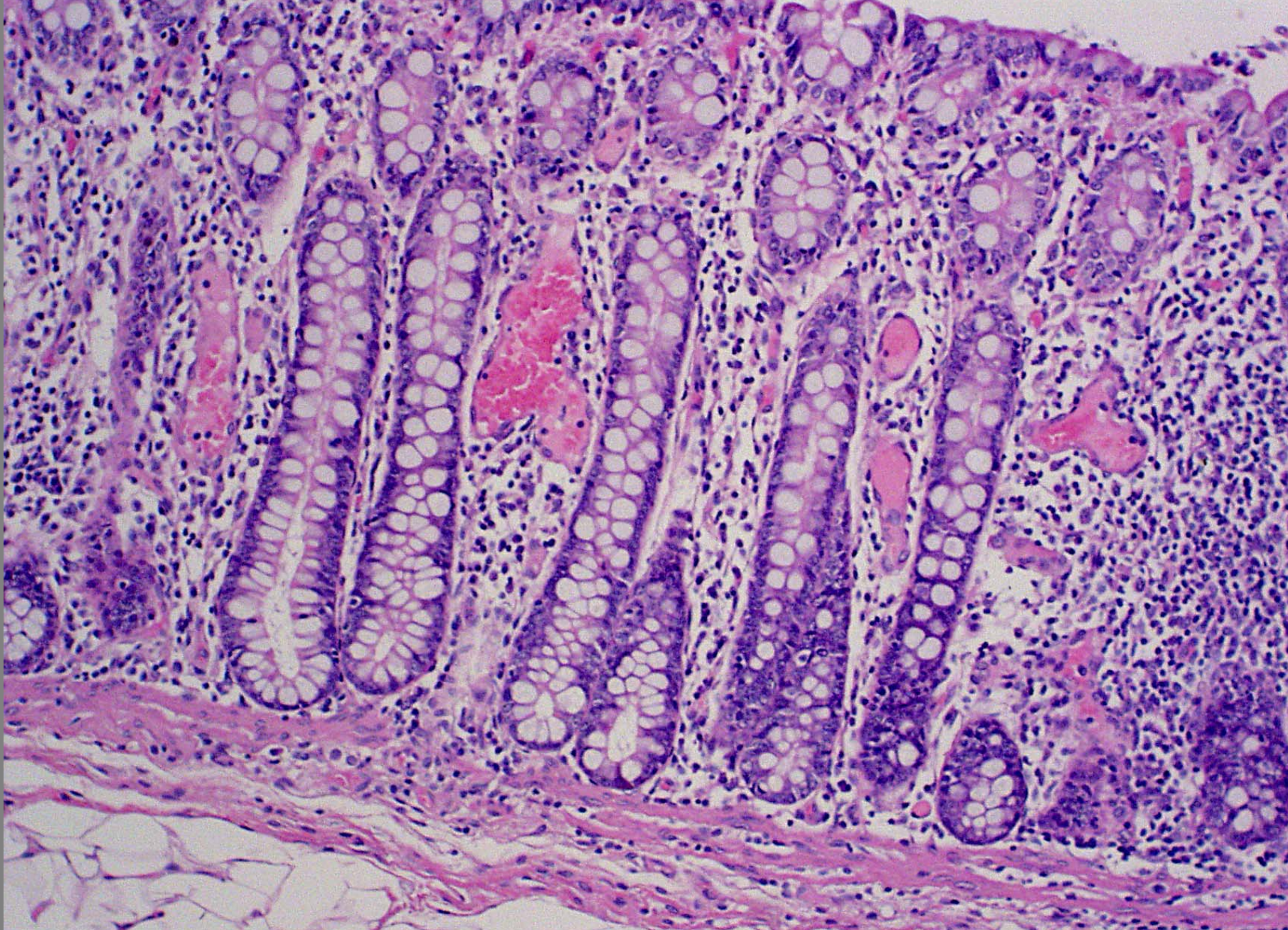

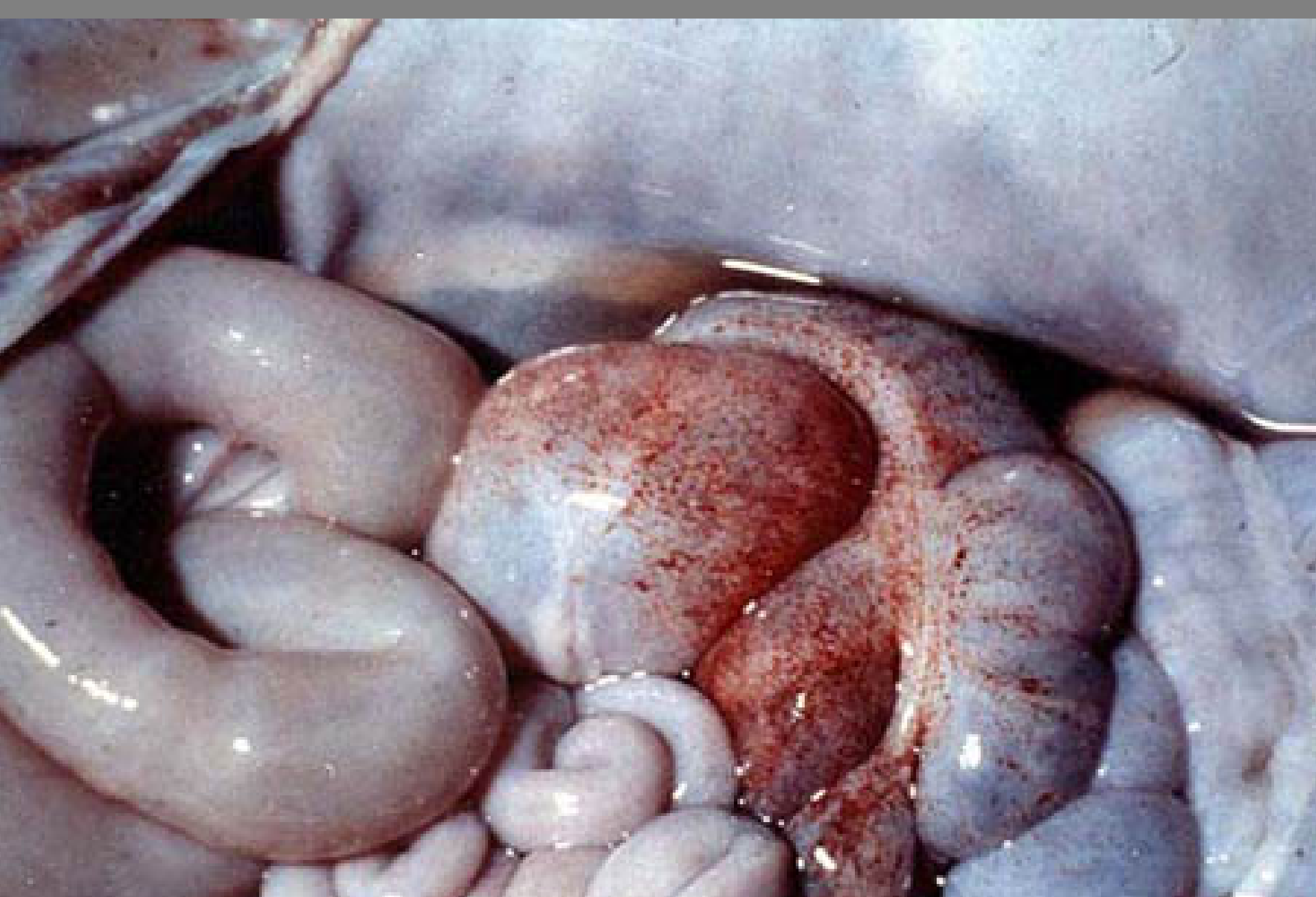


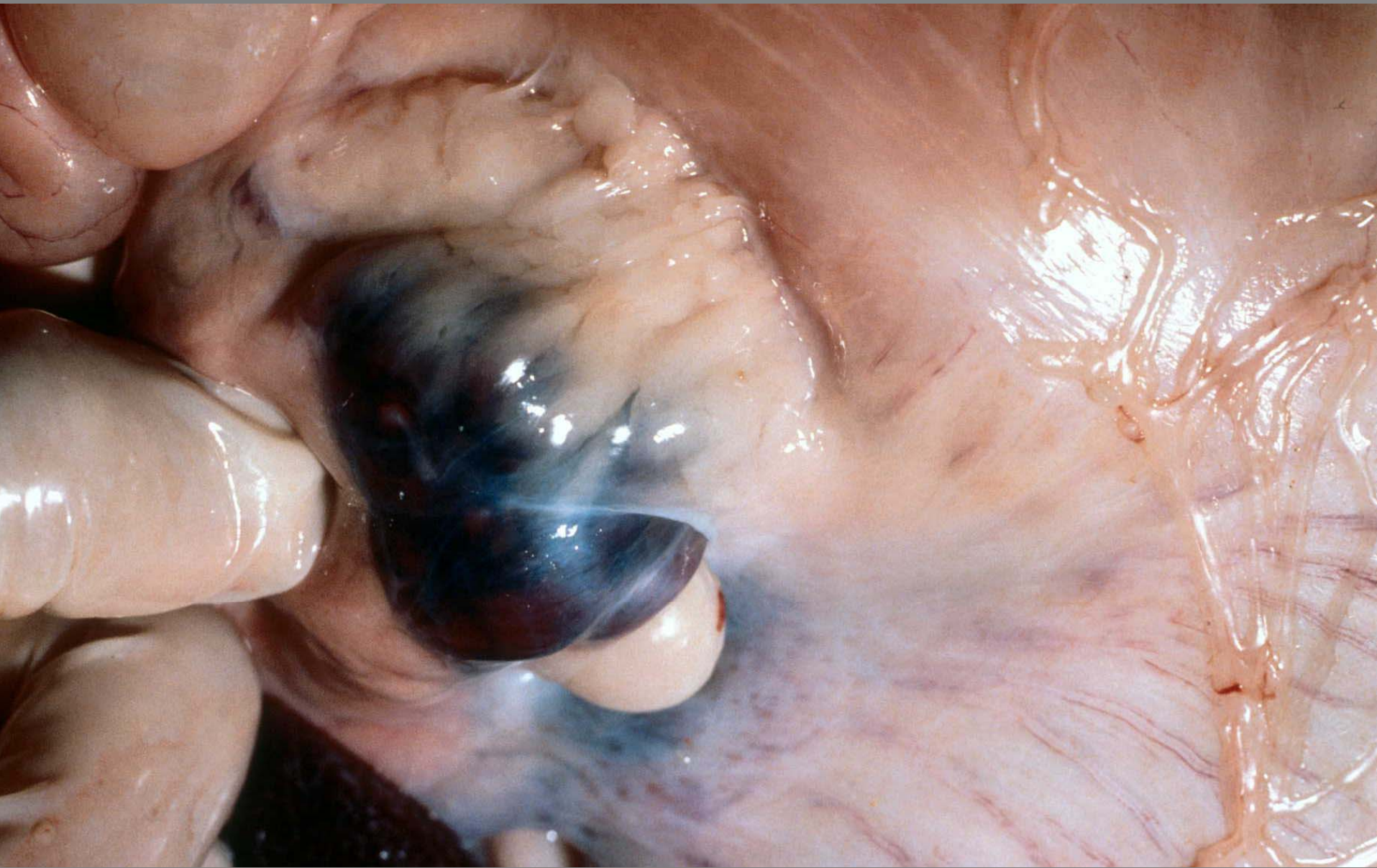
Intestine – necrosis of Peyer's patches – DD: sepsis, viral infection – CSF
norovirus in this case



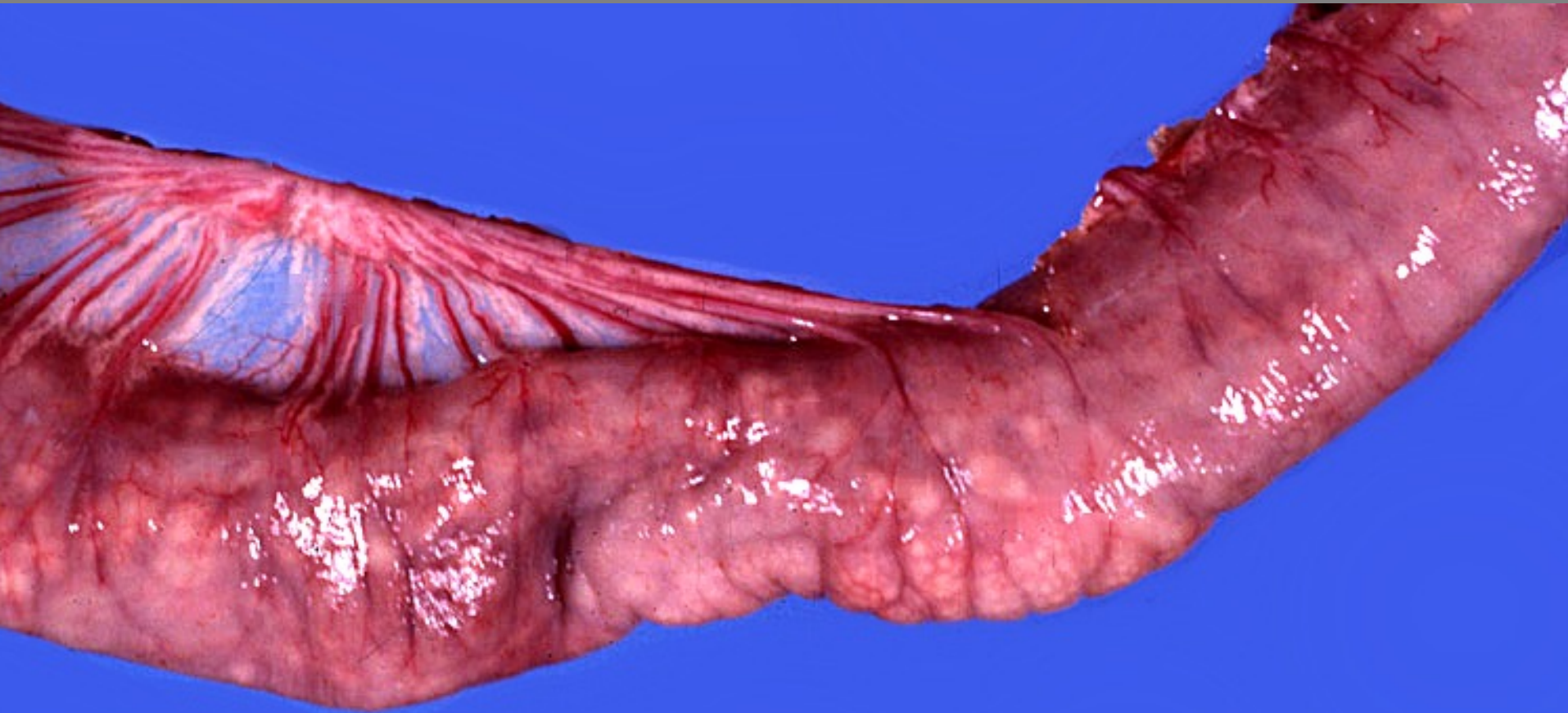
Large intestine – acute microthrombi – CSF pestivirus



Large intestine – acute hemorrhage – ASF virus



Gastrohepatic lymph node – acute hemorrhage – ASF virus



Small intestine – necrotizing enteritis – *Salmonella* spp.