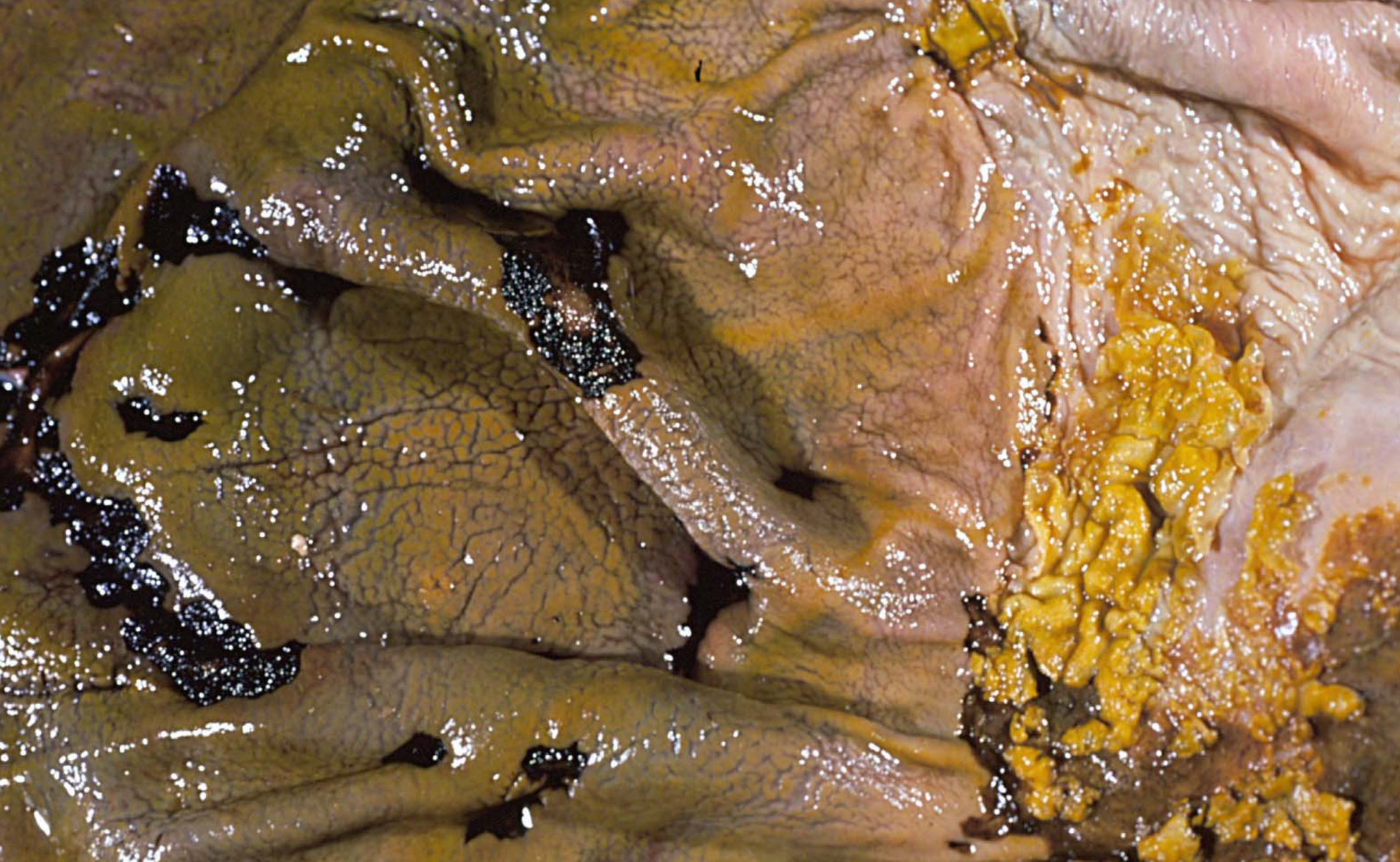
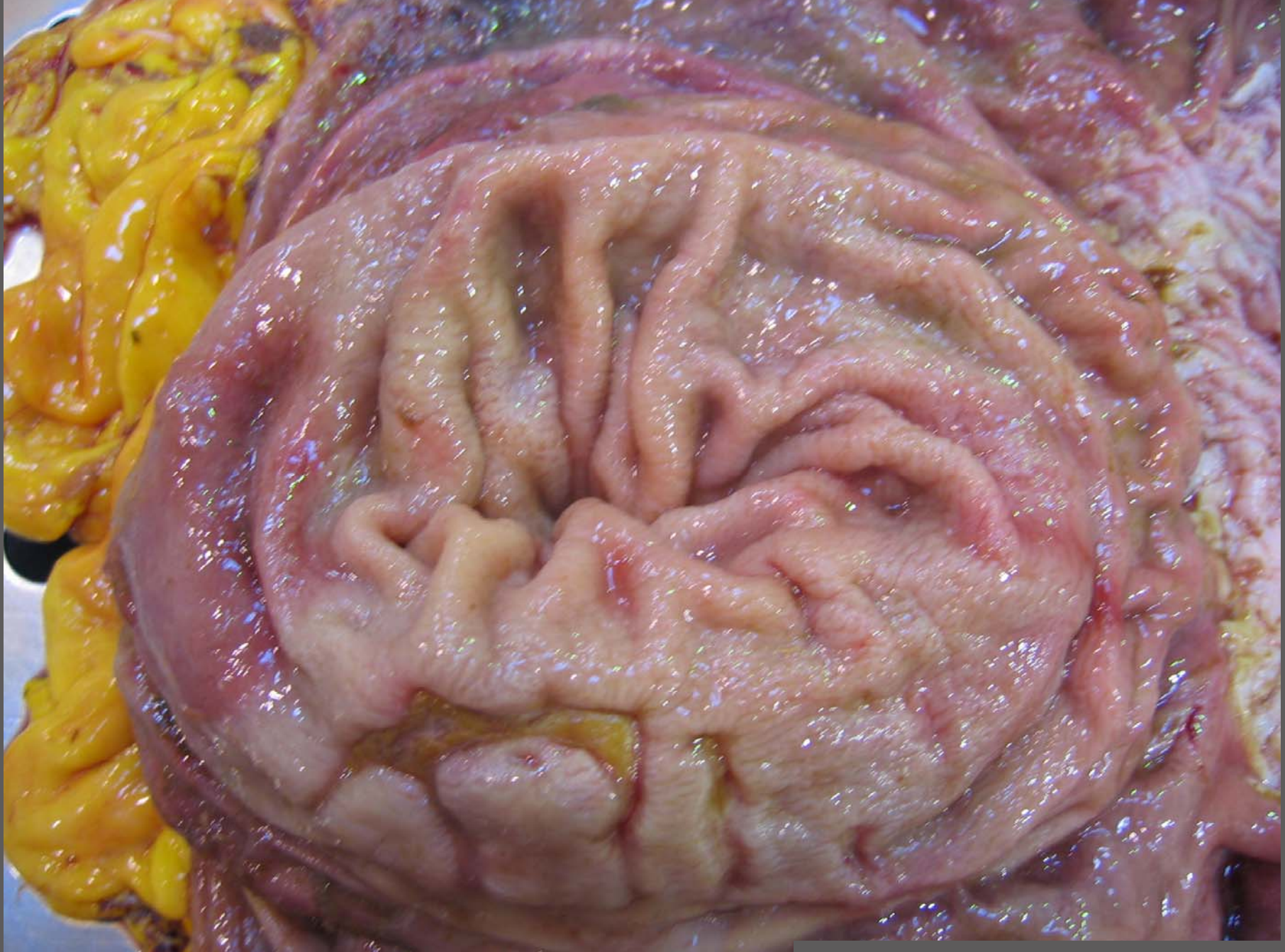


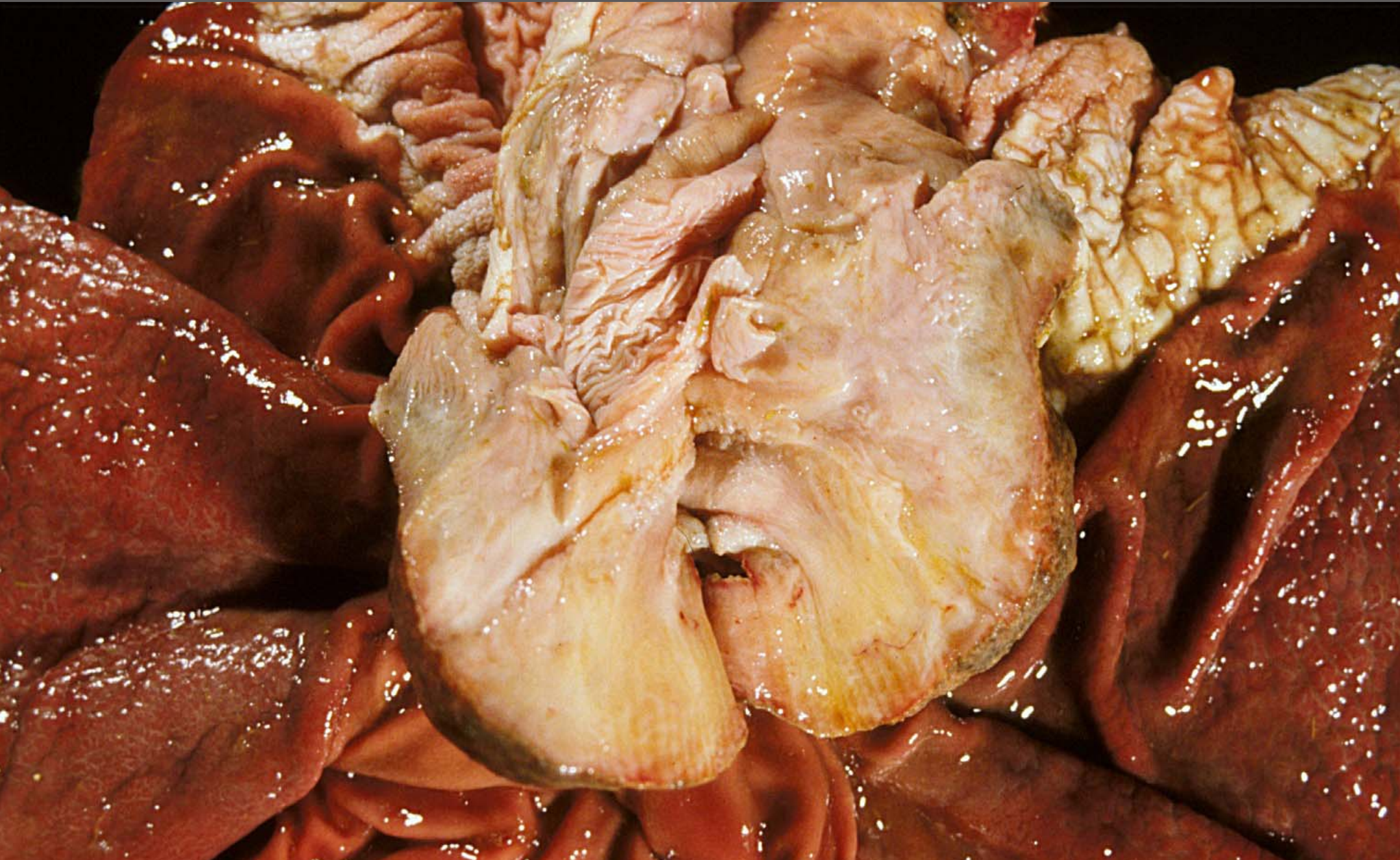Stomach – chronic ulceration with bleeding– NSAID in this case



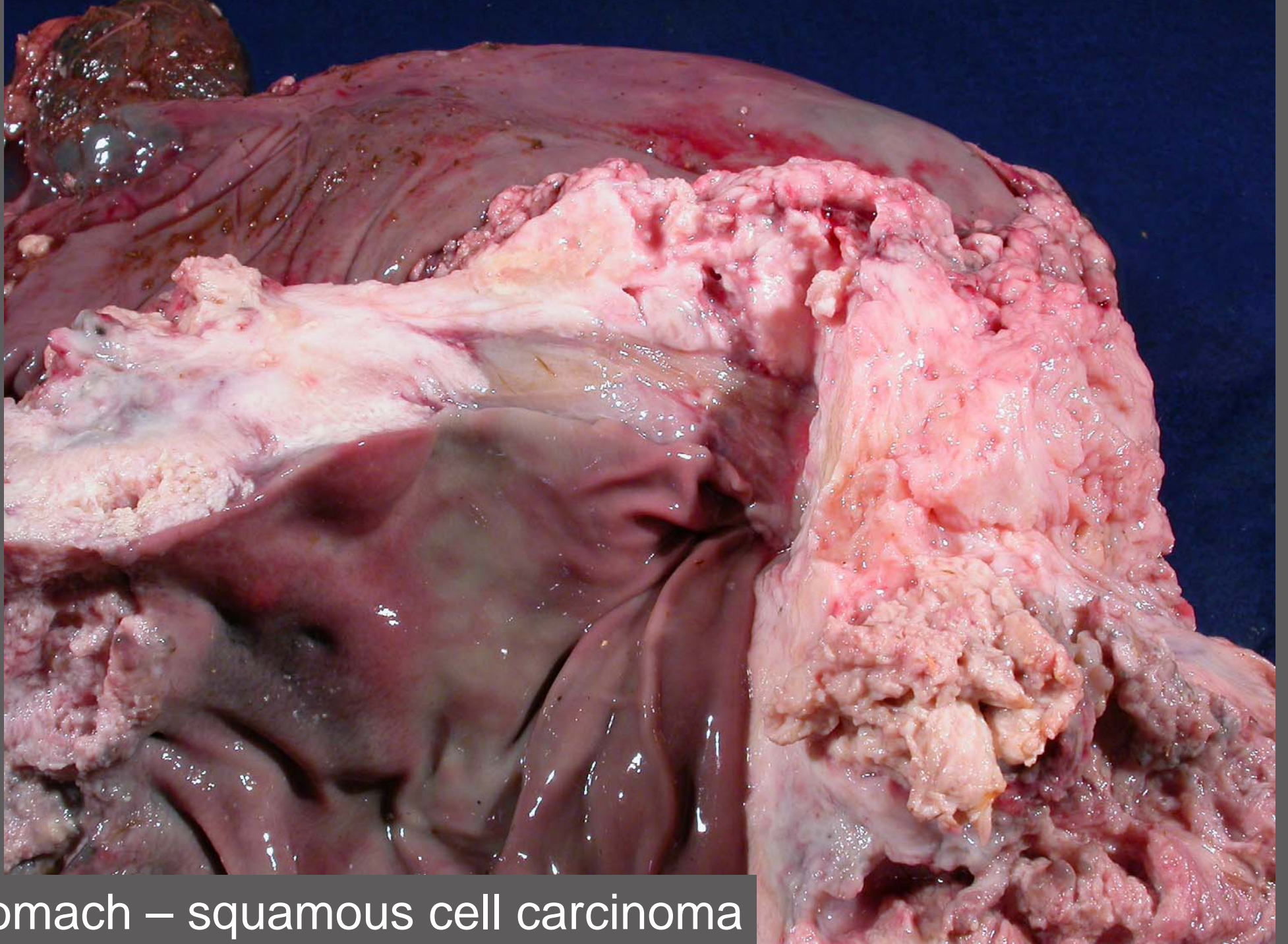
Colon – full thickness hemorrhagic necrosis – NSAID



Stomach – pylorus ulcers



Stomach – squamous cell carcinoma



Stomach – squamous cell carcinoma