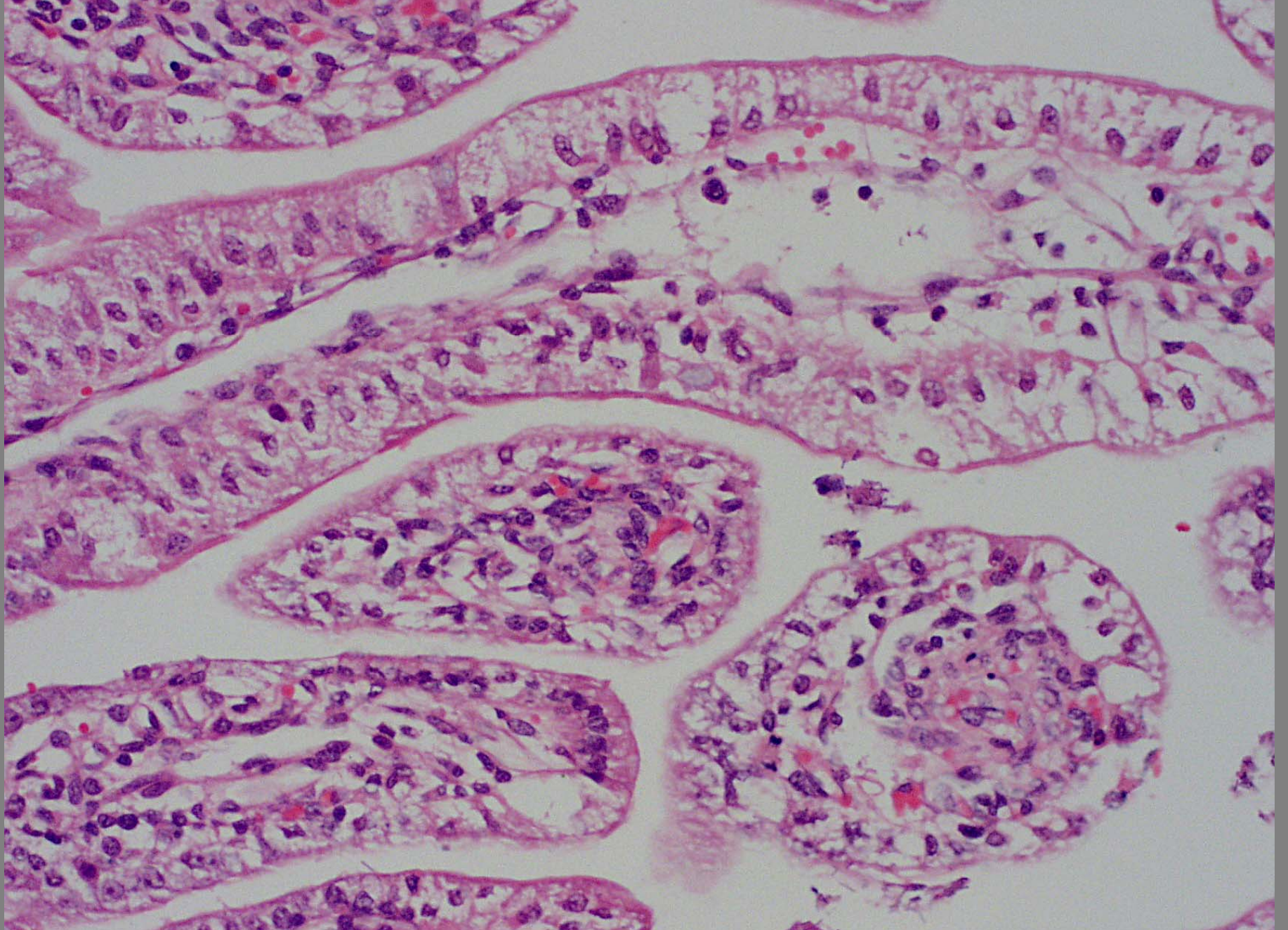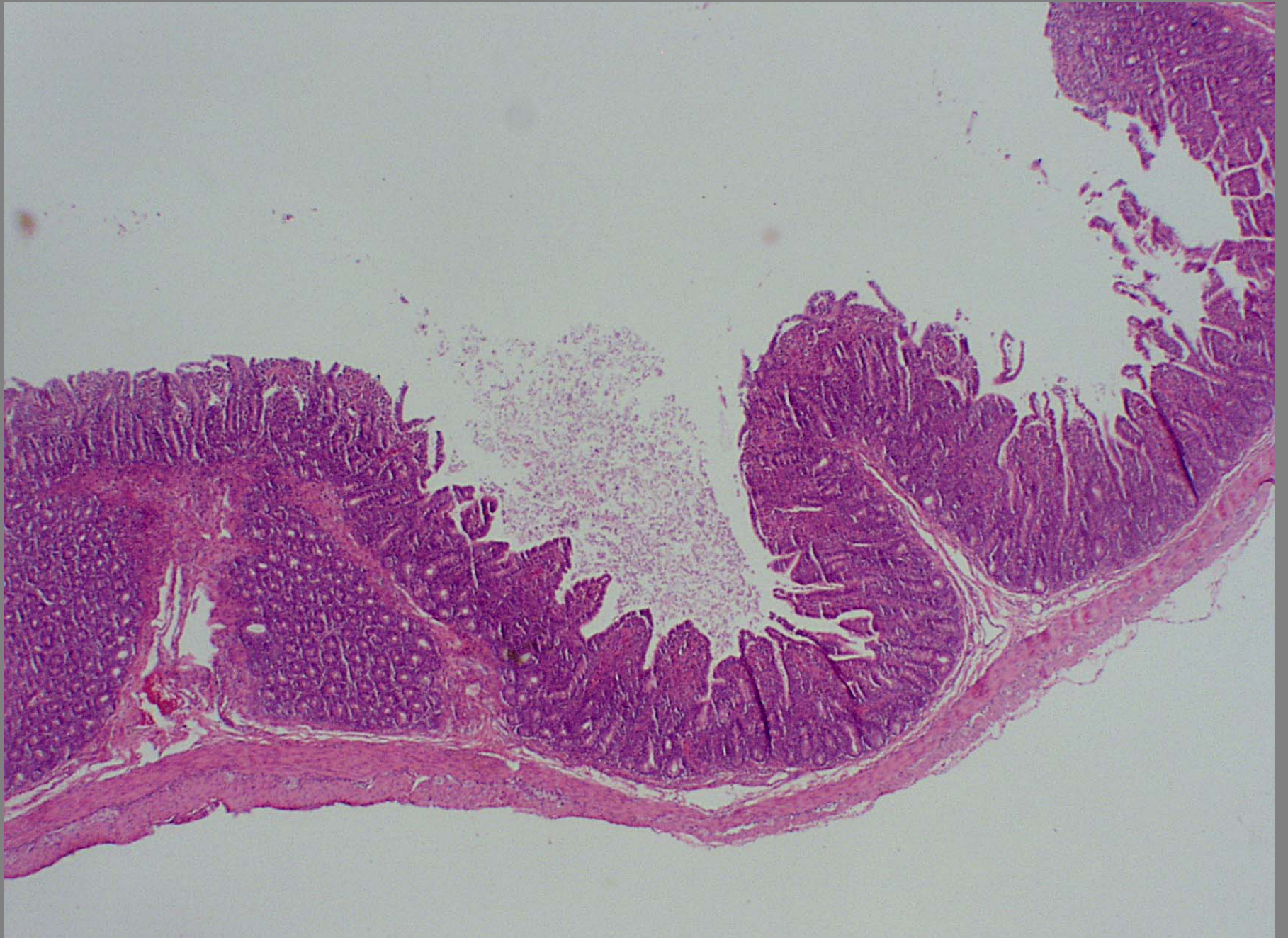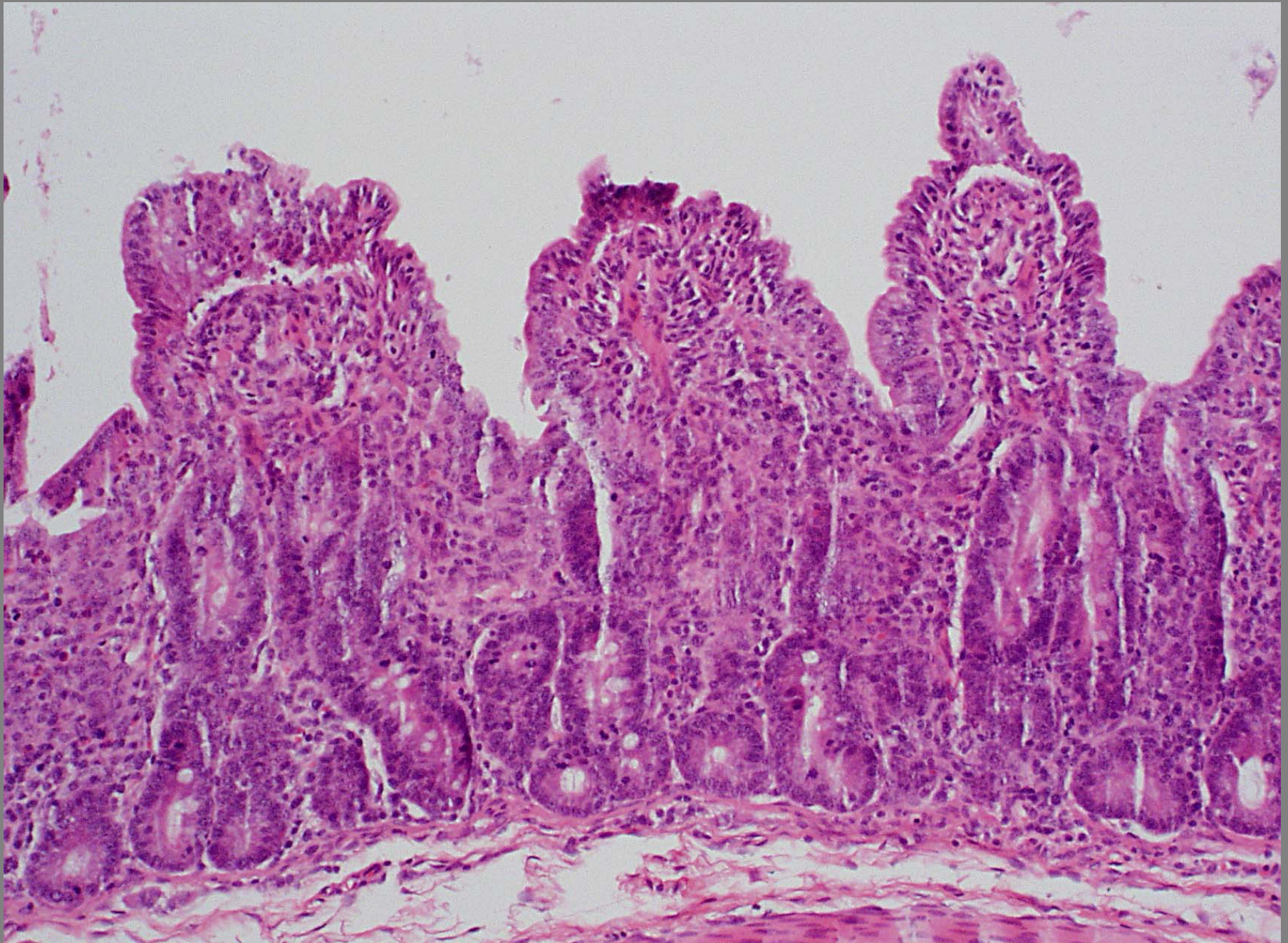


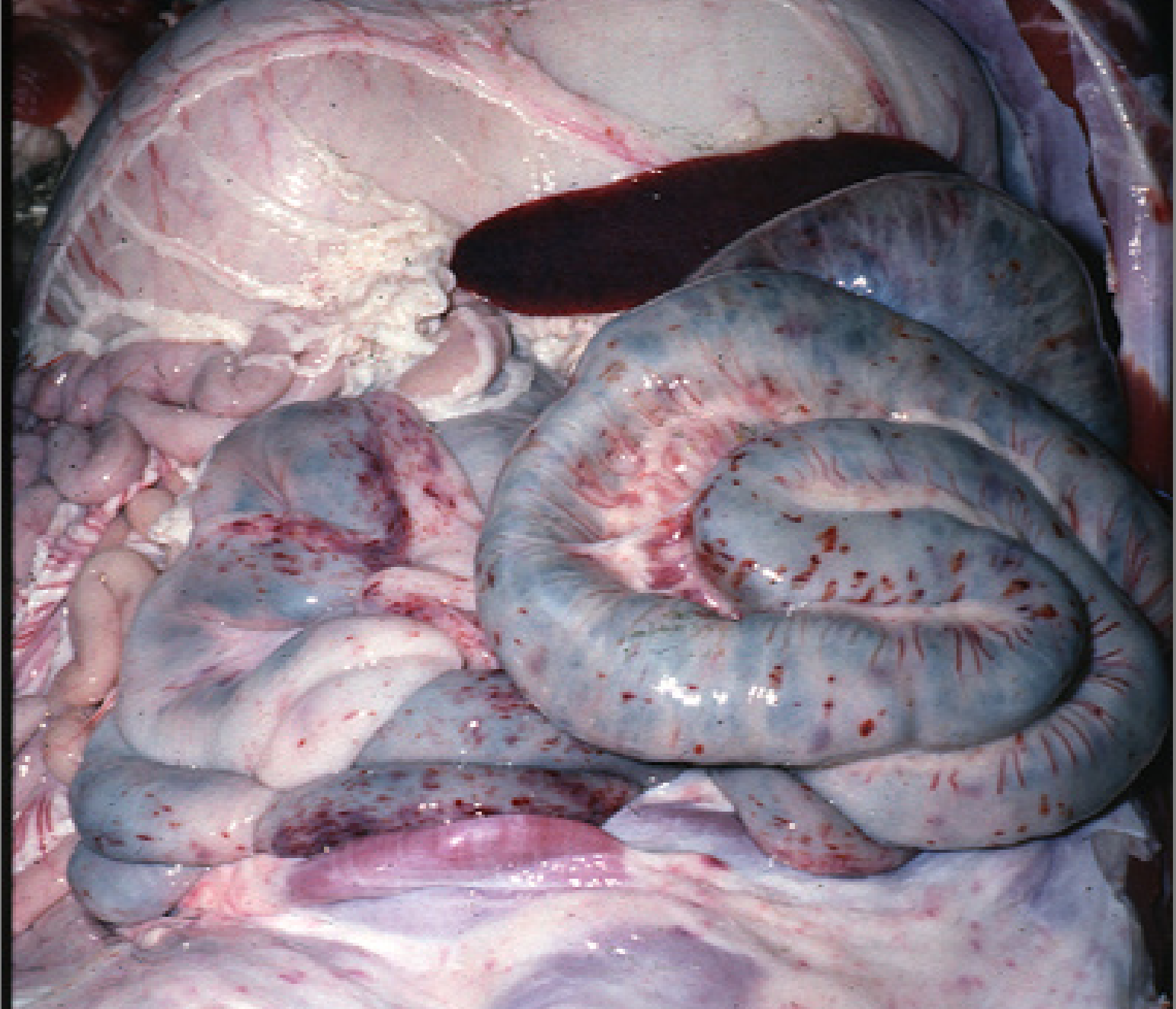
Small intestine – apical vacuolar enteropathy - rotavirus



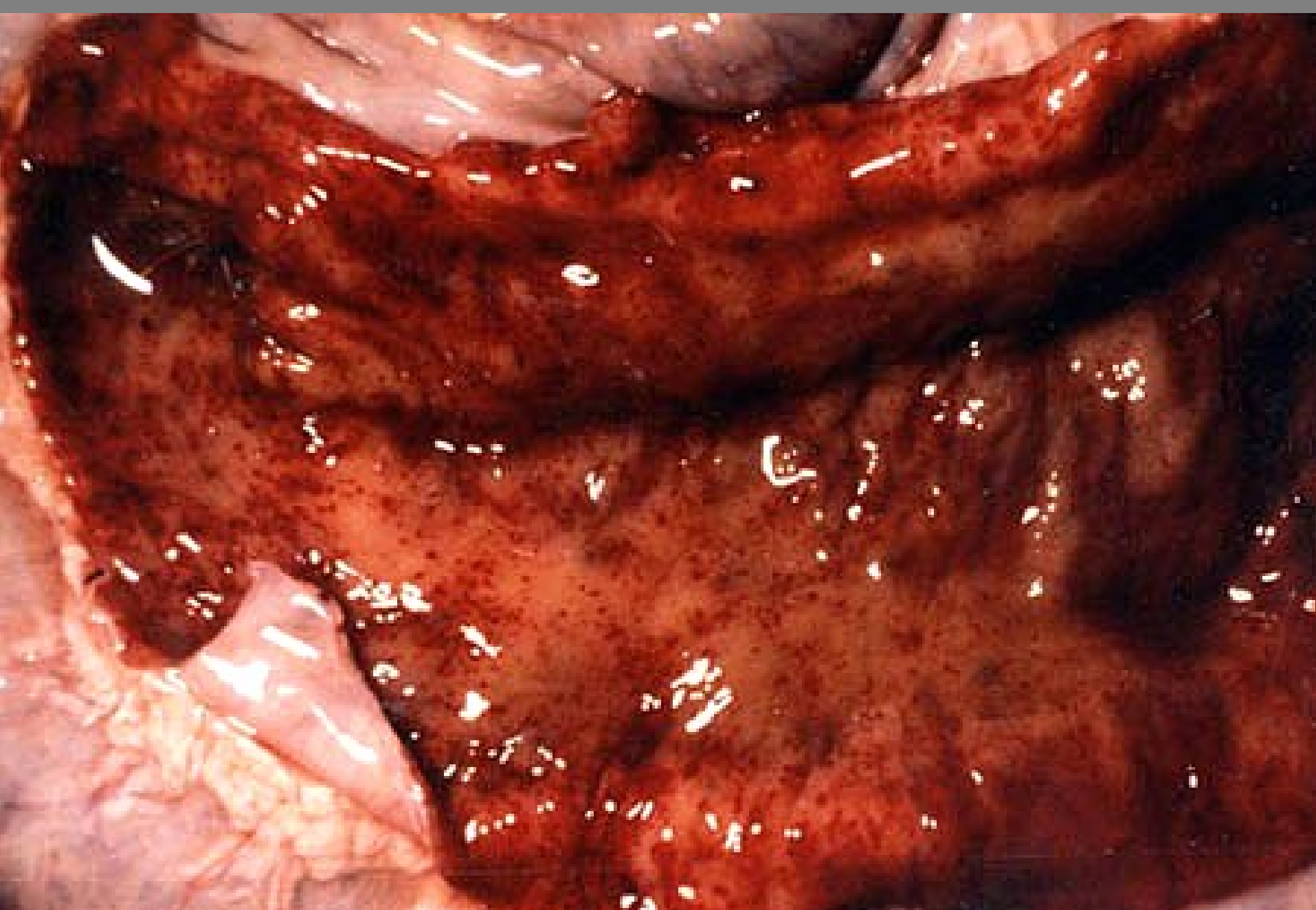
Small intestine – atrophy of villi – TGE



Small intestine – atrophy of villi – TGE coronavirus infection



Intestine – petechiae – DD: sepsis, viral infection – CFS pestivirus in this case



Intestine – petechiae – DD: sepsis, viral infection – CFS pestivirus in this case