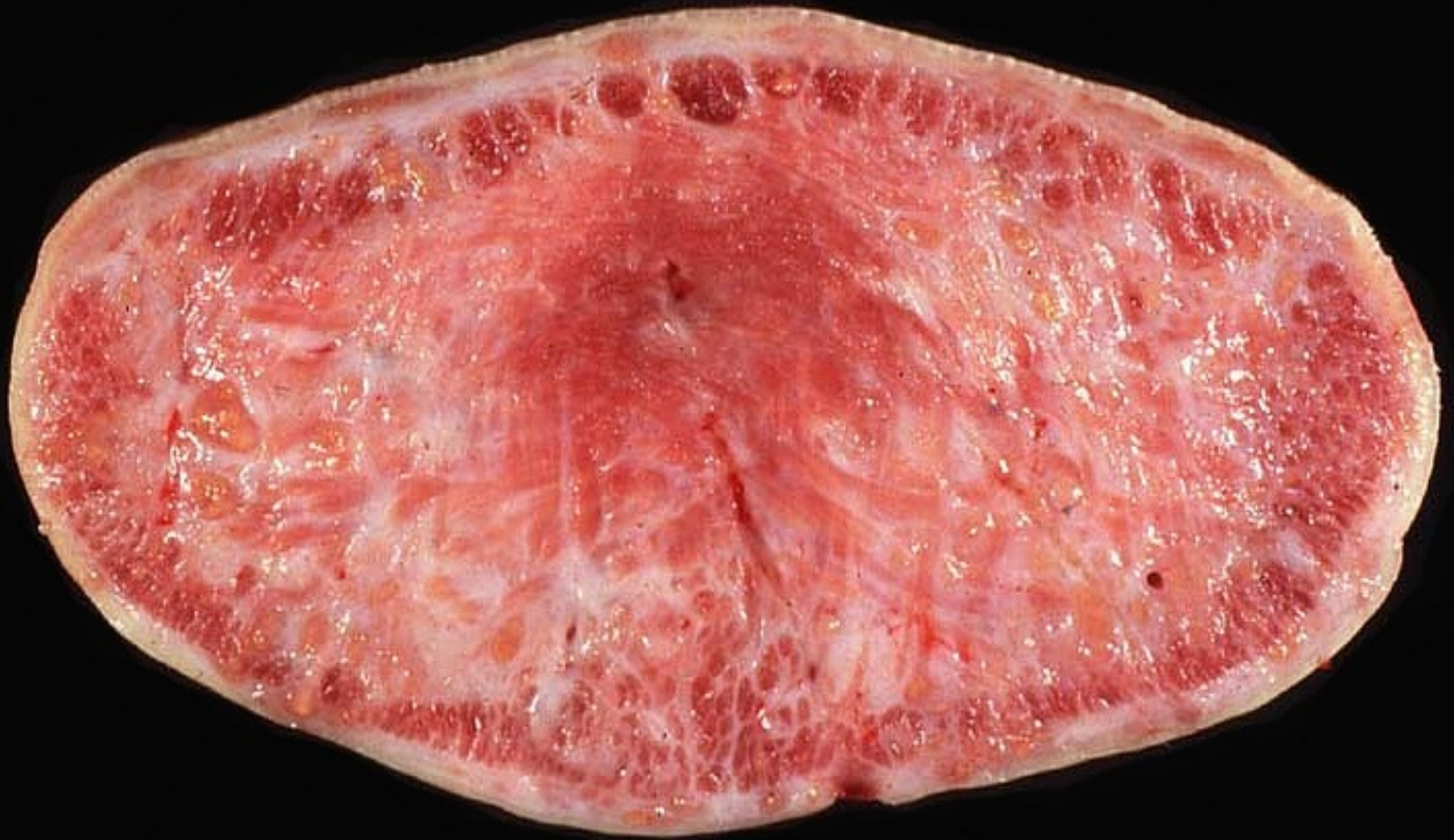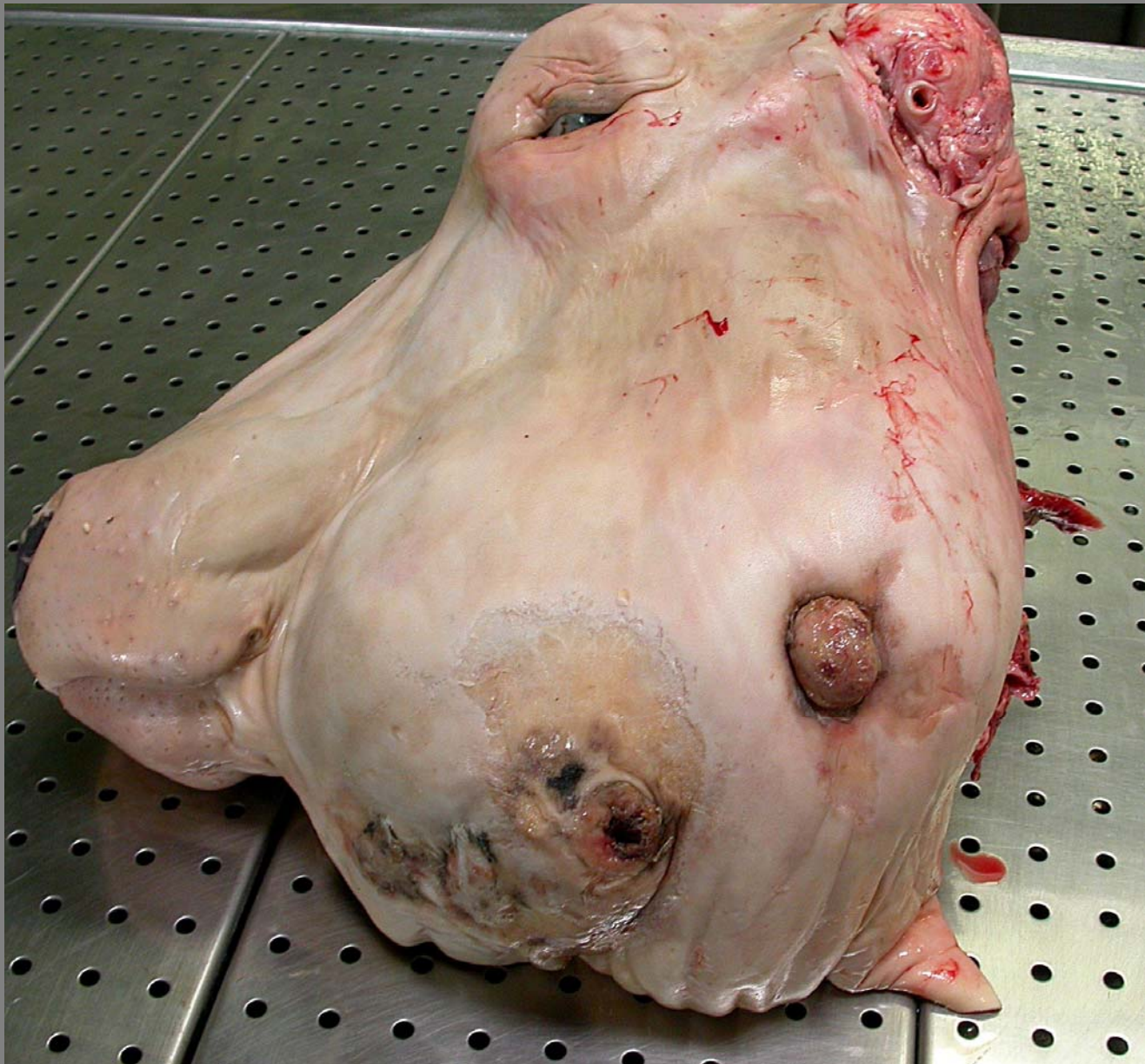
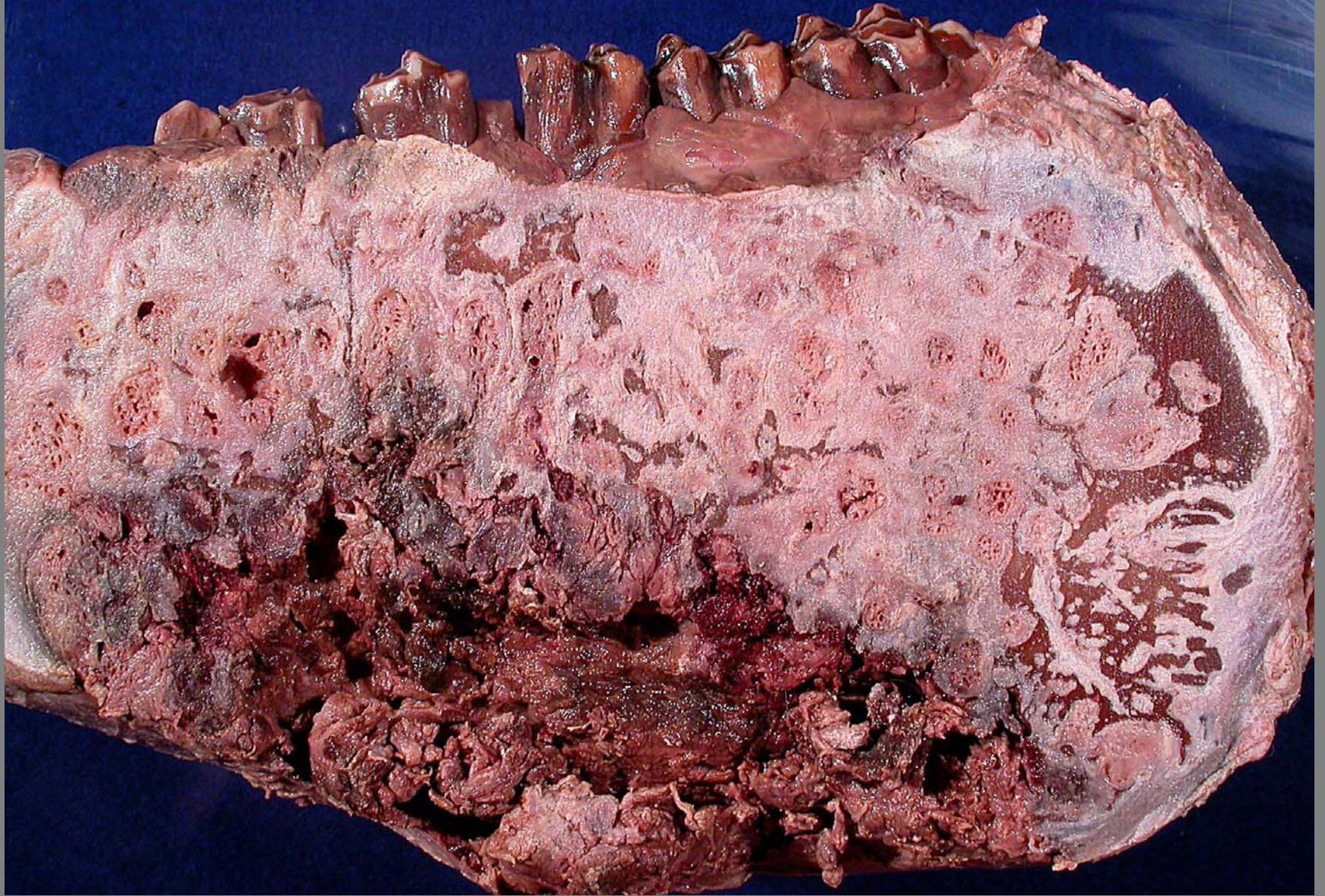


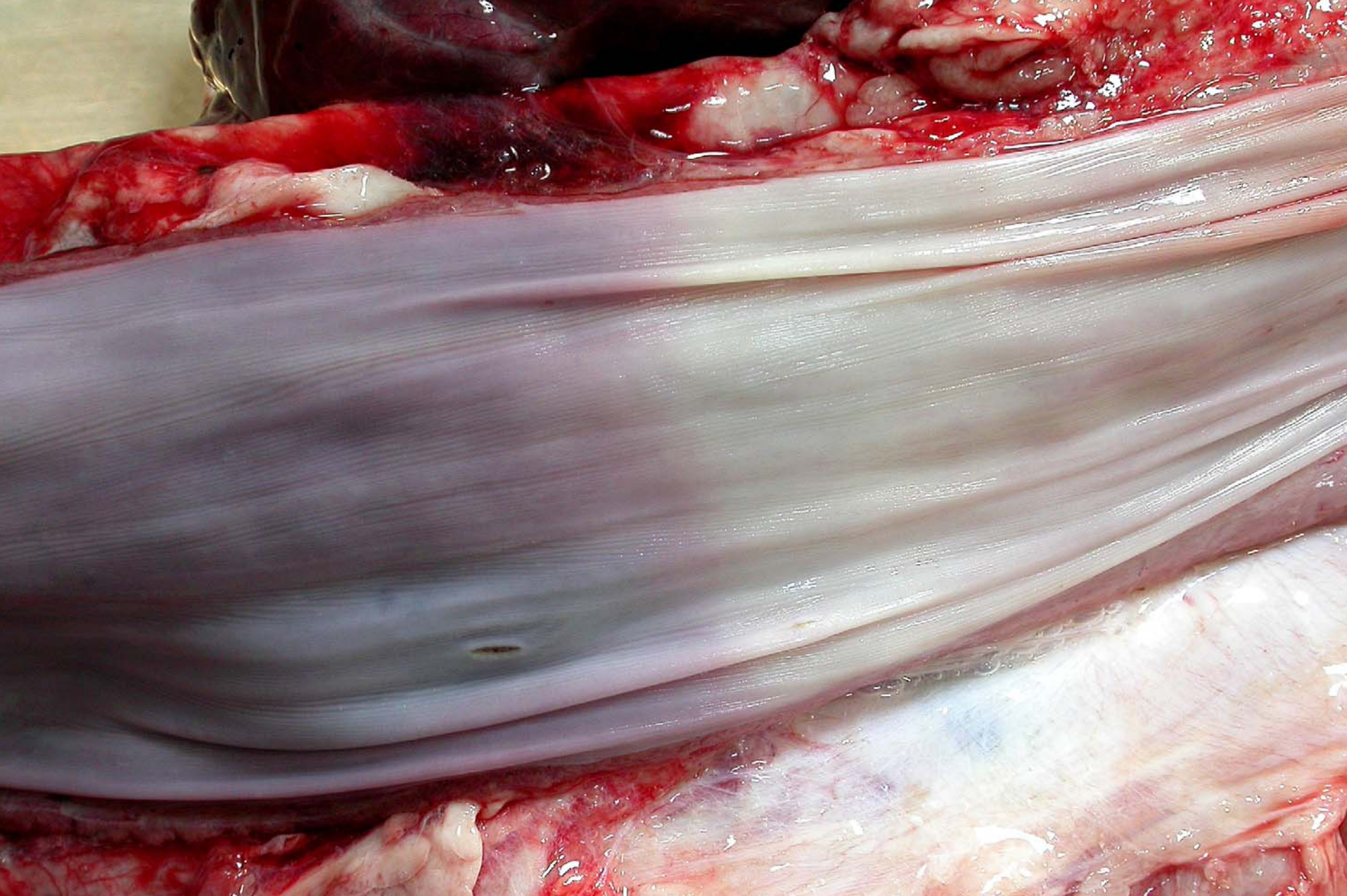**Glossitis, pyogranulomatous - *Actinobacillus lignieresii***  
Courtesy of John Edwards and John M. King




**Jaw – Osteomyelitis pyogranulomatous, chronic, fibrosing, rarefacting – *Actinomyces bovis***



**Jaw – Osteomyelitis pyogranulomatous, chronic, fibrosing, rarefying – *Actinomyces bovis***



**Esophagus - bloat line (*post mortem* or *intra vitam*)**



**Esophagus – erosive, ulcerative esophagitis – BVD pestivirus**