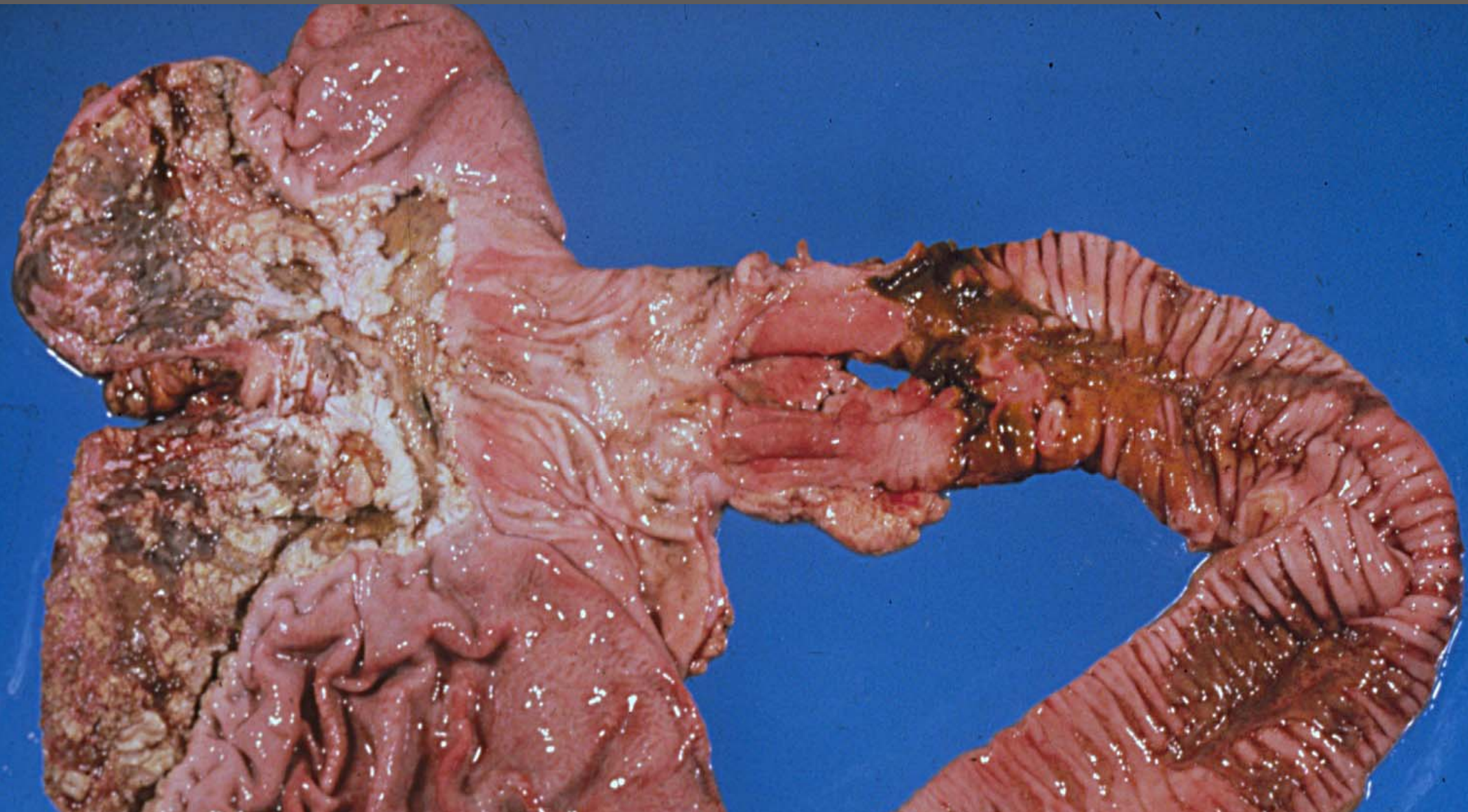
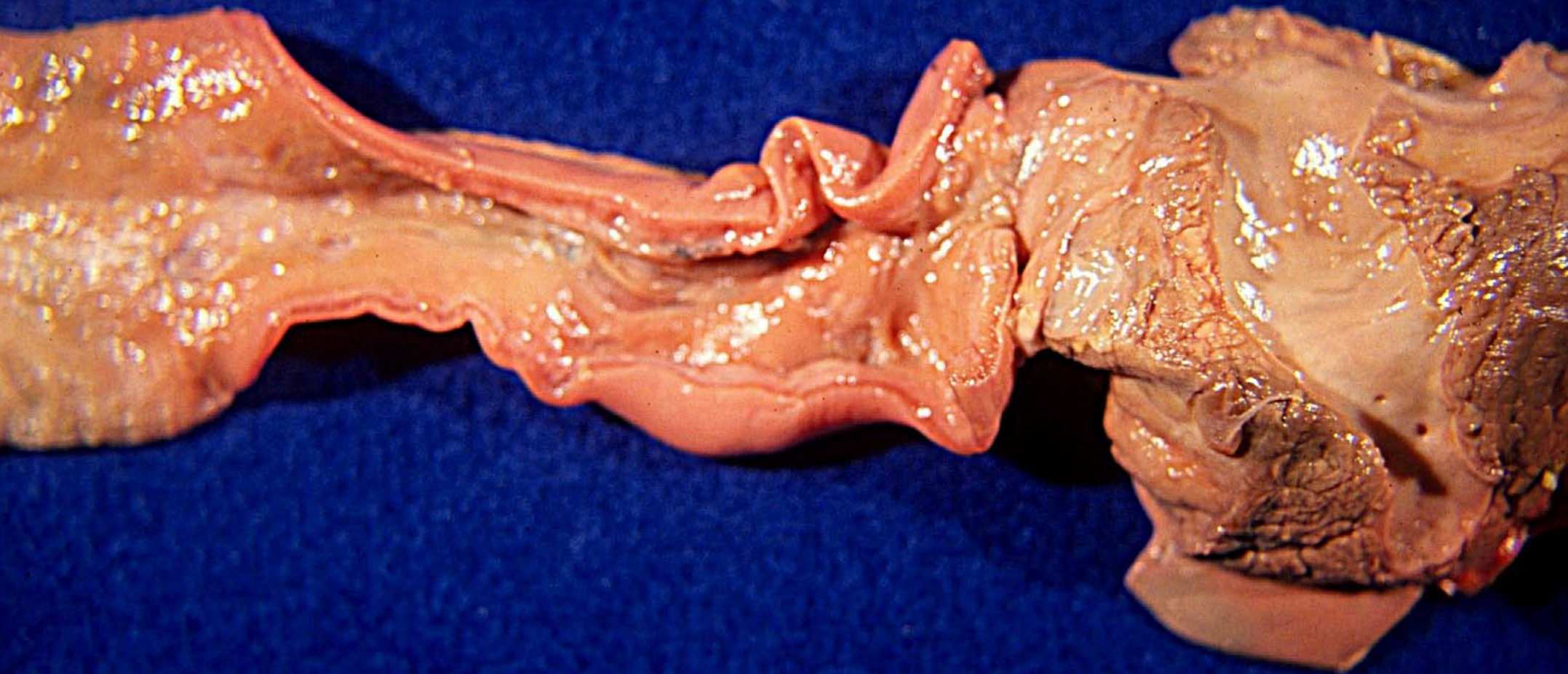
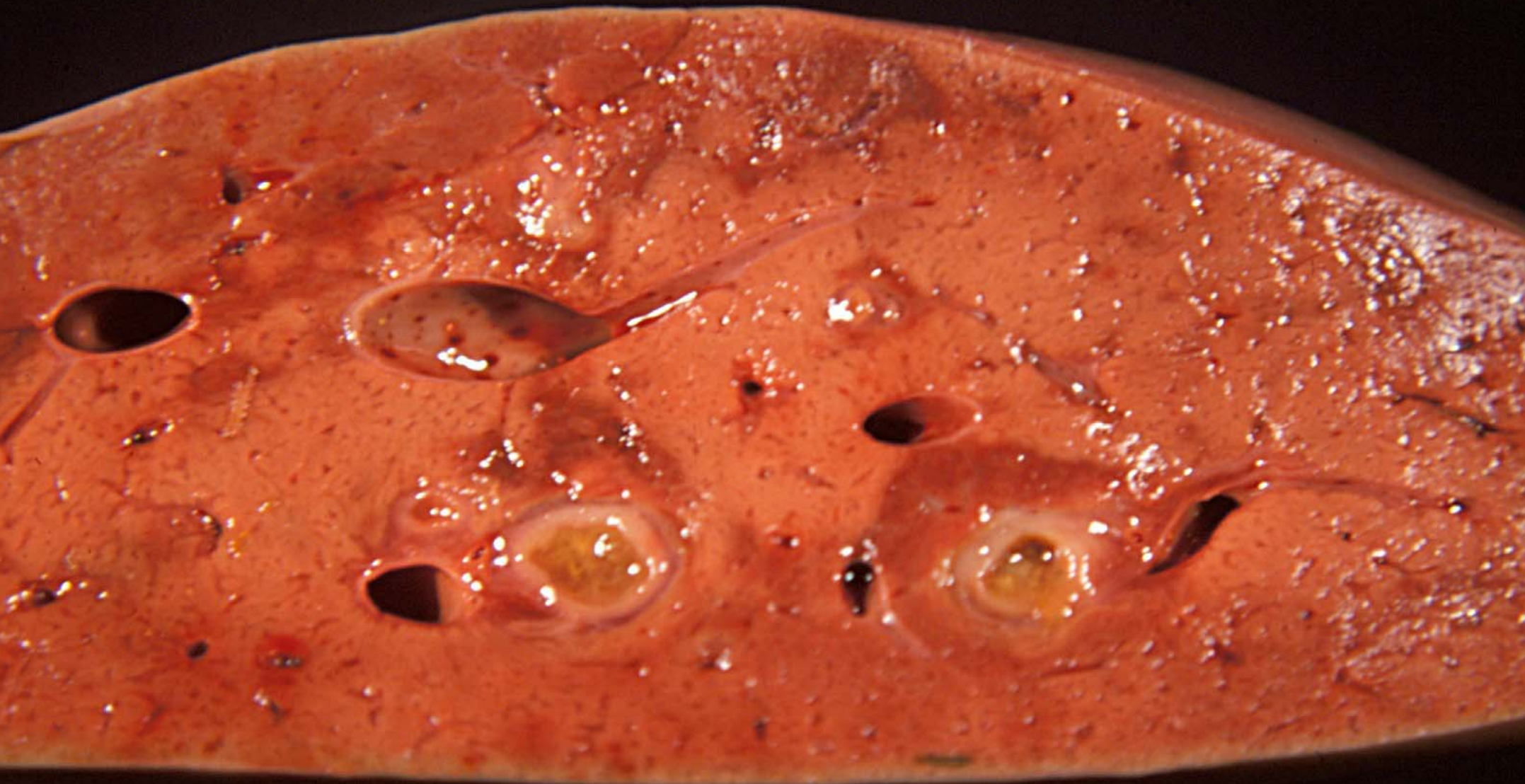
Foal – stomach, duodenum – erosions, ulcers with duodenal ulceration and perforation (J.M. King)





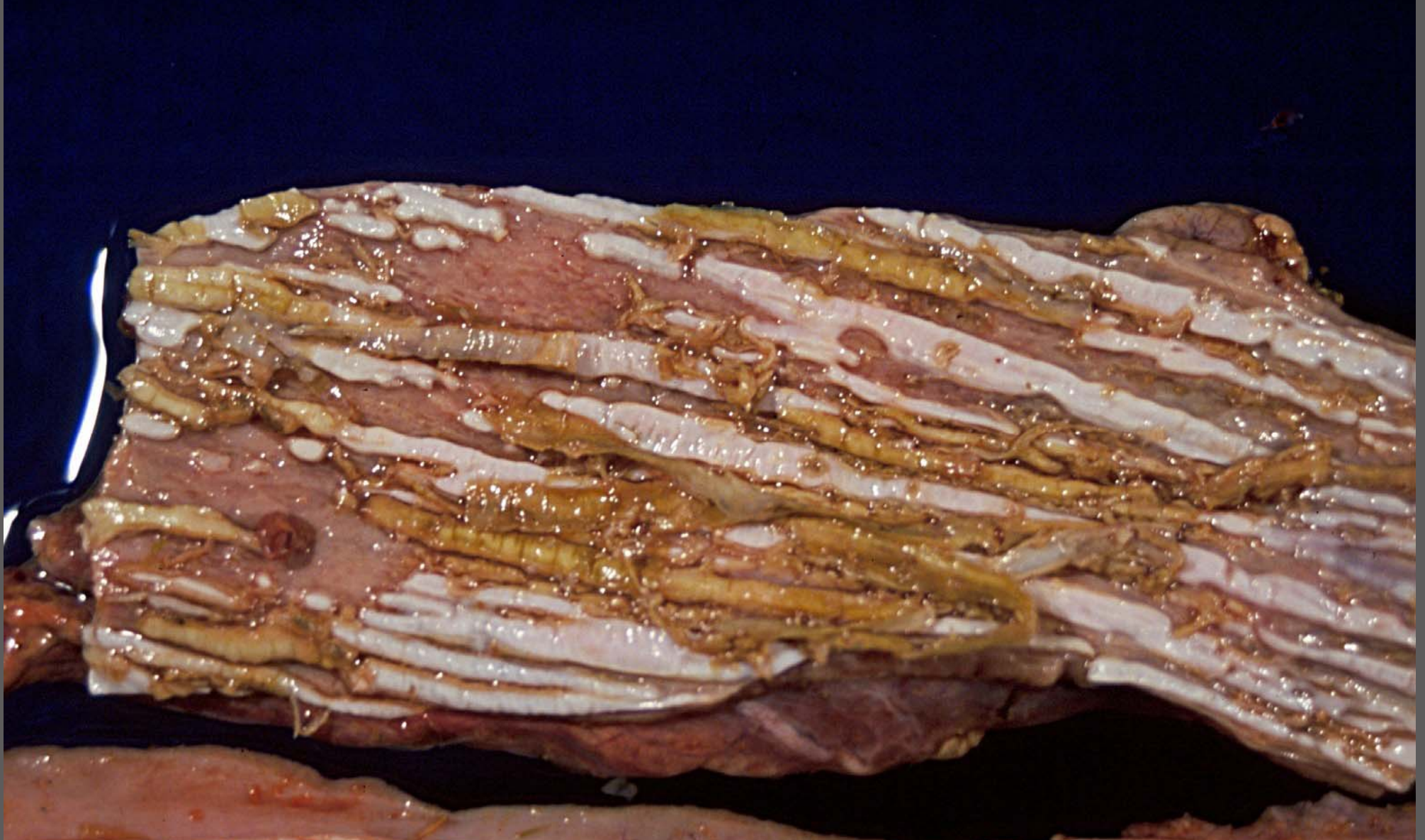Foal – duodenum – stenosis with pancreatic duct dilatation





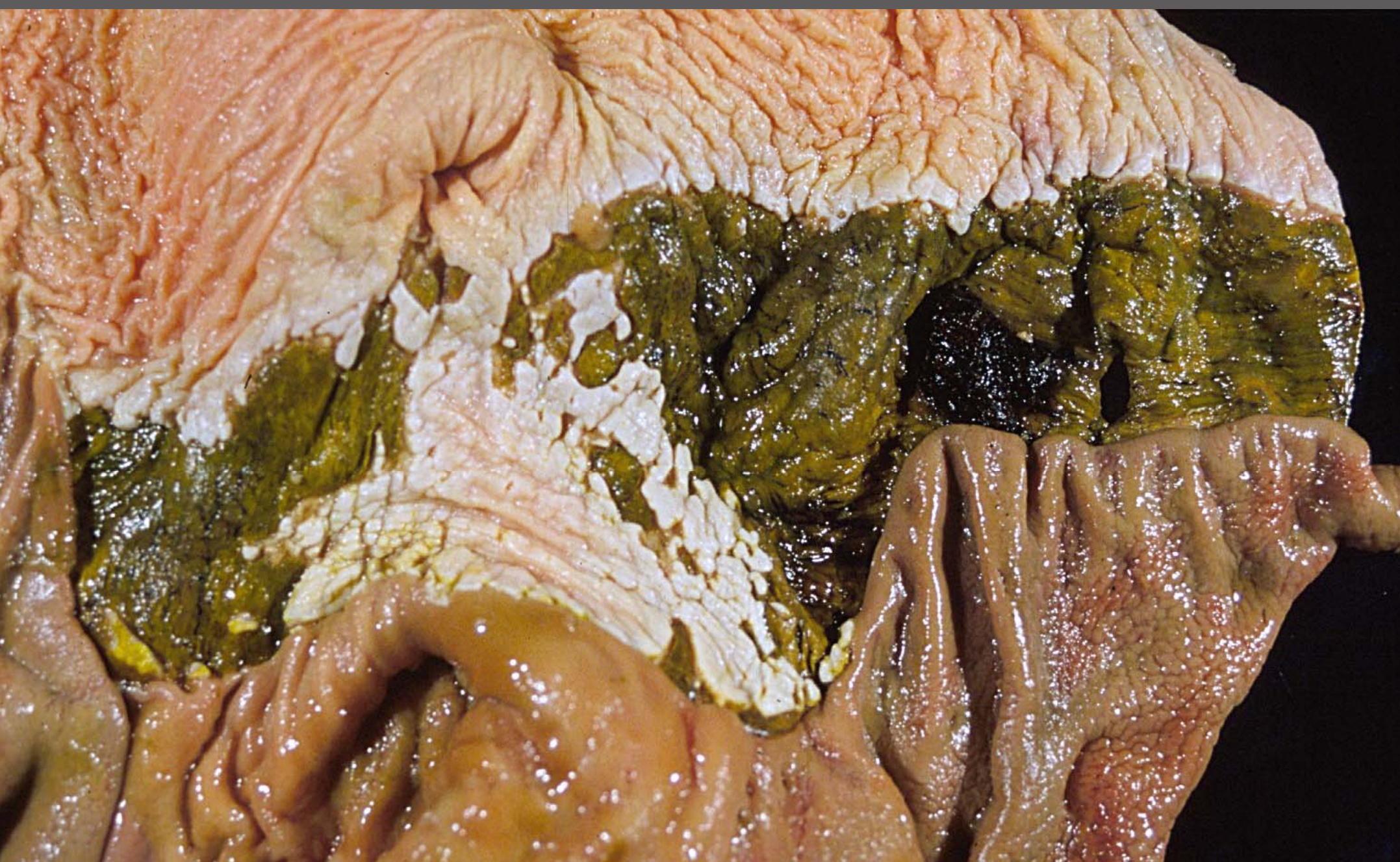Foal – liver – severe cholestasis secondary to duodenal stenosis





Foal – esophagus – ascending esophageal linear ulceration secondary to gastric abnormal emptying due to duodenal stenosis secondary to previous ulceration





Stomach – extensive *pars squamosa* ulceration with perforation