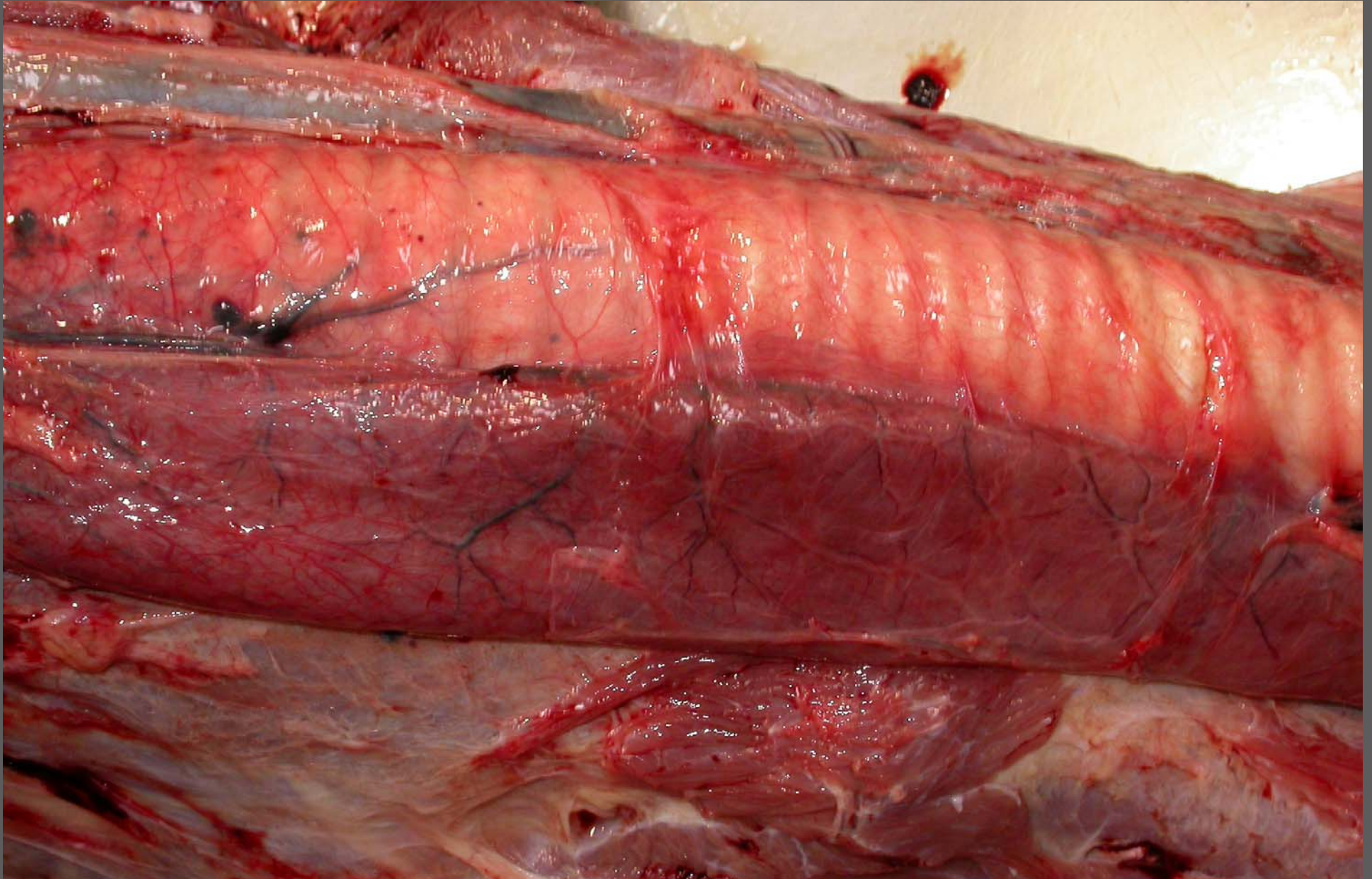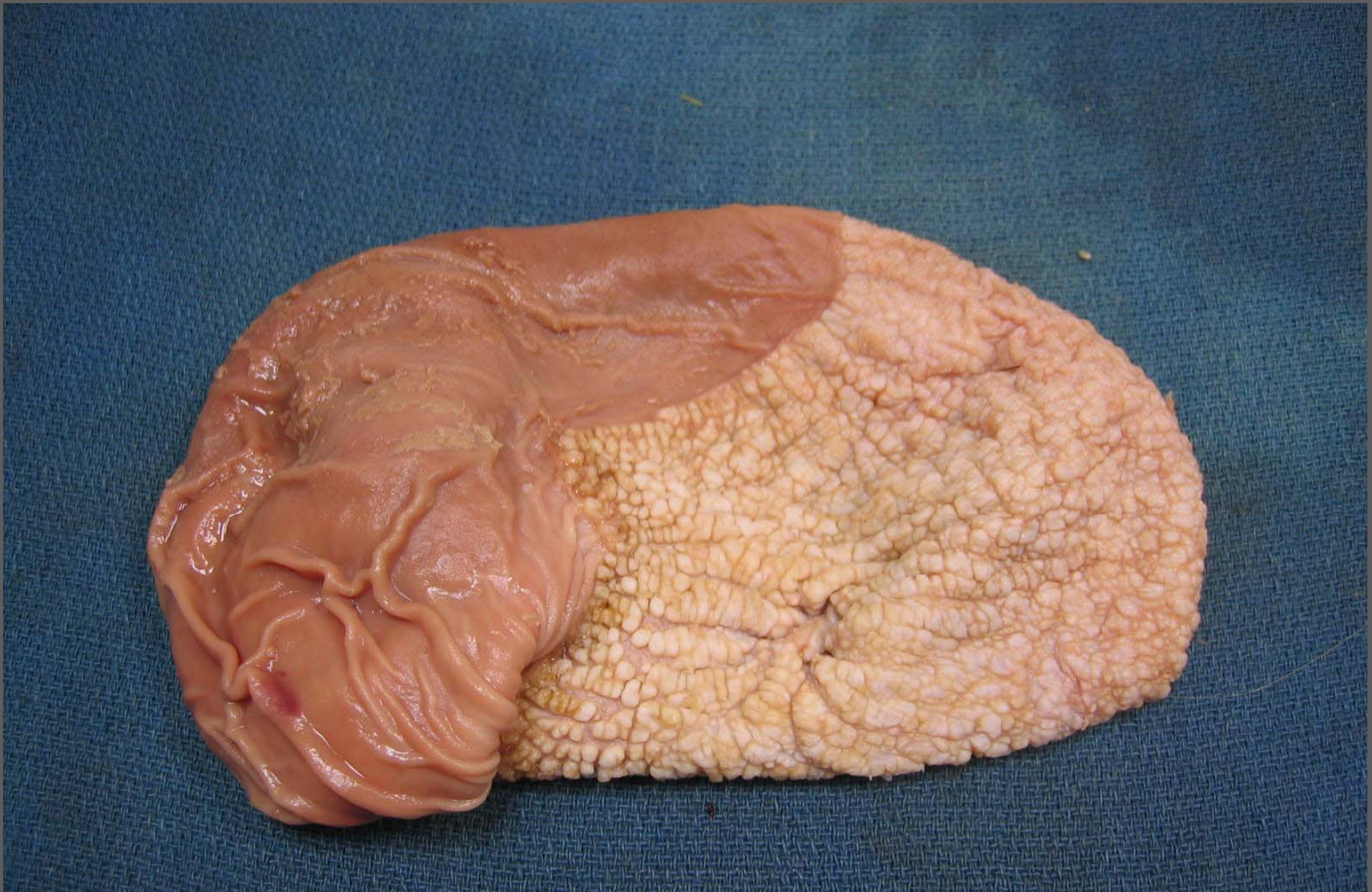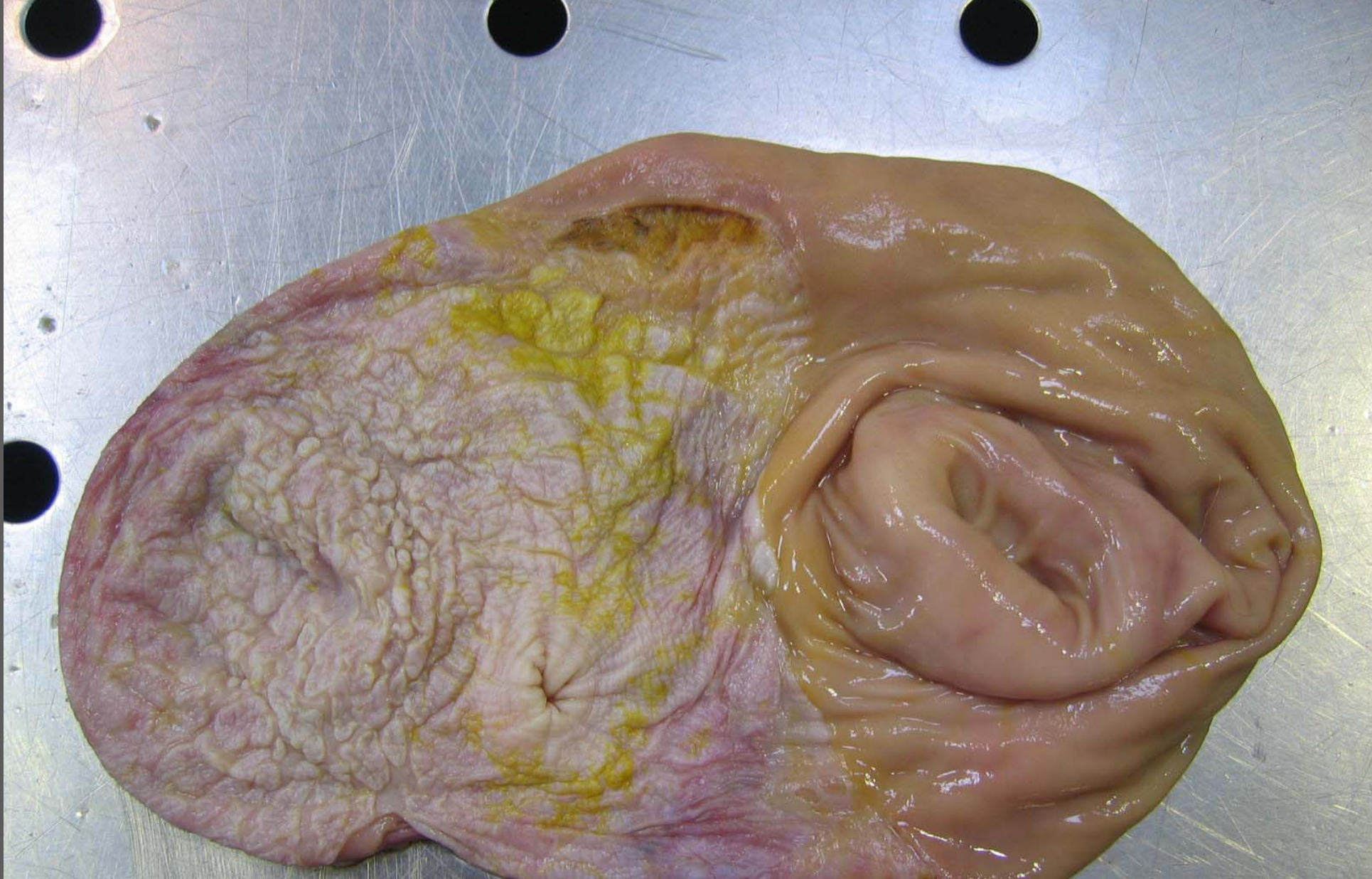


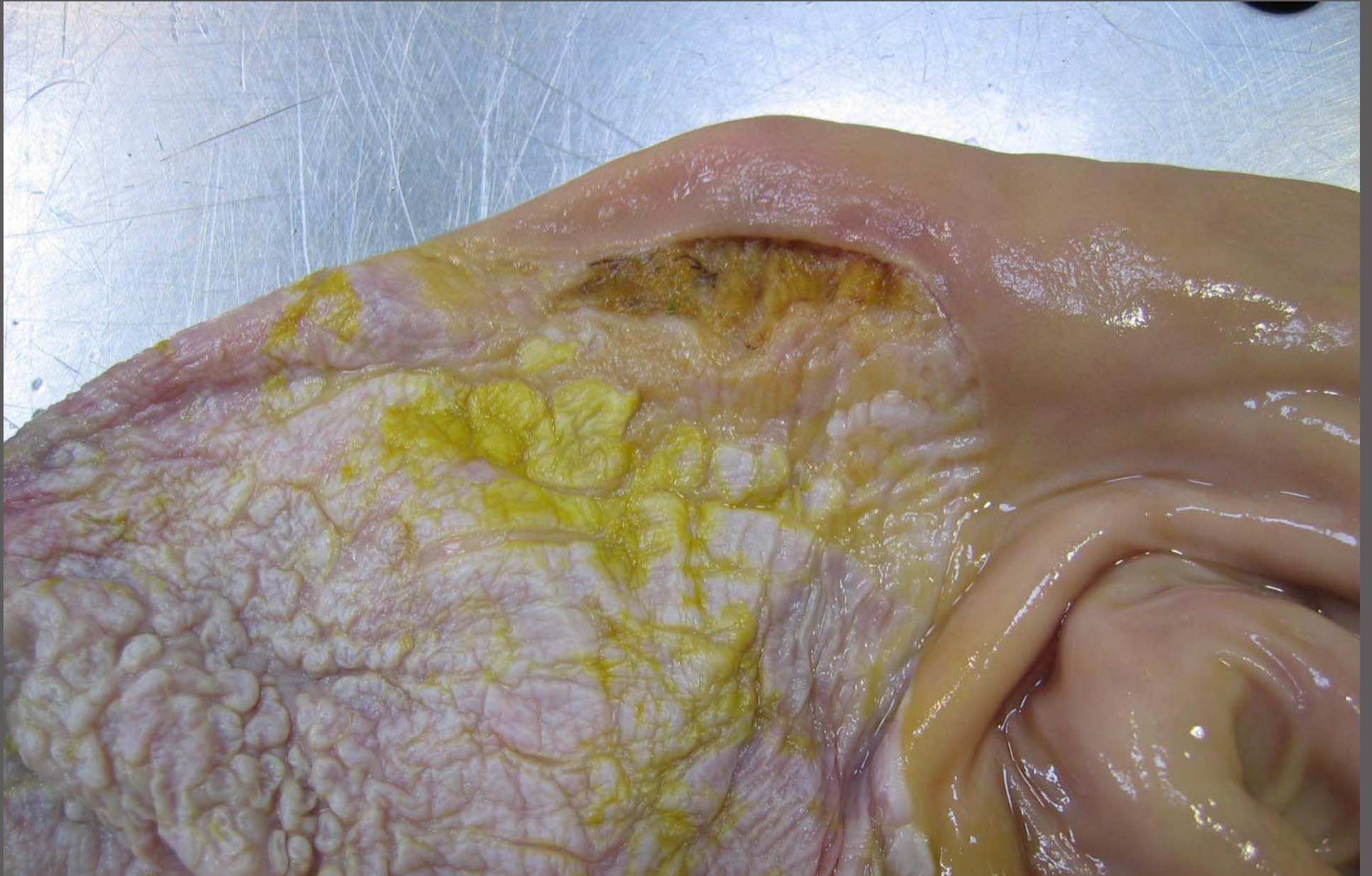Esophagus – megaesophagus secondary to autonomic system dysplasia



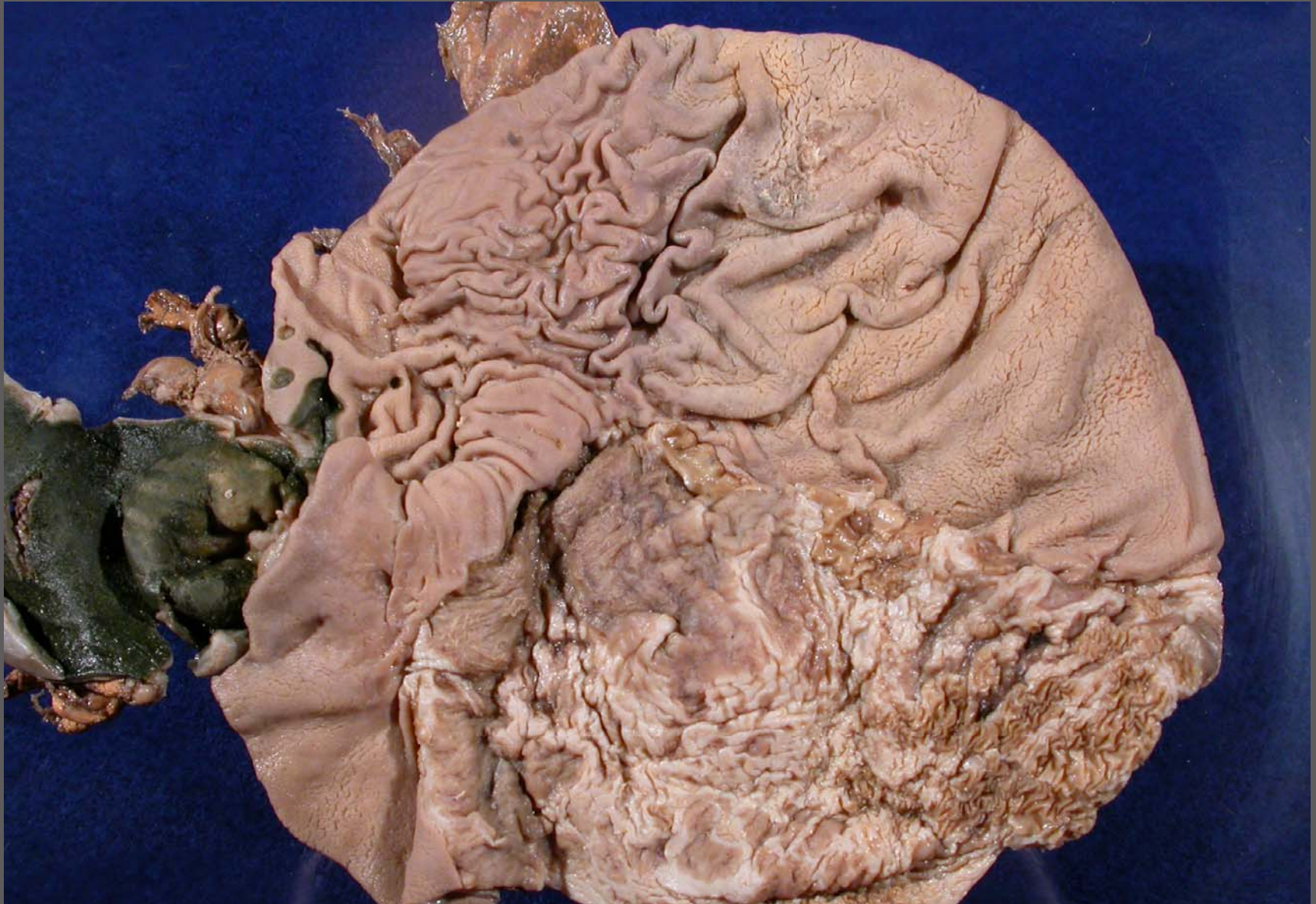Foal – stomach – erosions, ulcers and cobblestone hyperkeratosis



Foal – stomach – erosions, ulcers, cobblestone hyperkeratosis and perforation



Foal – stomach – erosions, ulcers, cobblestone hyperkeratosis and perforation



Foal – stomach, duodenum – erosions, ulcers with duodenal ulceration and perforation