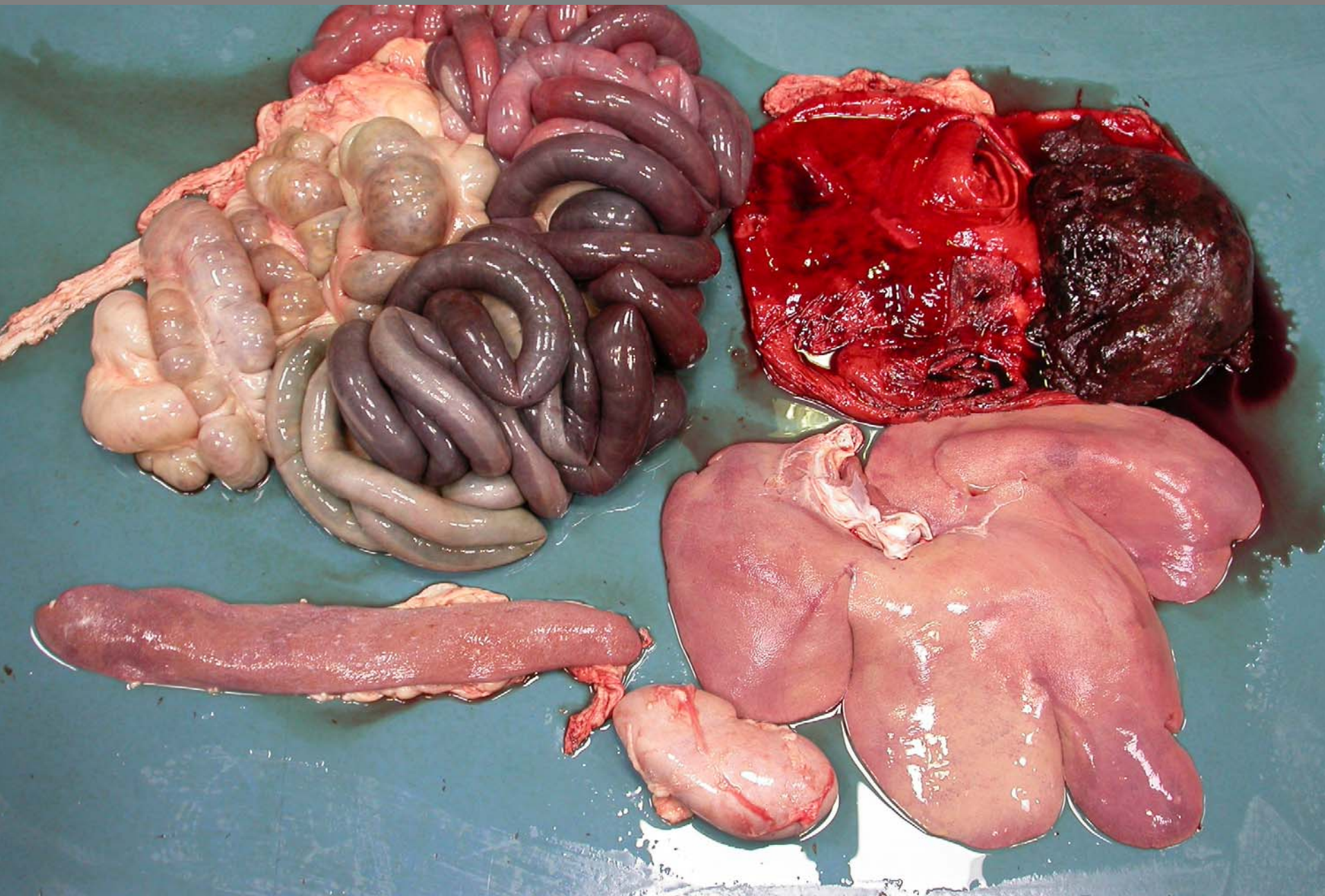
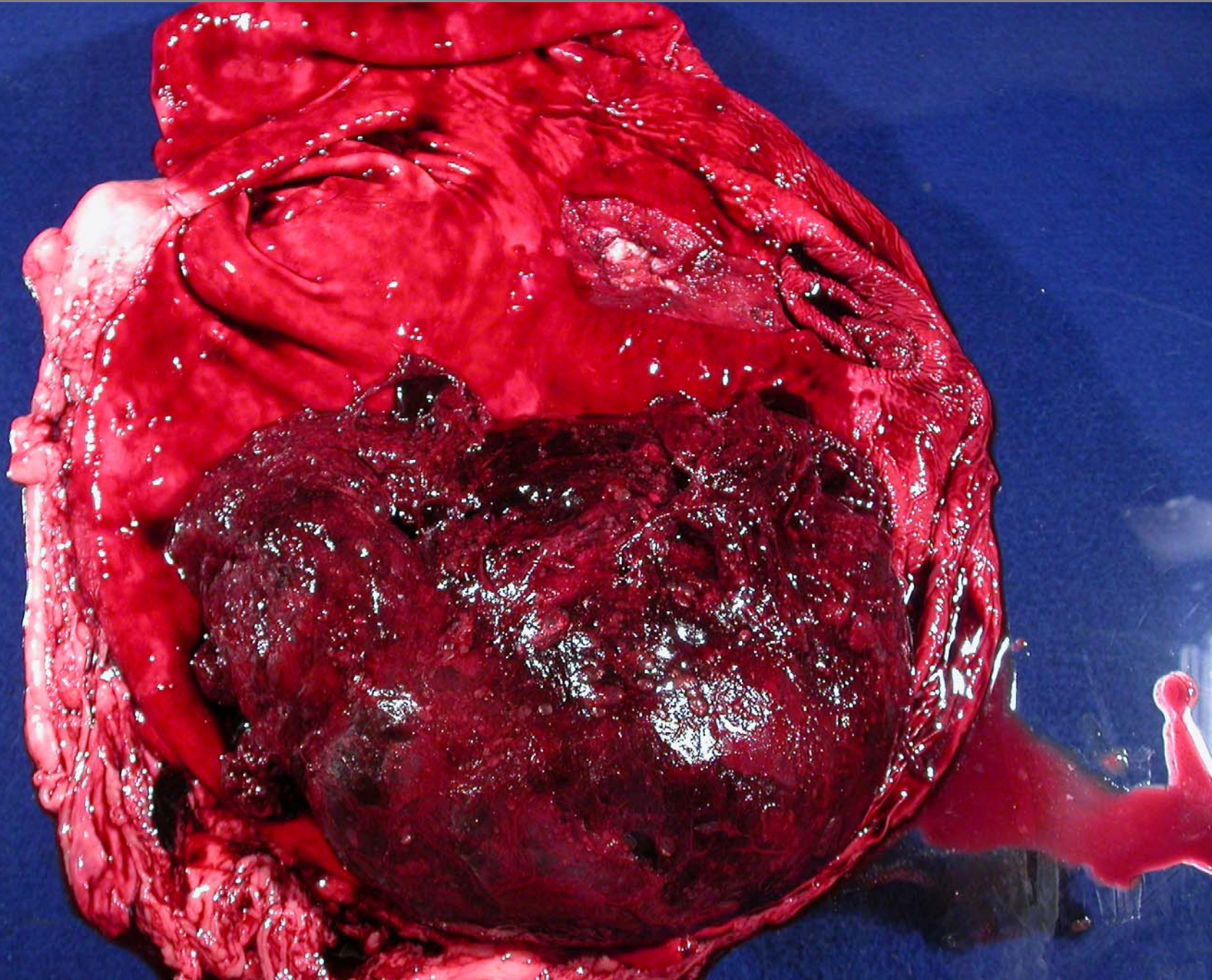


Stomach – gastroesophageal ulcer – exsanguination  
and anemic pallor



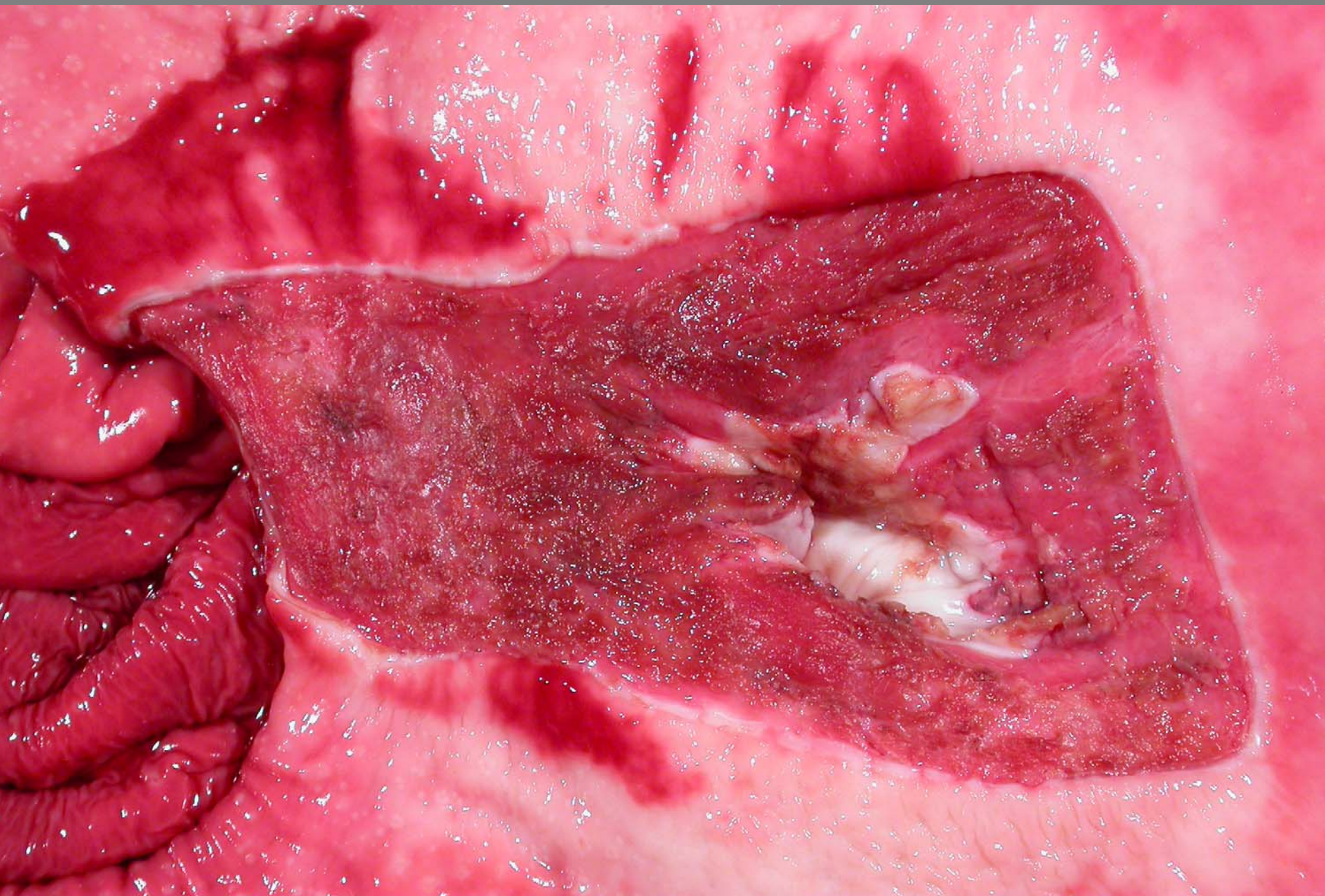

Stomach – gastroesophageal ulcer – exsanguination – intragastric blood clot

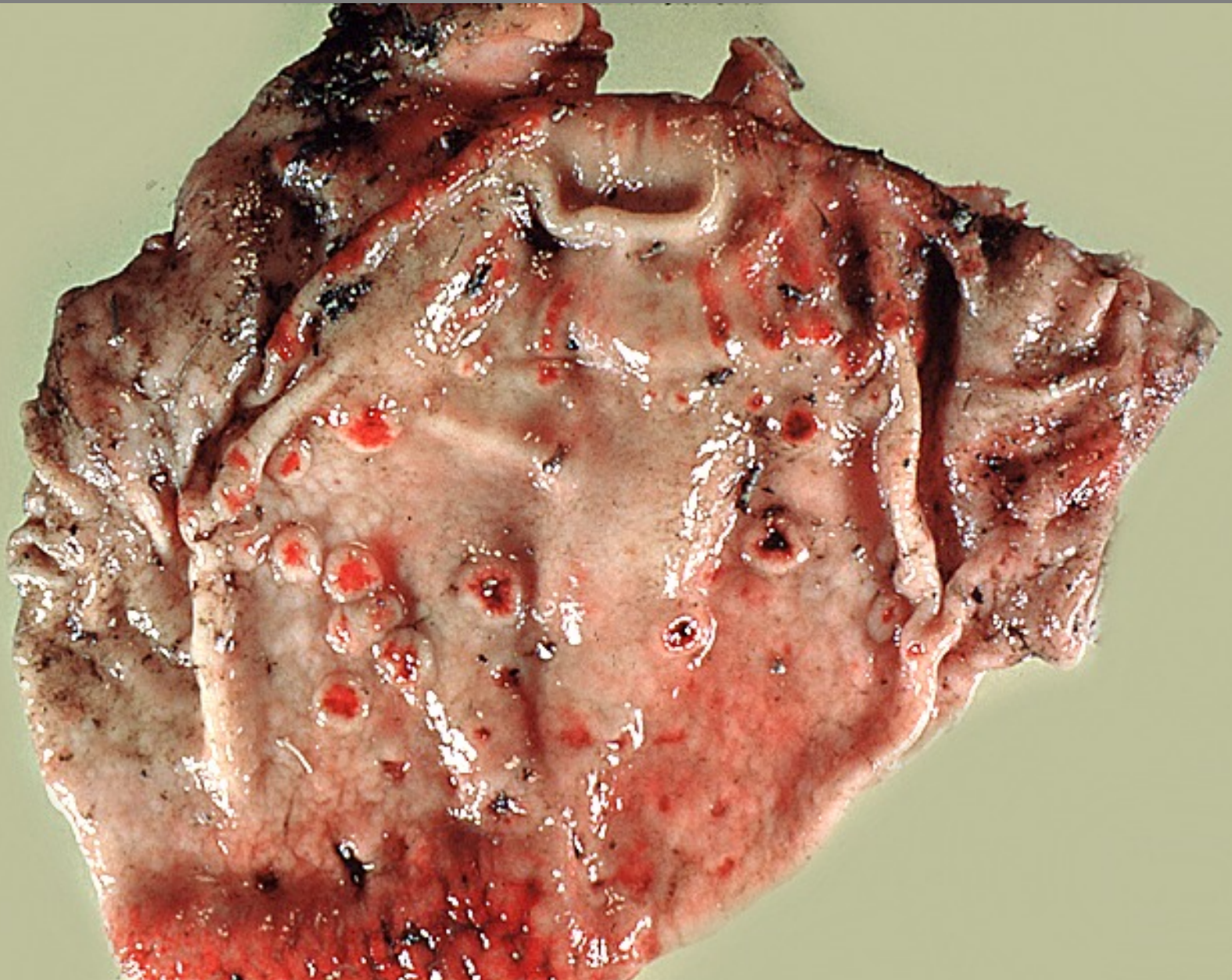




Stomach – gastroesophageal ulcer – exsanguination  
and anemic pallor

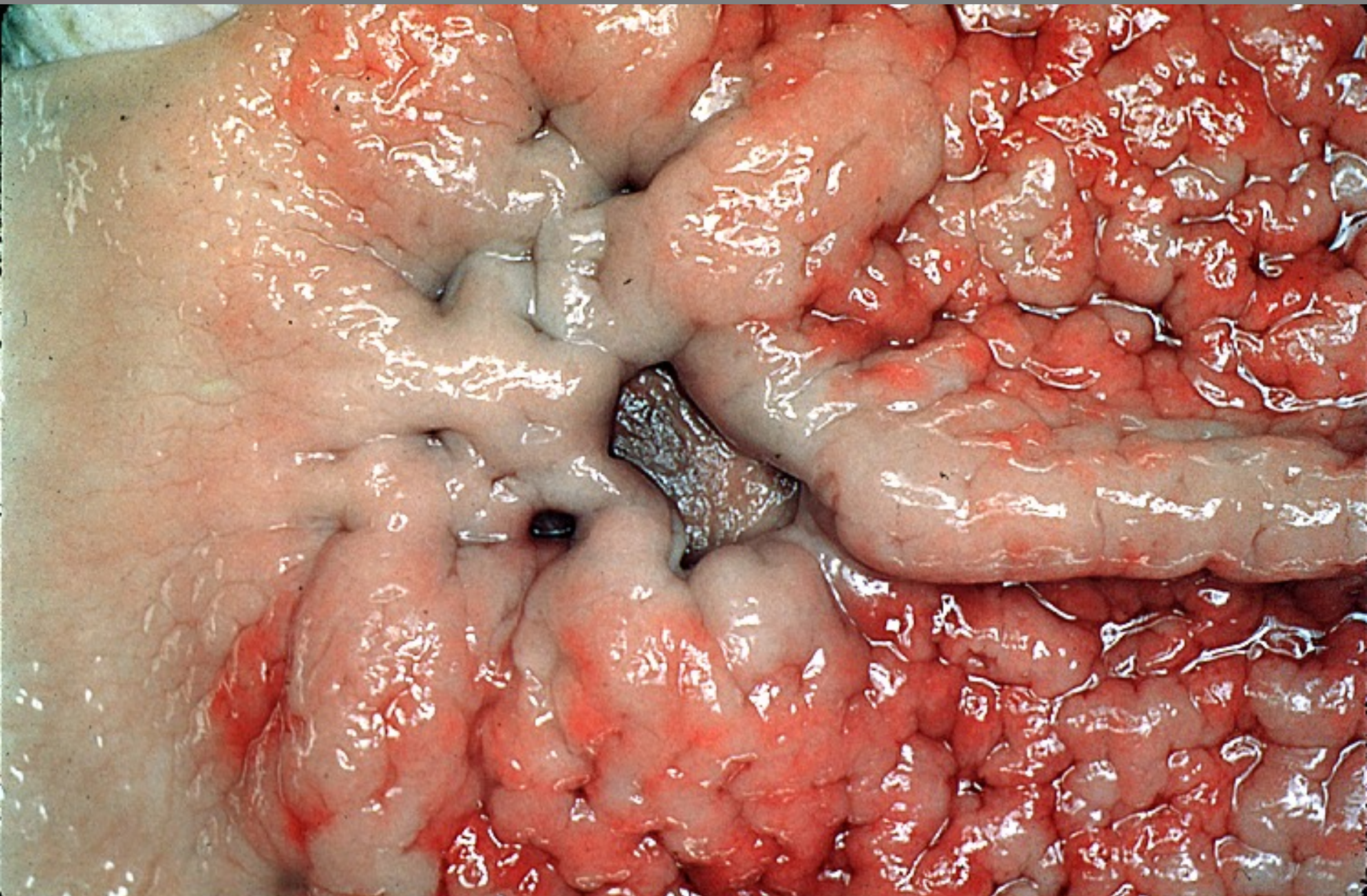






Stomach – ulcerative gastritis – *Hyostrogylus rubidus*





Stomach – ulcerative gastritis – *Hyostromylus rubidus*