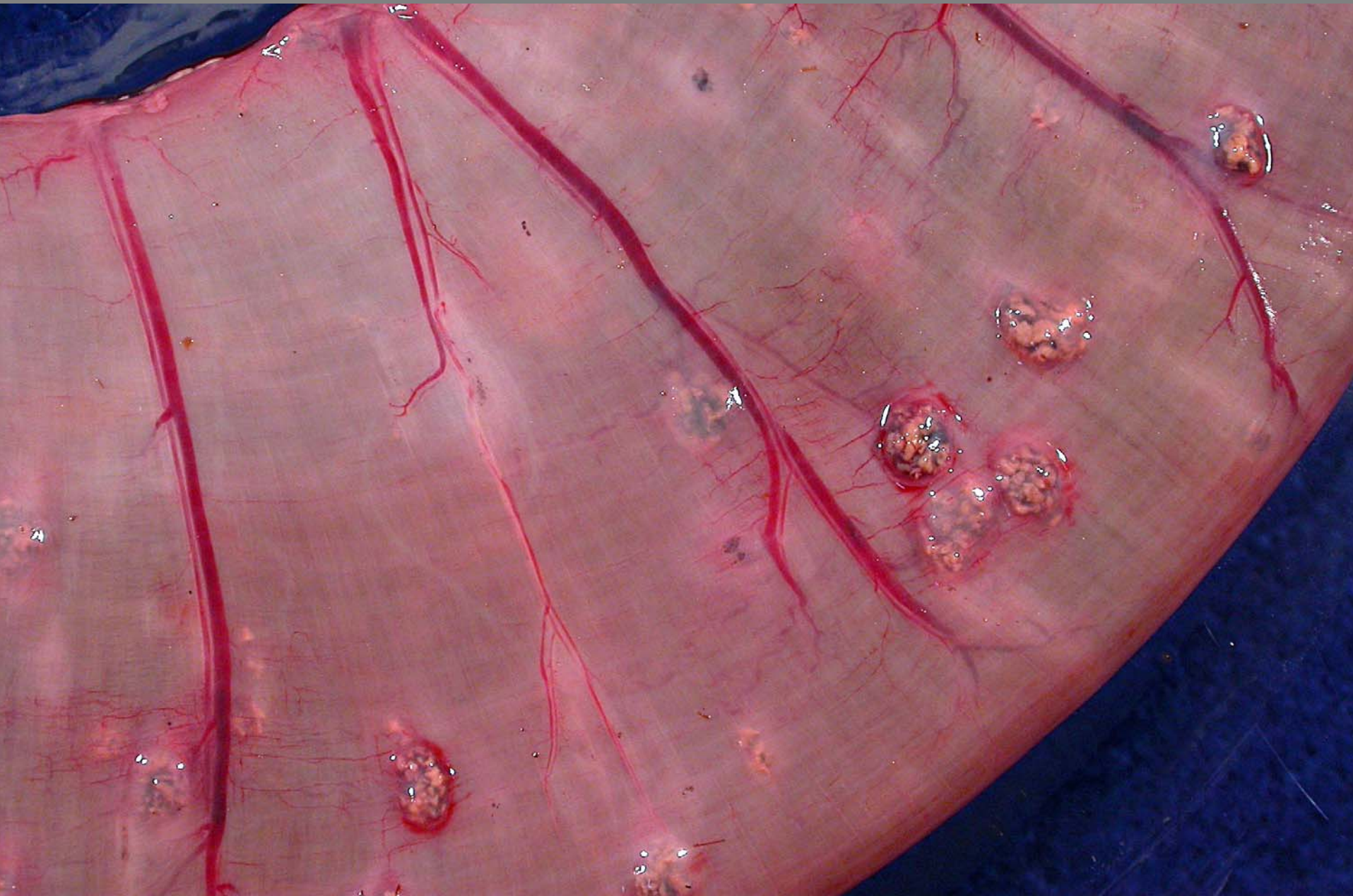
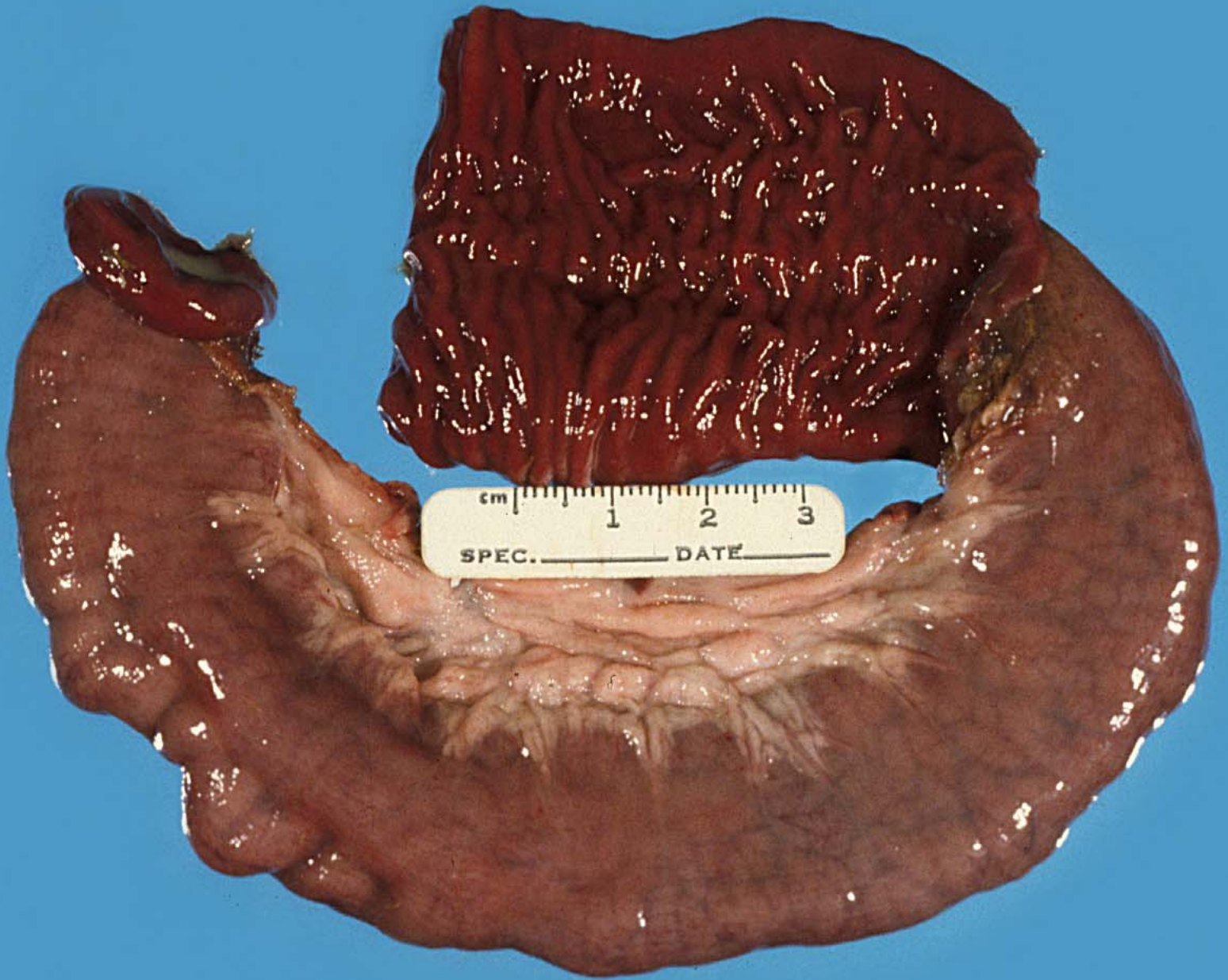
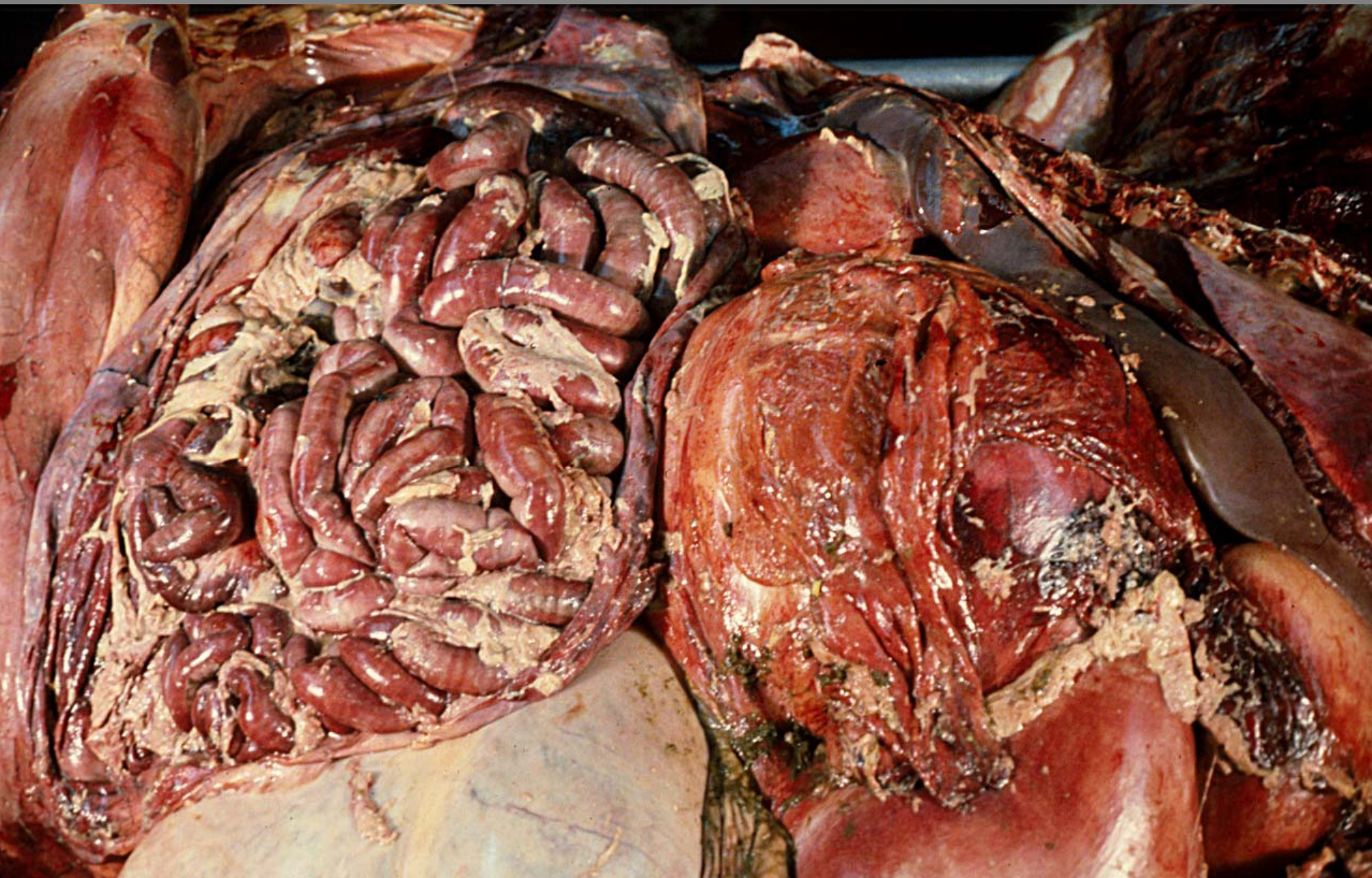
Small intestine – serosa – *Oesophagostomum* spp.  
granulomata

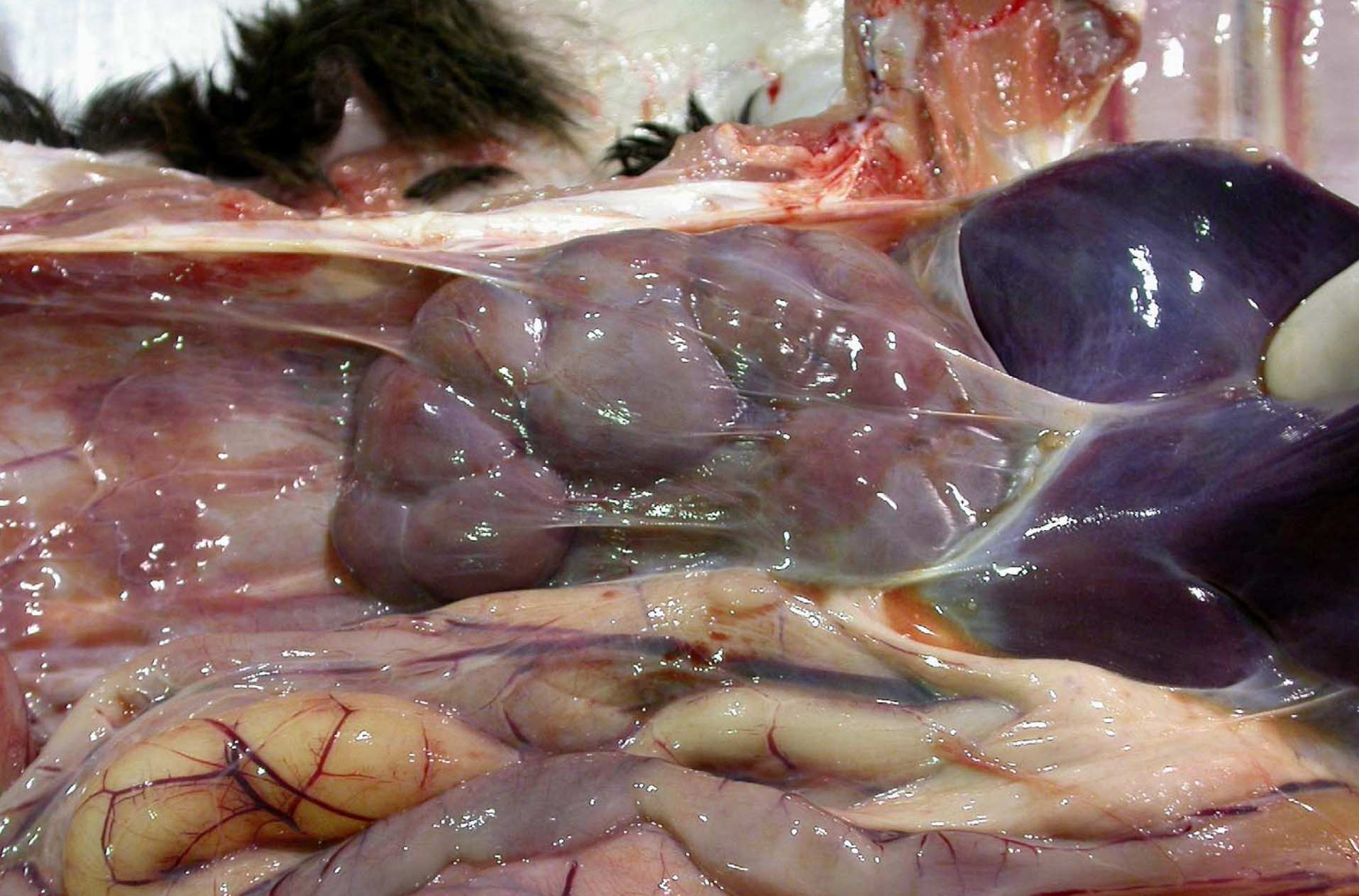




Calf – jejunum – alimentary lymphoma



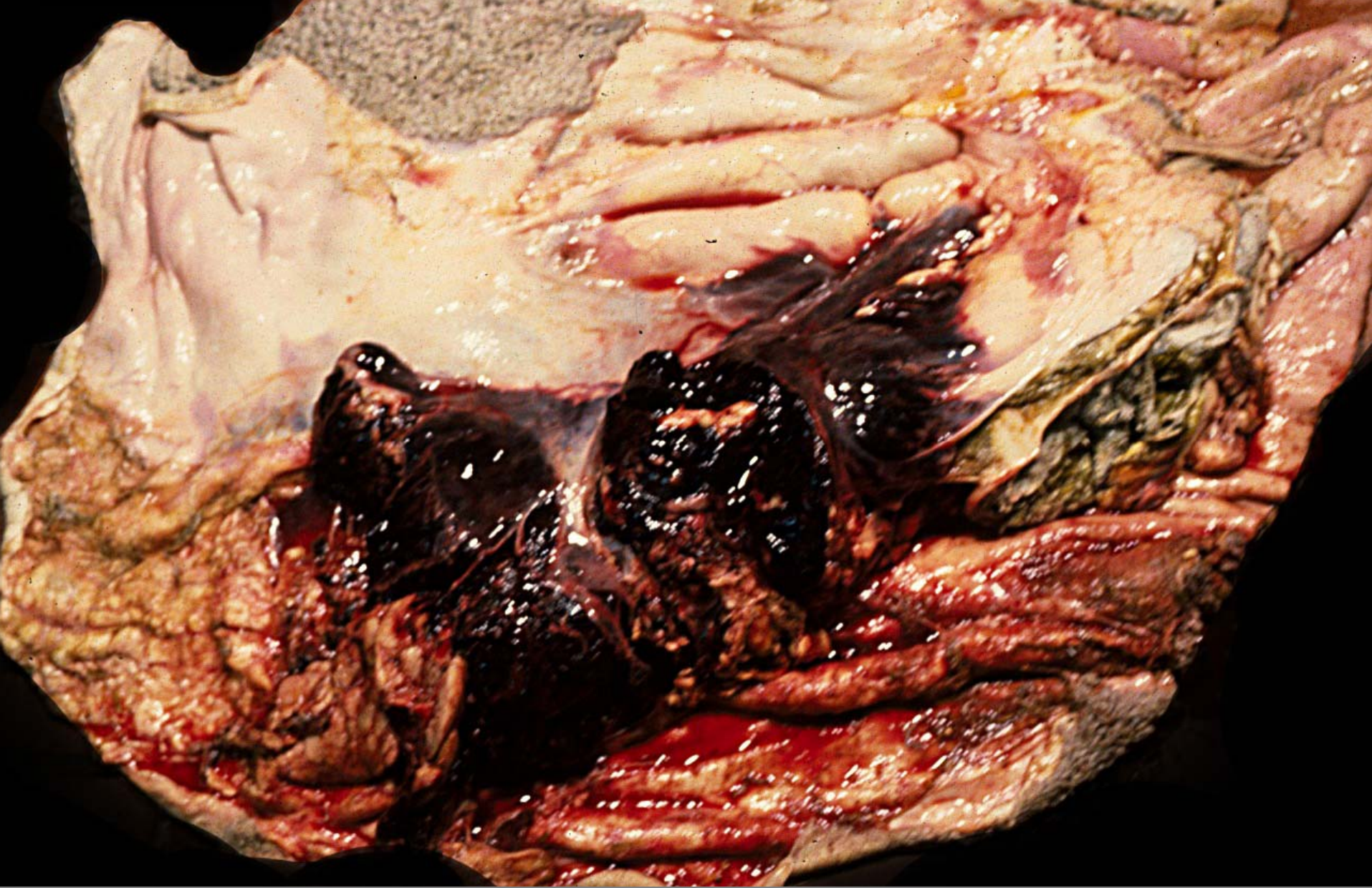
**Fibrinous septic peritonitis**



**Calf – serous atrophy of fat, liver atrophy – winter hypocaloric emaciation**



**Cecum- adenocarcinoma**



**Ruminal arterial wall degeneration with thinning, elastic fibers loss, fibrosis and rupture**