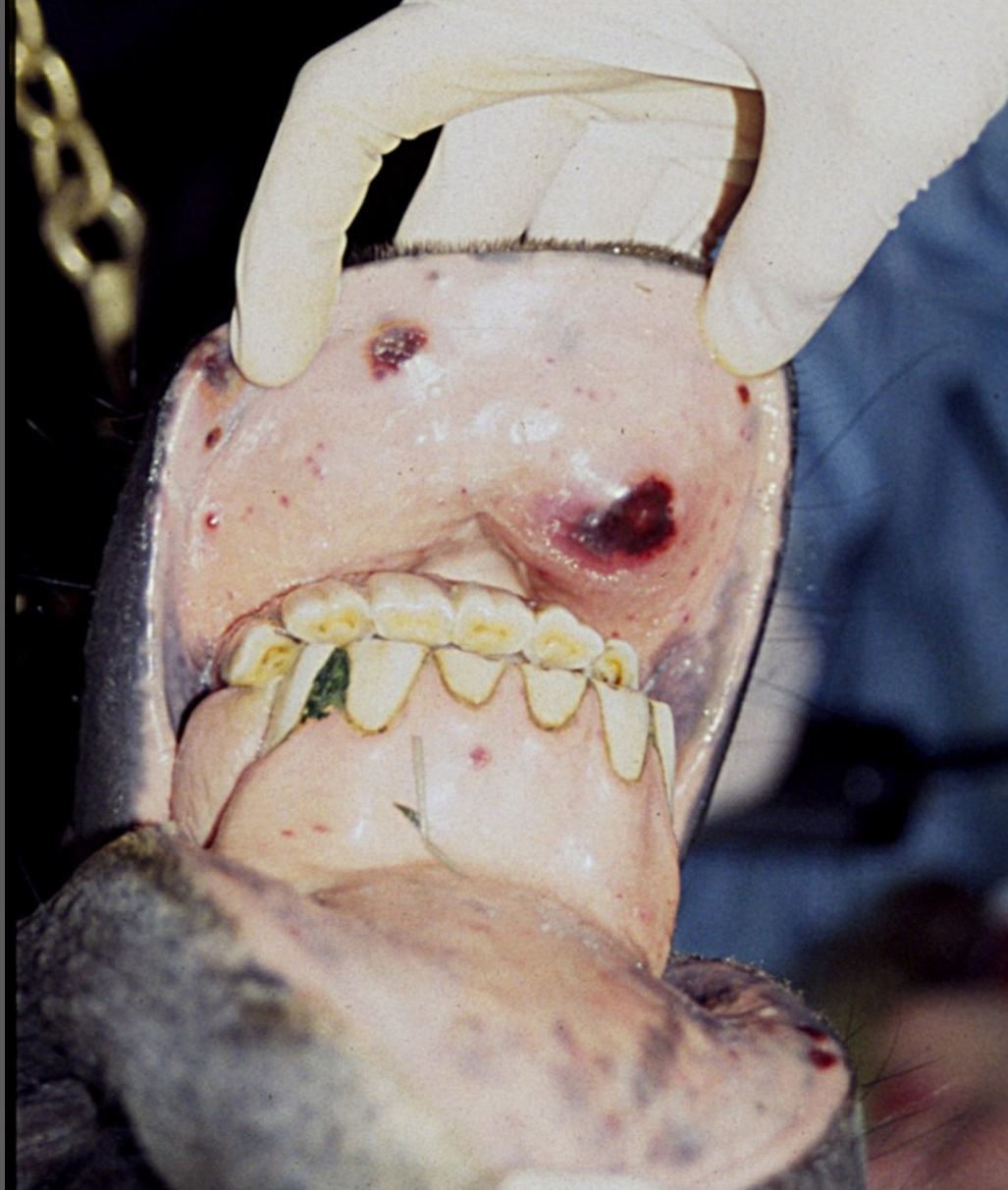
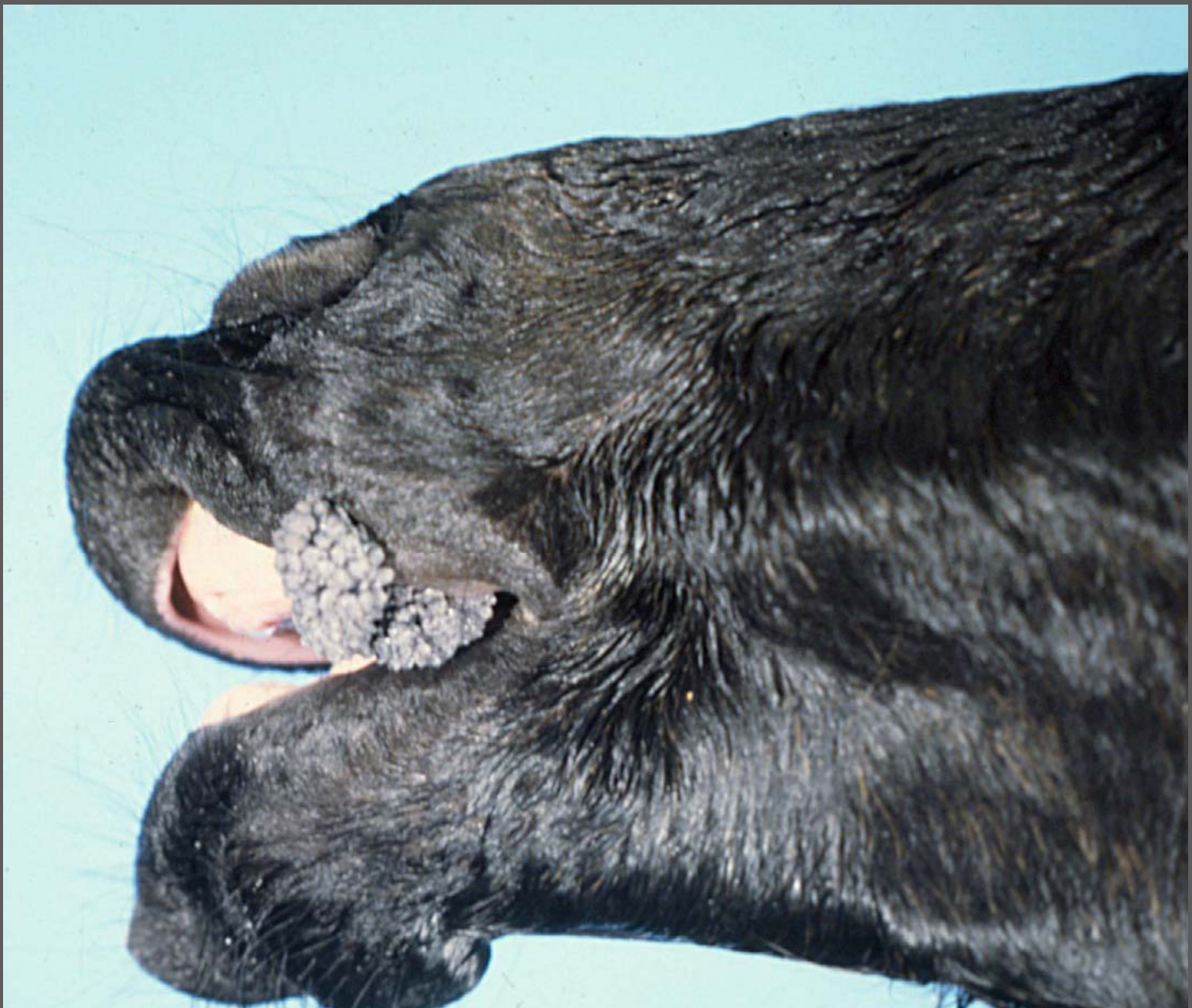
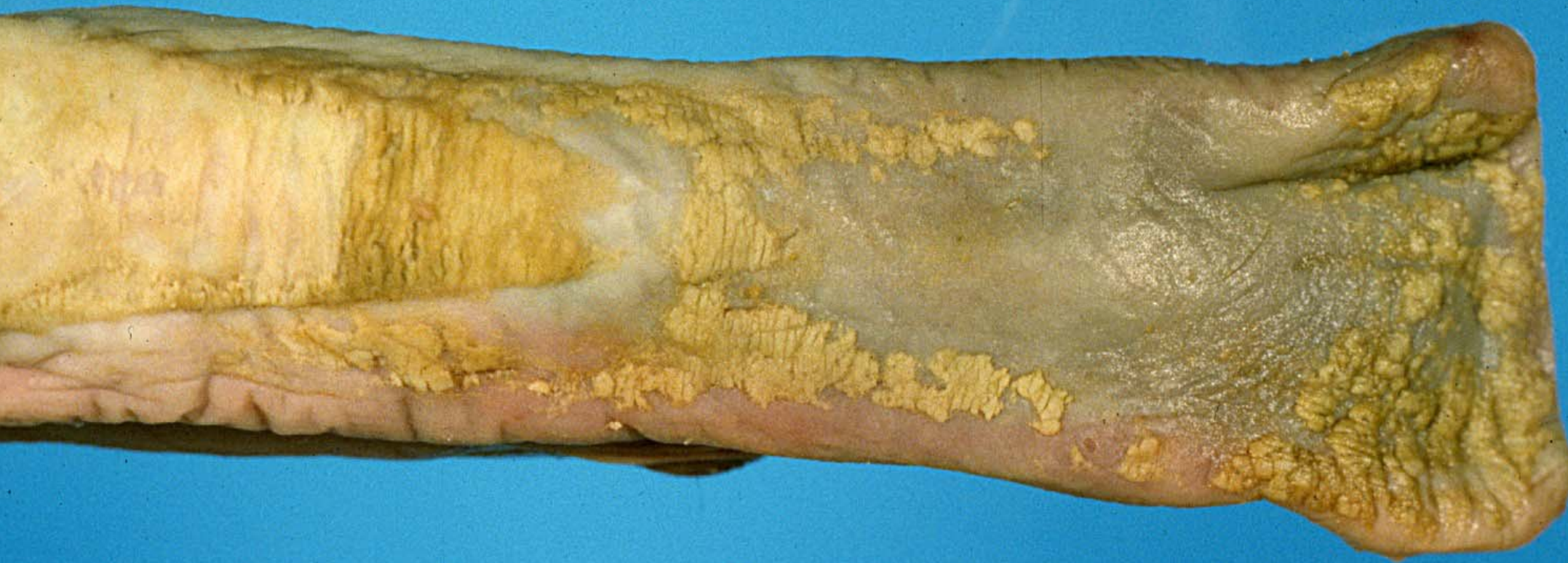

Oral cavity – hemorrhagic necrosis – purpura hemorrhagica –
DD: EVA



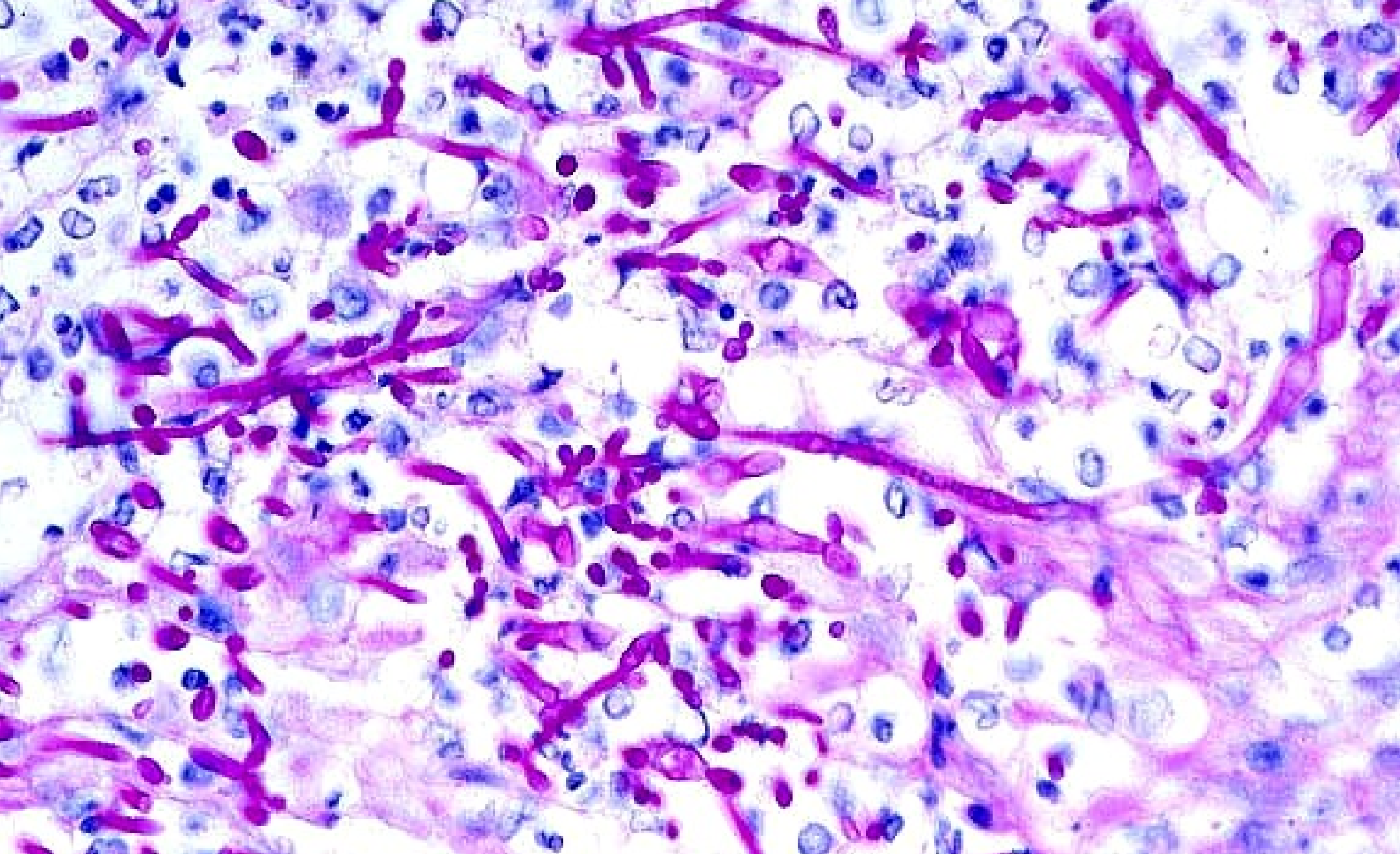
Fetus – labial papillomata



Tongue – parakeratosis – opportunistic *Candida* spp.



Esophagus – parakeratosis – opportunistic *Candida* spp.
in foal with systemic salmonellosis



Candida spp. - AFIP