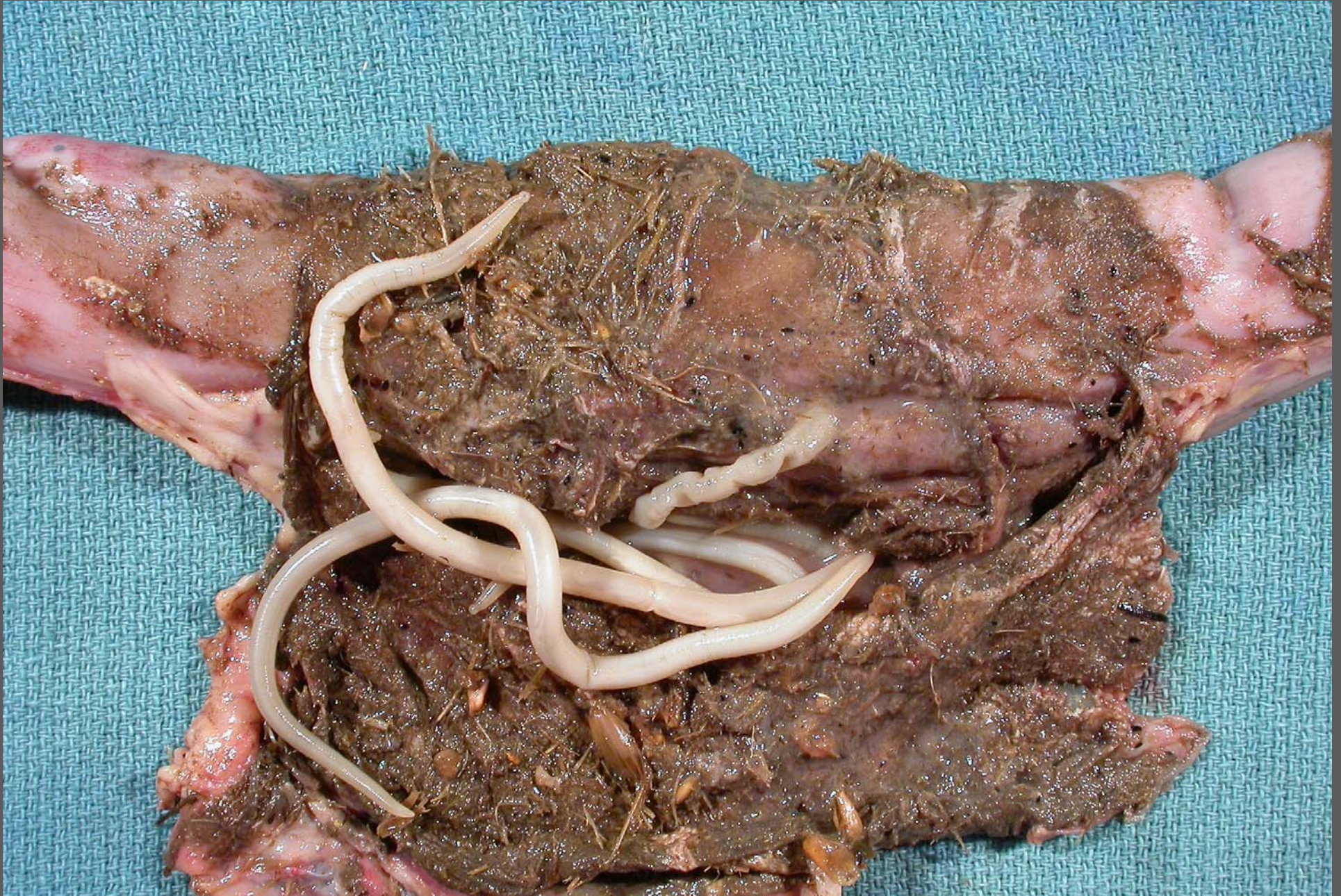
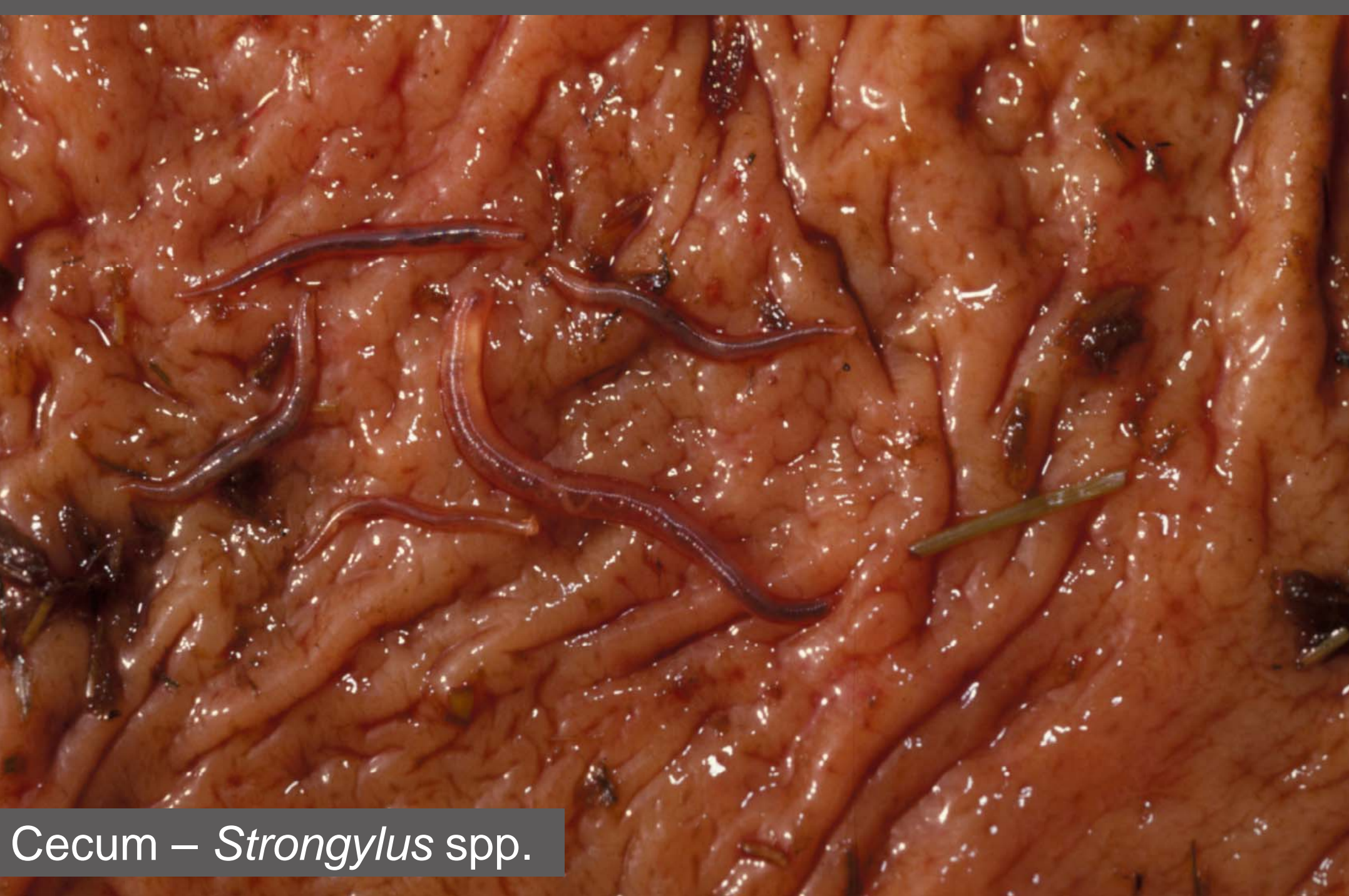
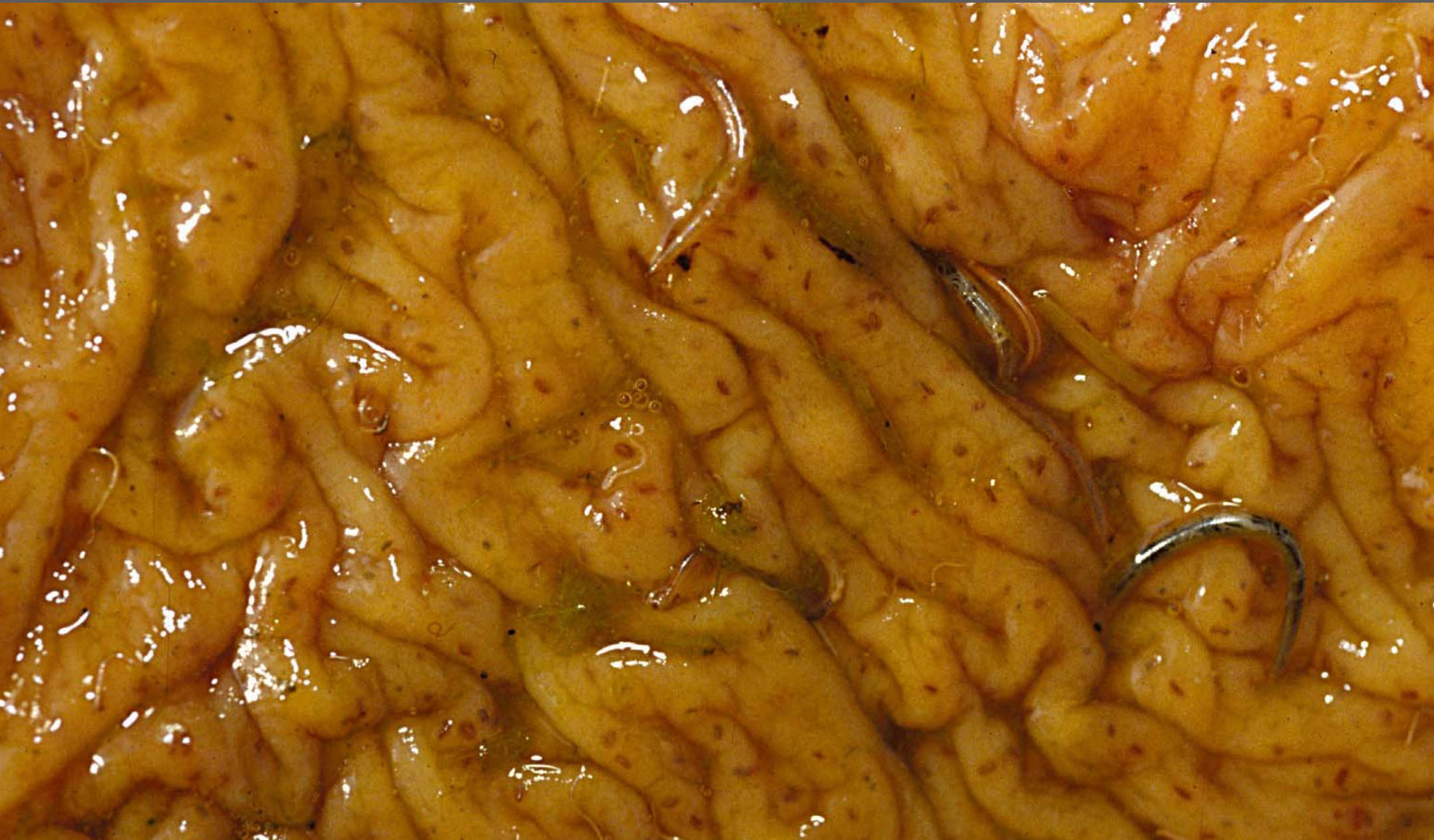Foal – small intestine impaction with ascarids (*Parascaris equorum*)





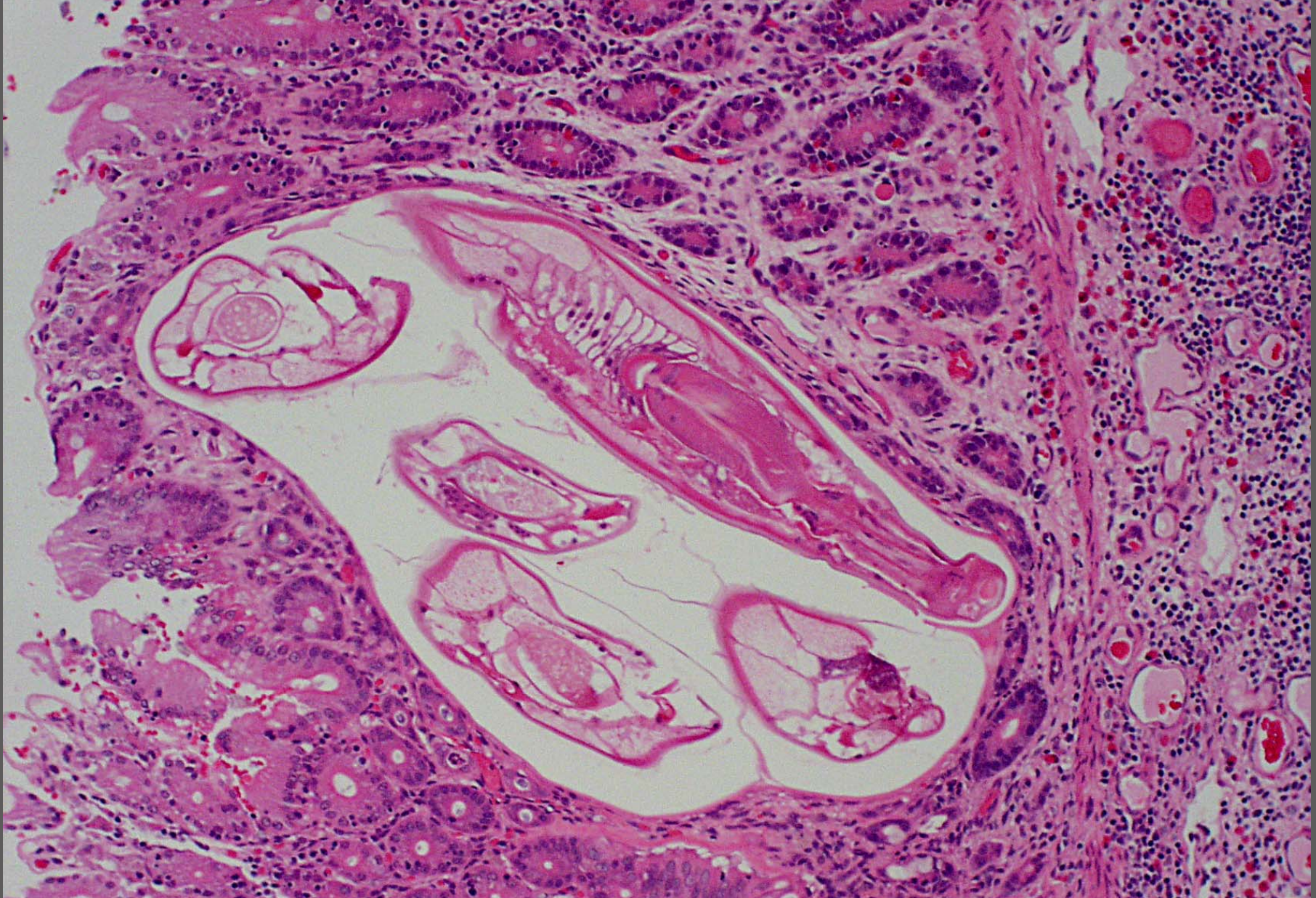
Cecum – *Strongylus* spp.





Large intestine – *Strongylus* spp. adults and *Cyathostomidae* adults and encysted larvae





Large intestine – *Cyathostomidae* encysted larva and moderate chronic enteritis with eosinophils





Ileocecal valve – Severe cestodiasis (*Anoplocephala perfoliata*) with severe edema and ulcerative chronic typhlitis