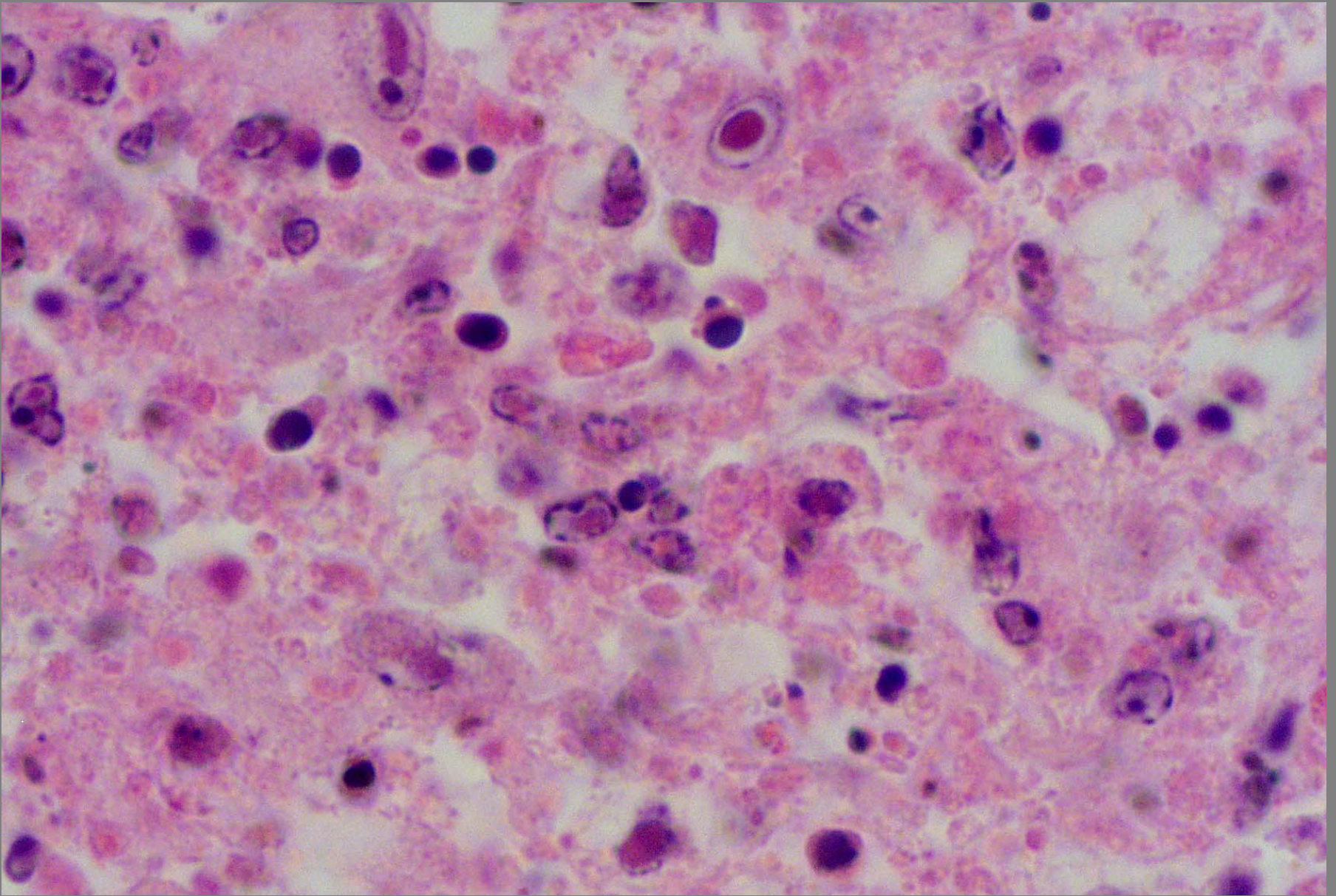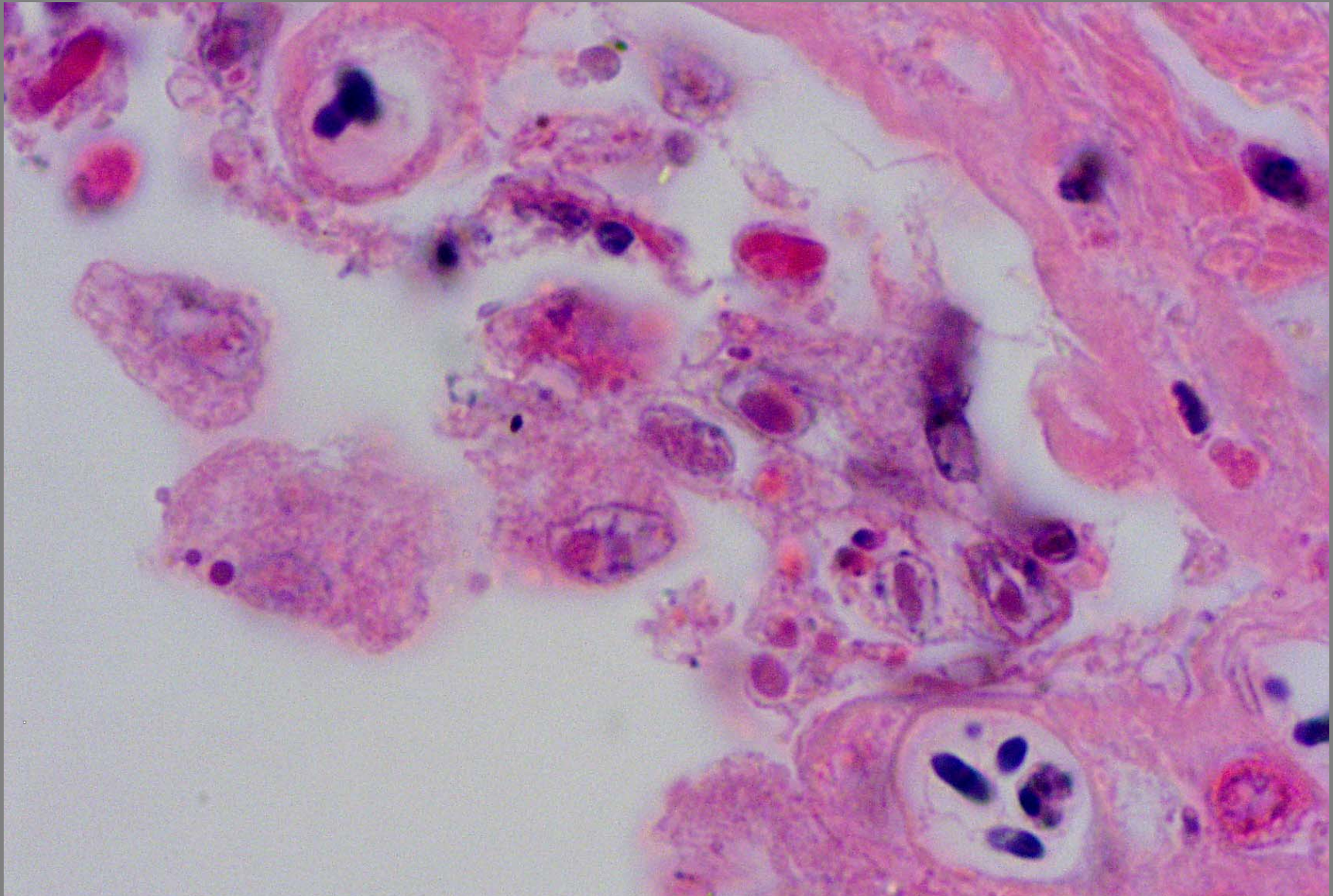


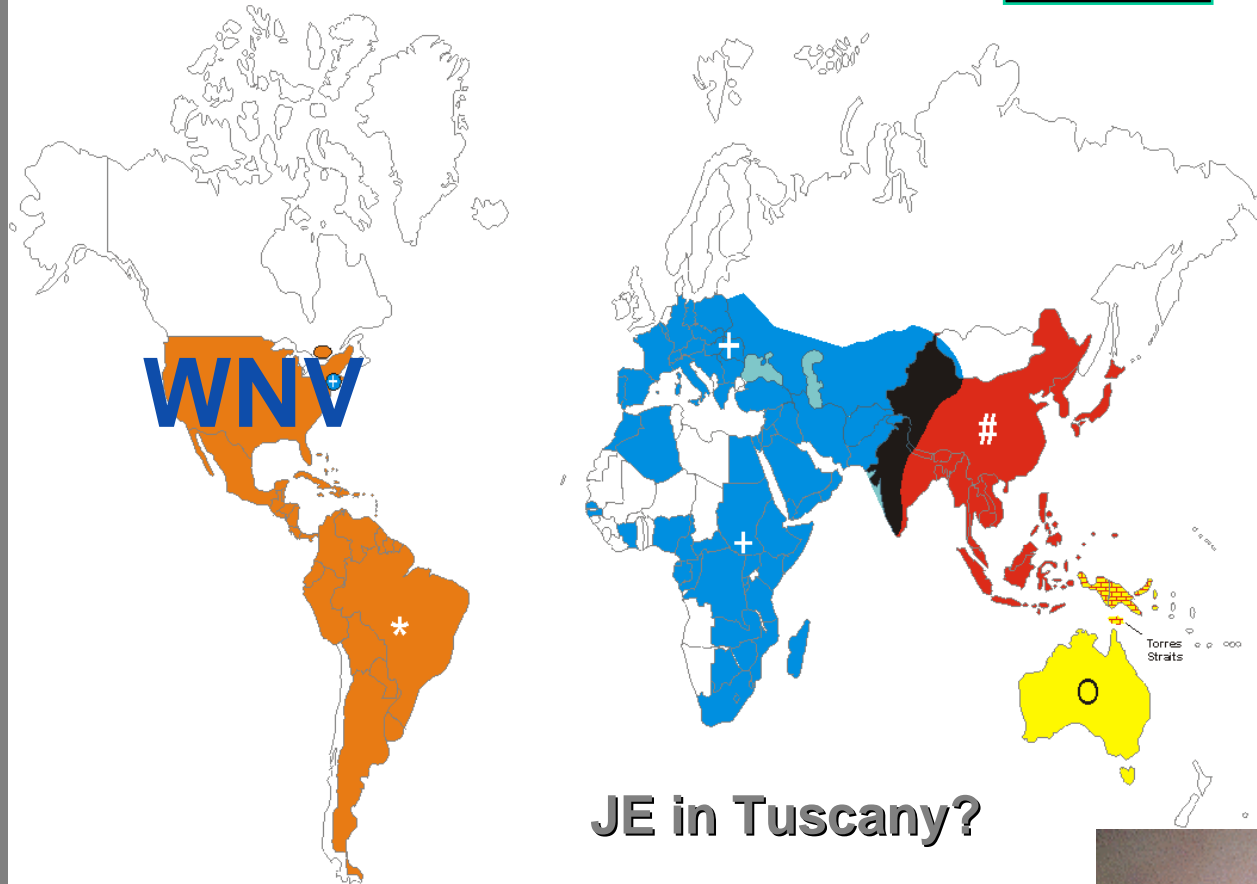
Intestinal lymphoid necrosis – I.B. - duck plague herpes virus



Intestinal lymphoid necrosis – I.B. - duck plague herpes virus

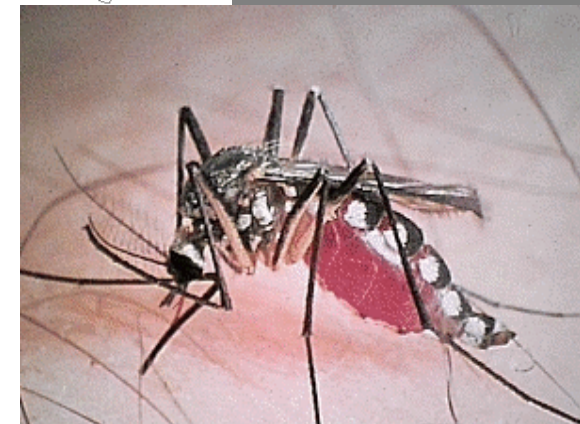The Geographic Distribution of the Japanese Encephalitis Serocomplex of the Family Flaviridae

2005

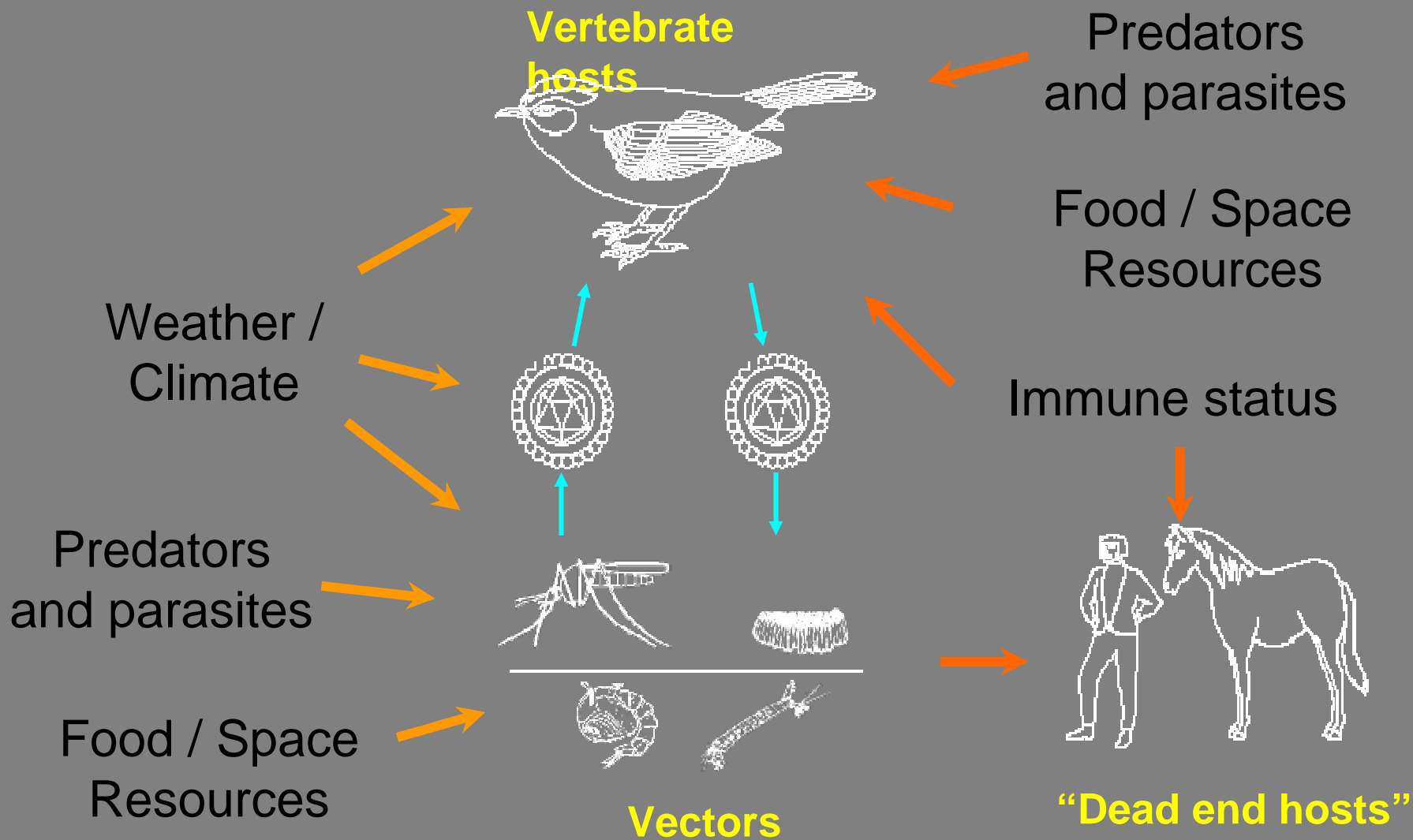


JE in Tuscany?

- St. Louis encephalitis
- * Rocio and St. Louis (Brazil)
- + West Nile virus
- # Japanese encephalitis
- West Nile and Japanese encephalitis
- Japanese and Murray Valley encephalitis
- Murray Valley and Kunjin



Components in the transmission and maintenance of arboviral encephalitis





Crow - Enteric necrosis with melena - WNV