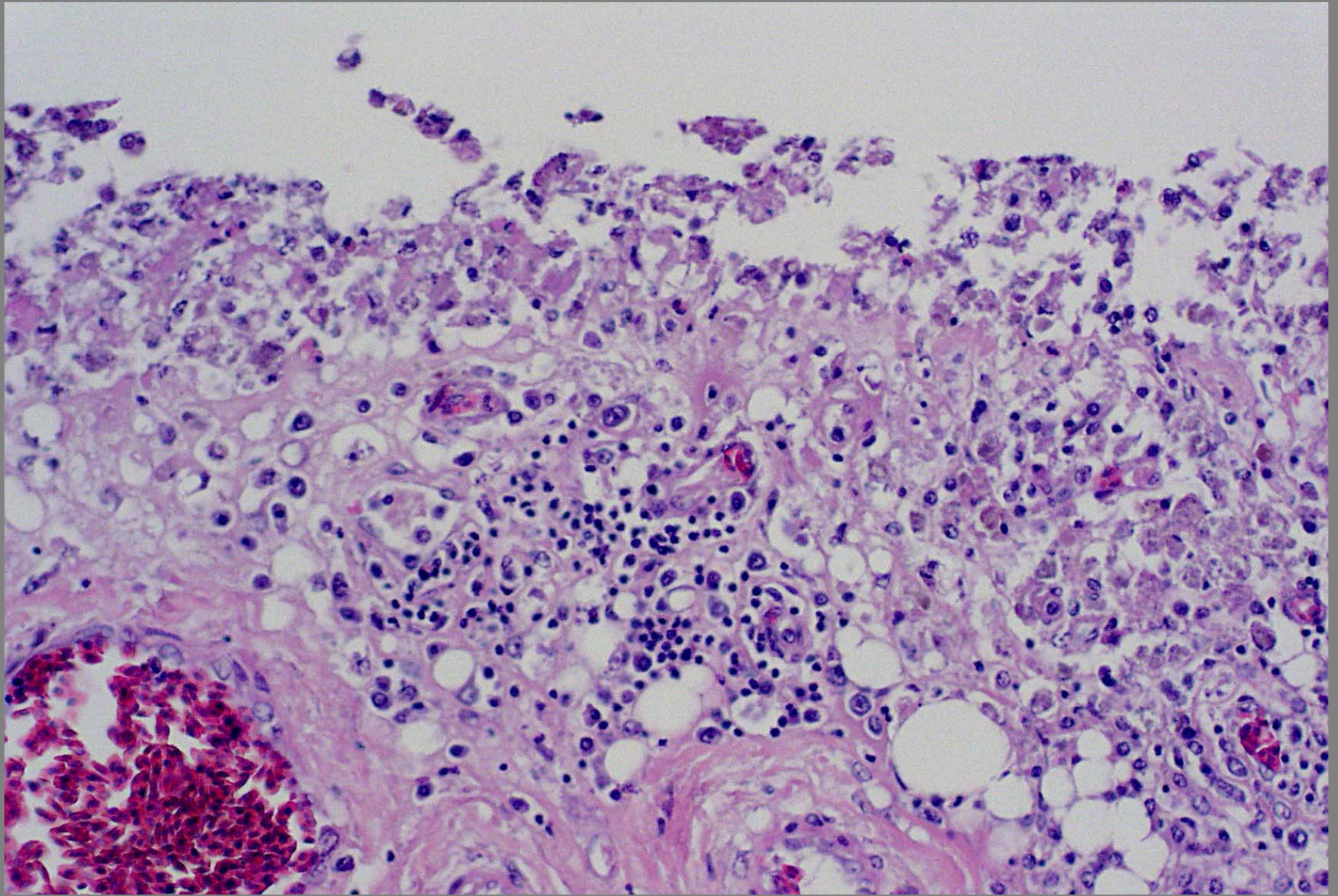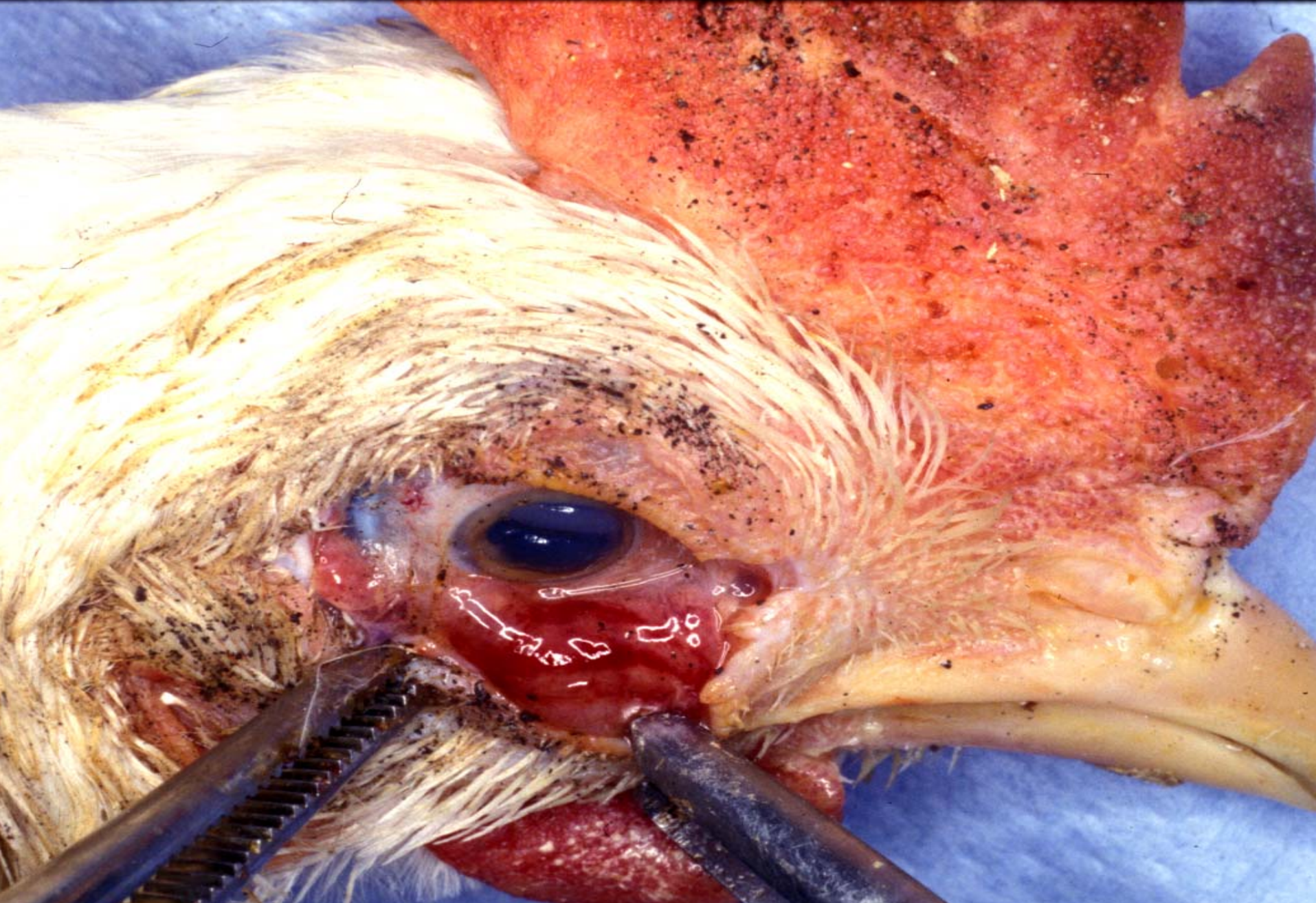

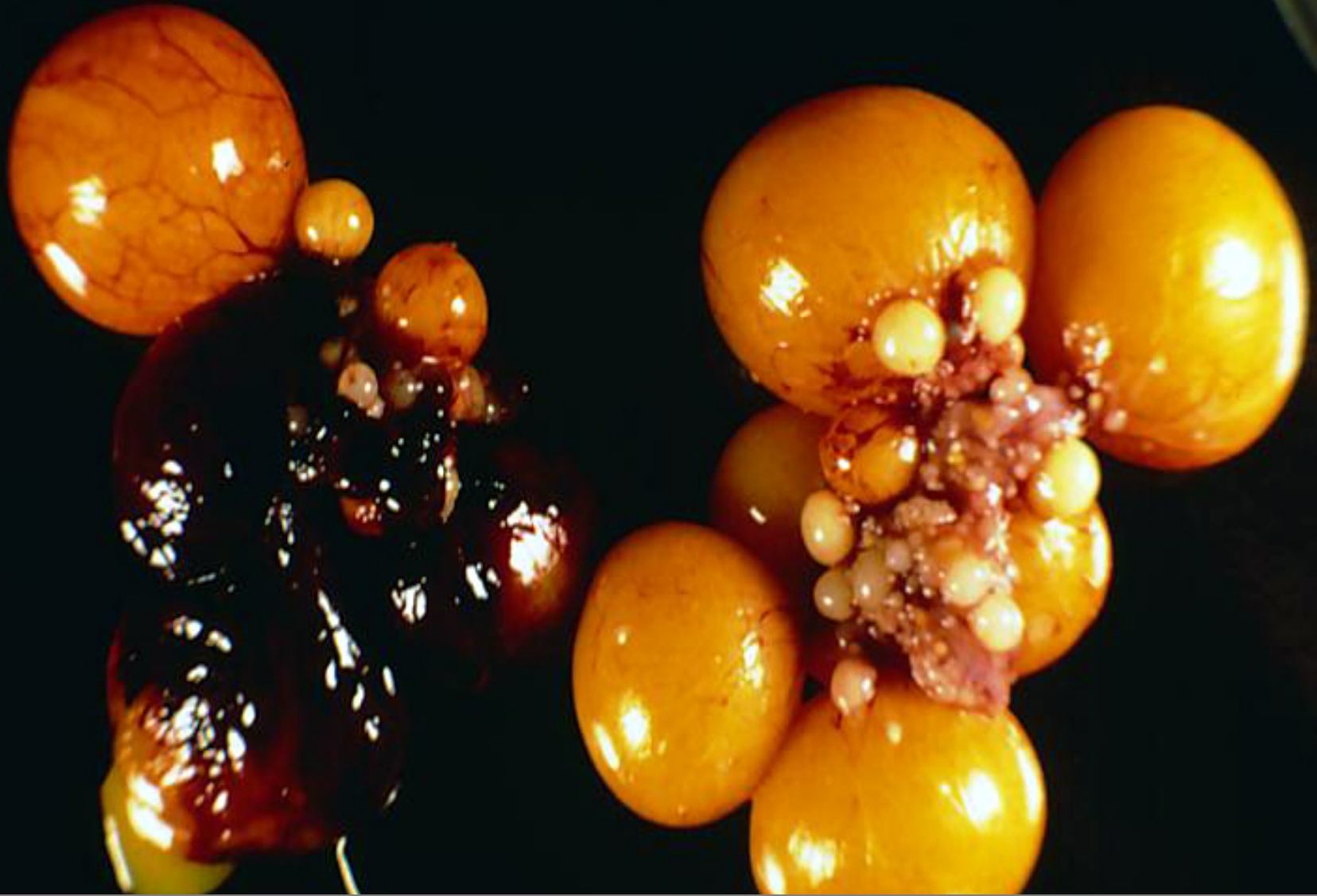
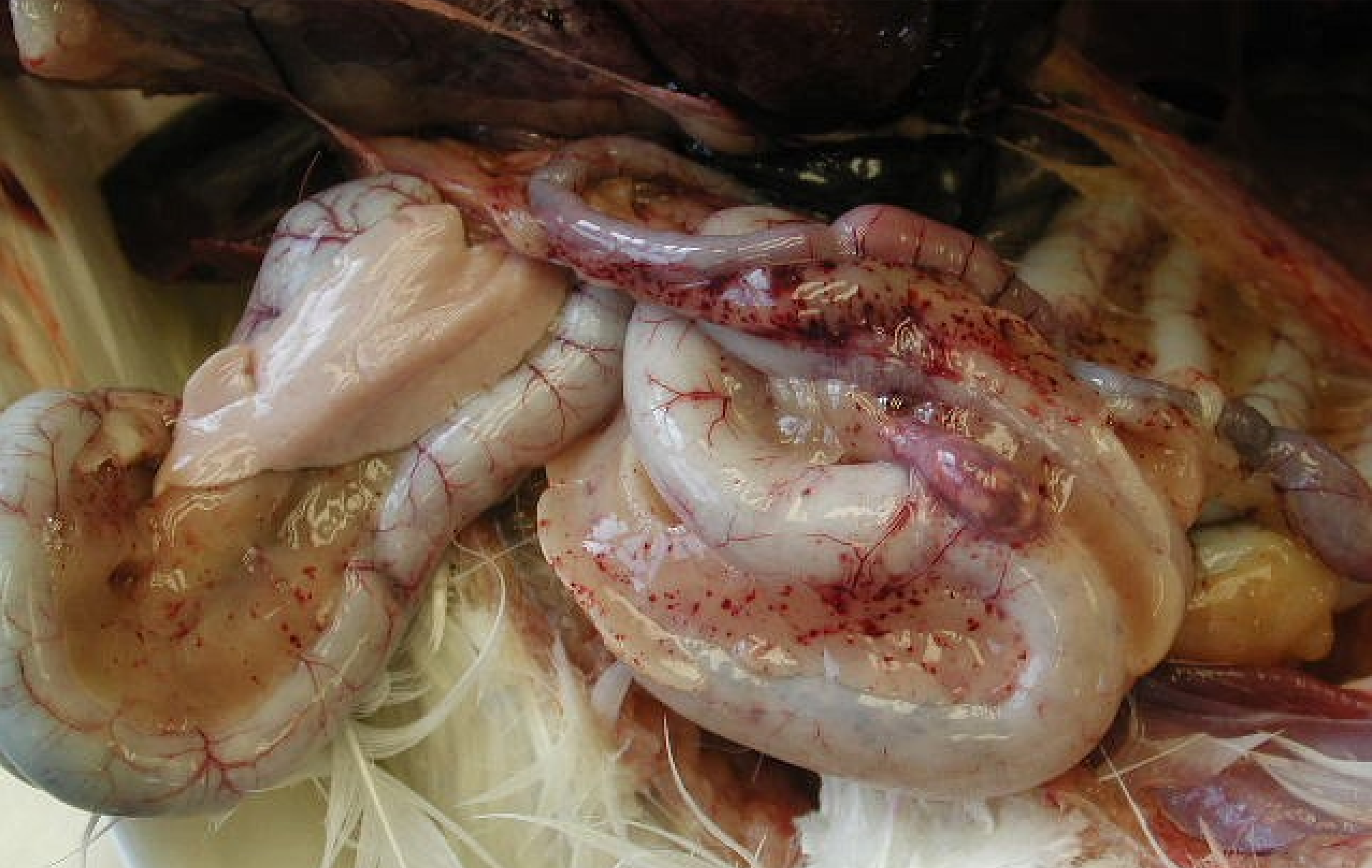Cecal tonsil necrosis – ND (from Plum Island glass slides set)



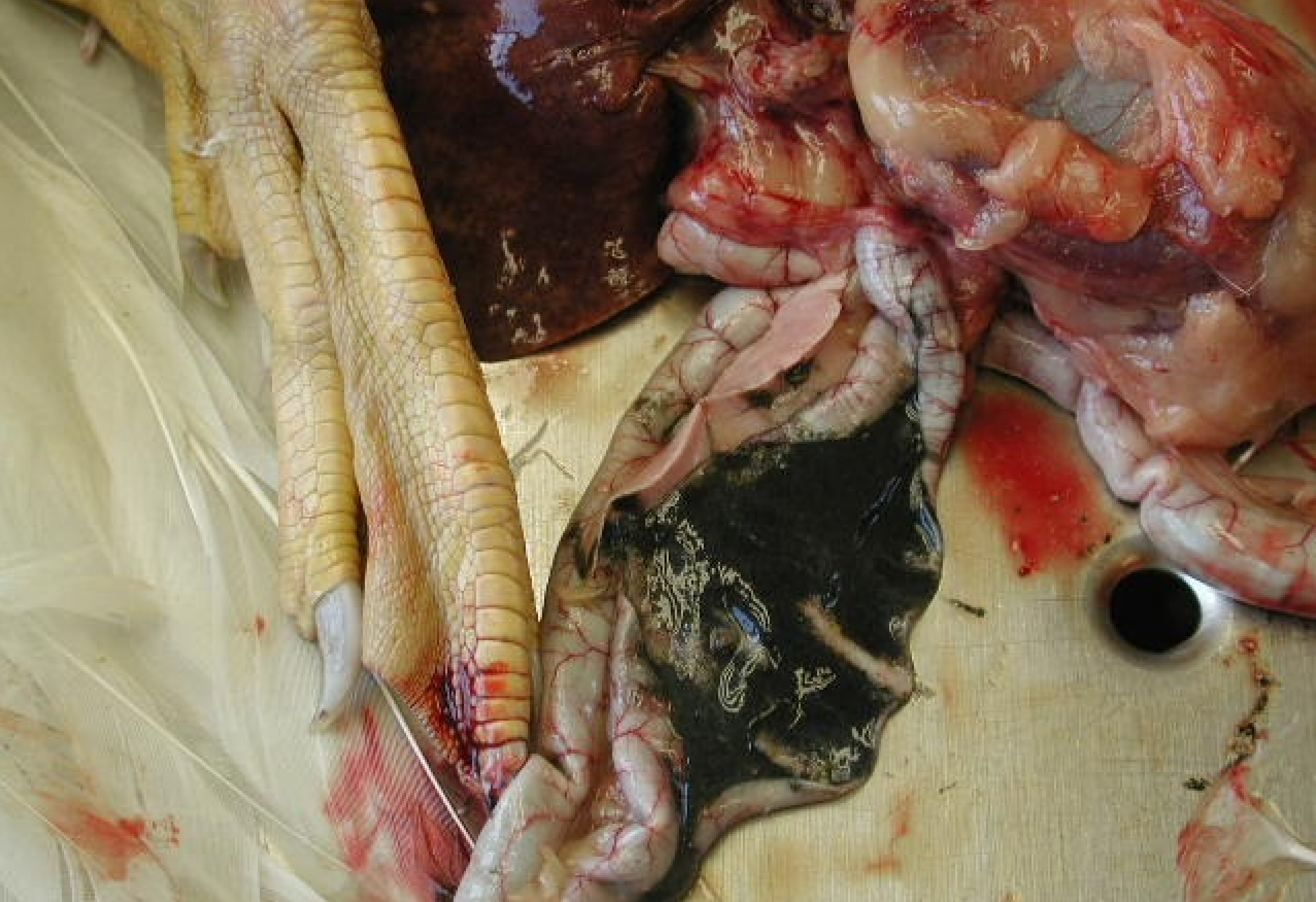Hemorrhagic edema – ND



Ovarian hemorrhage – ND



Intestinal and pancreatic hemorrhagic necrosis
– duck plague herpes virus



Intestinal necrosis – duck plague herpes virus