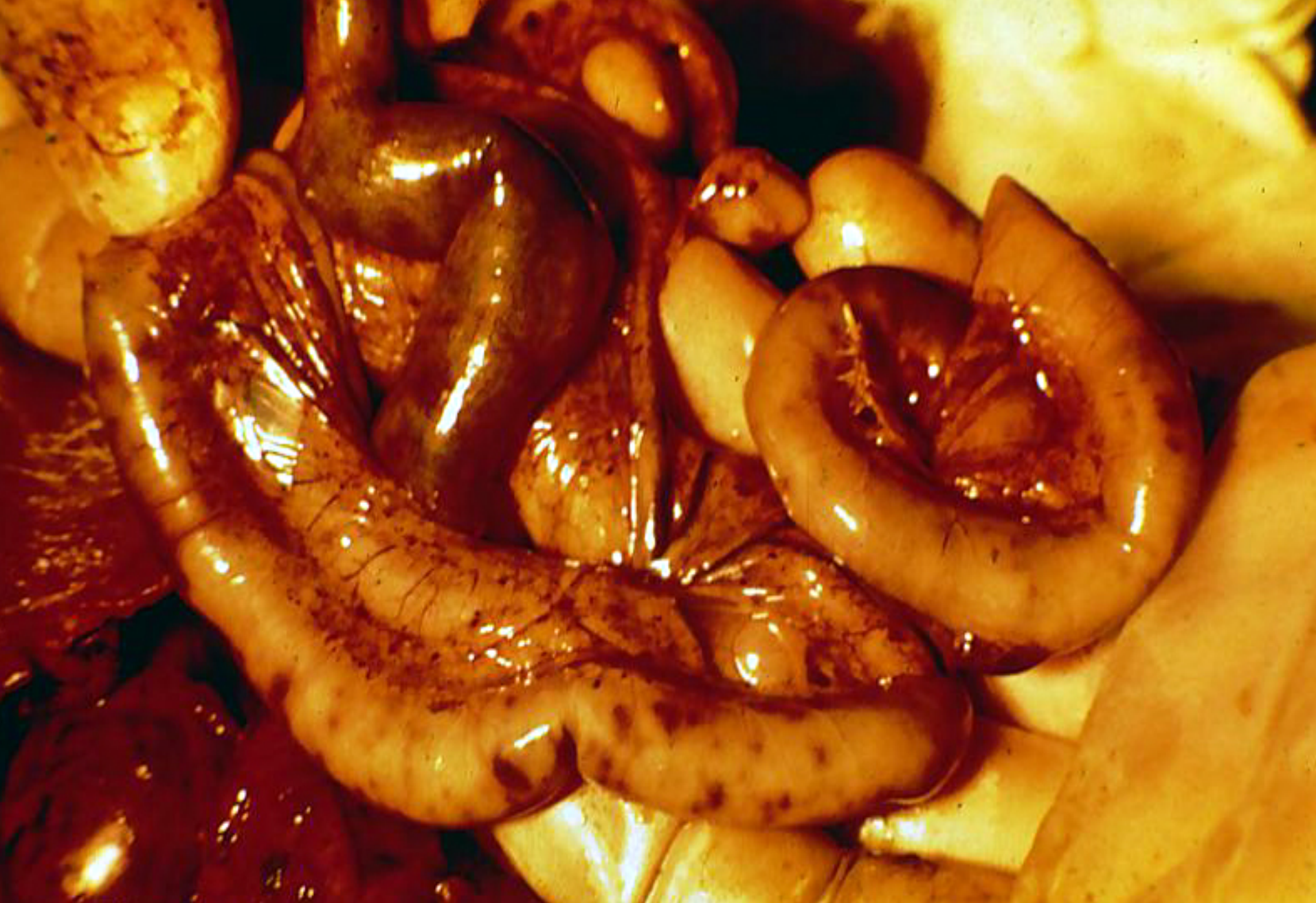
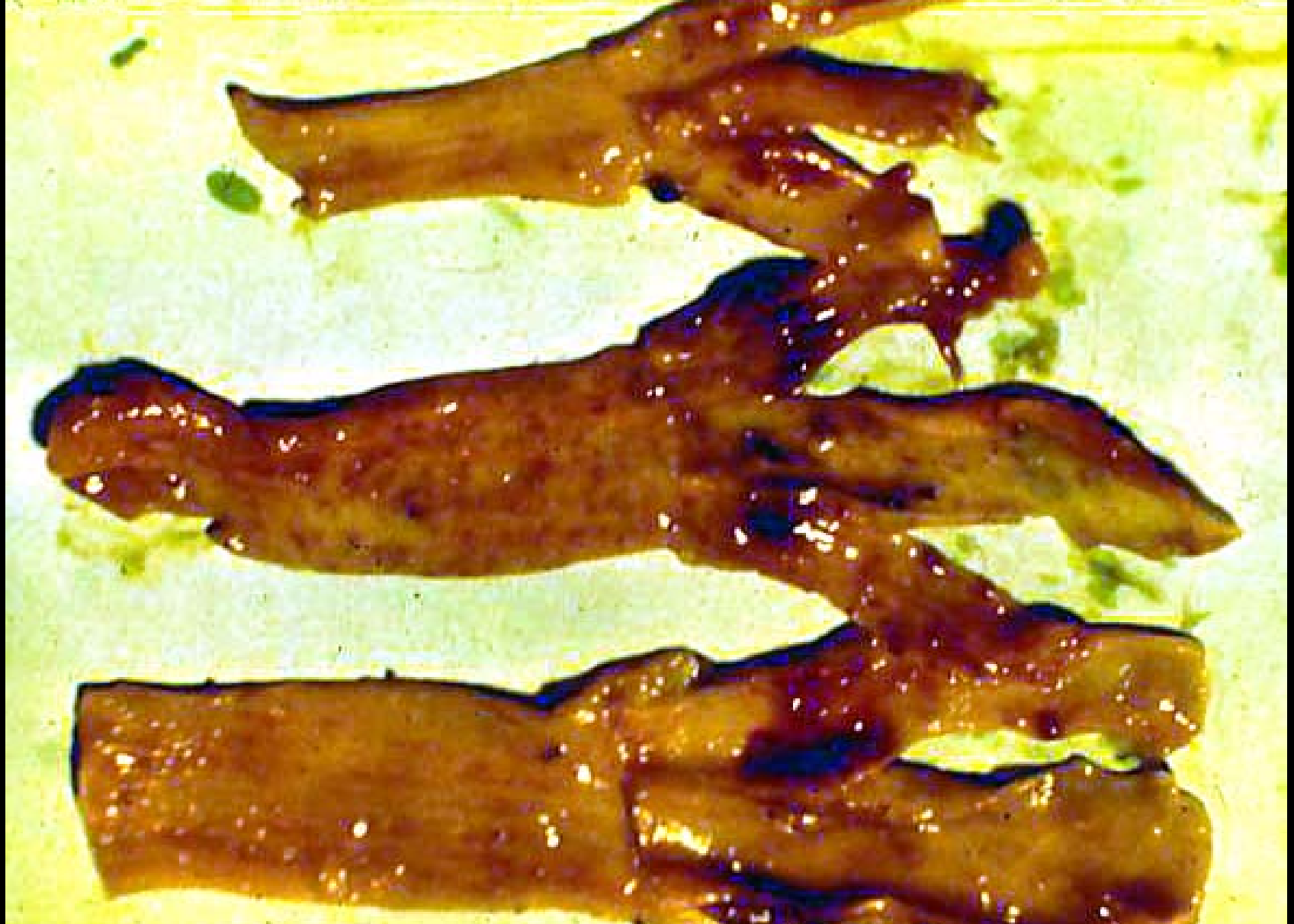
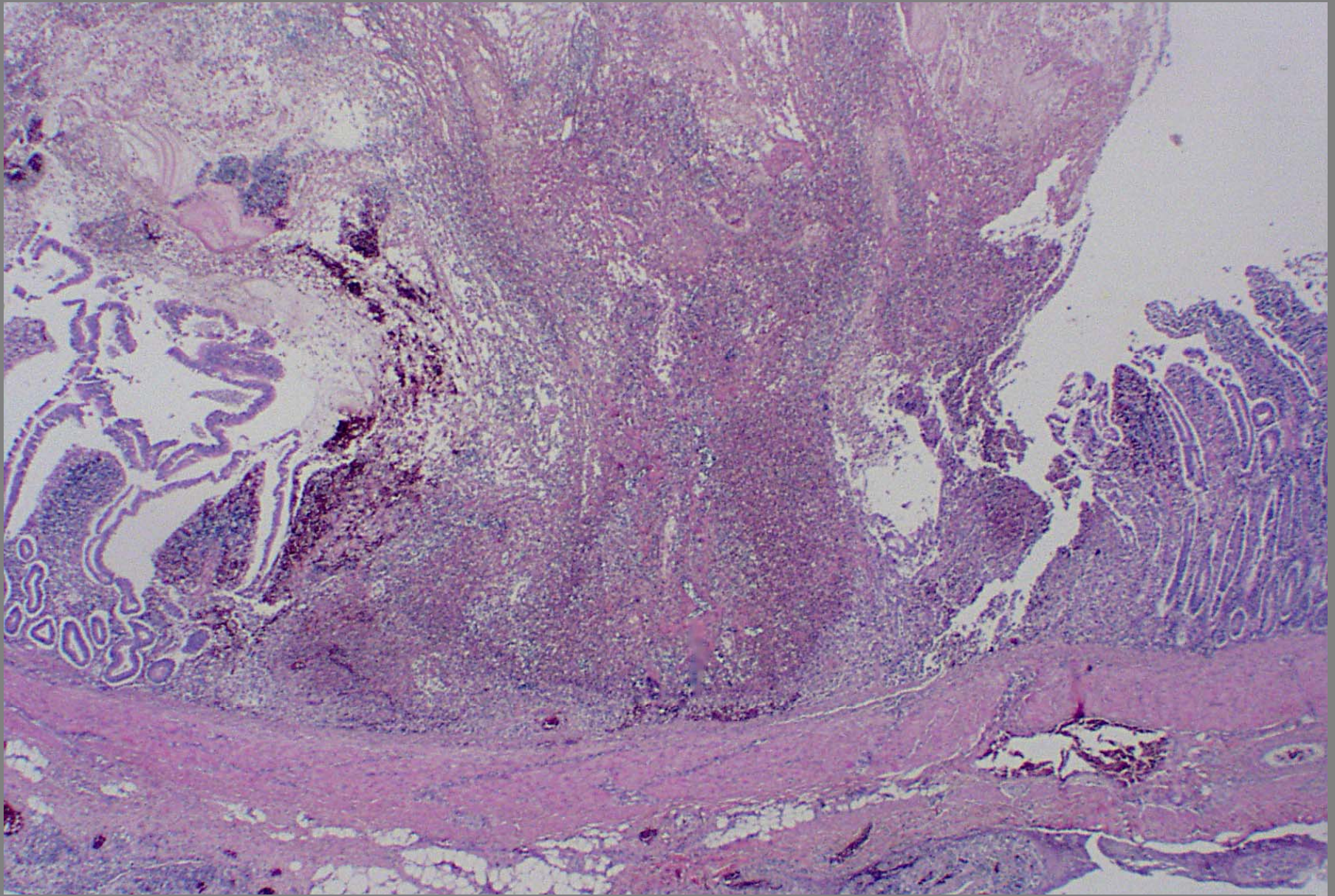


Intestinal hemorrhagic necrosis – ND



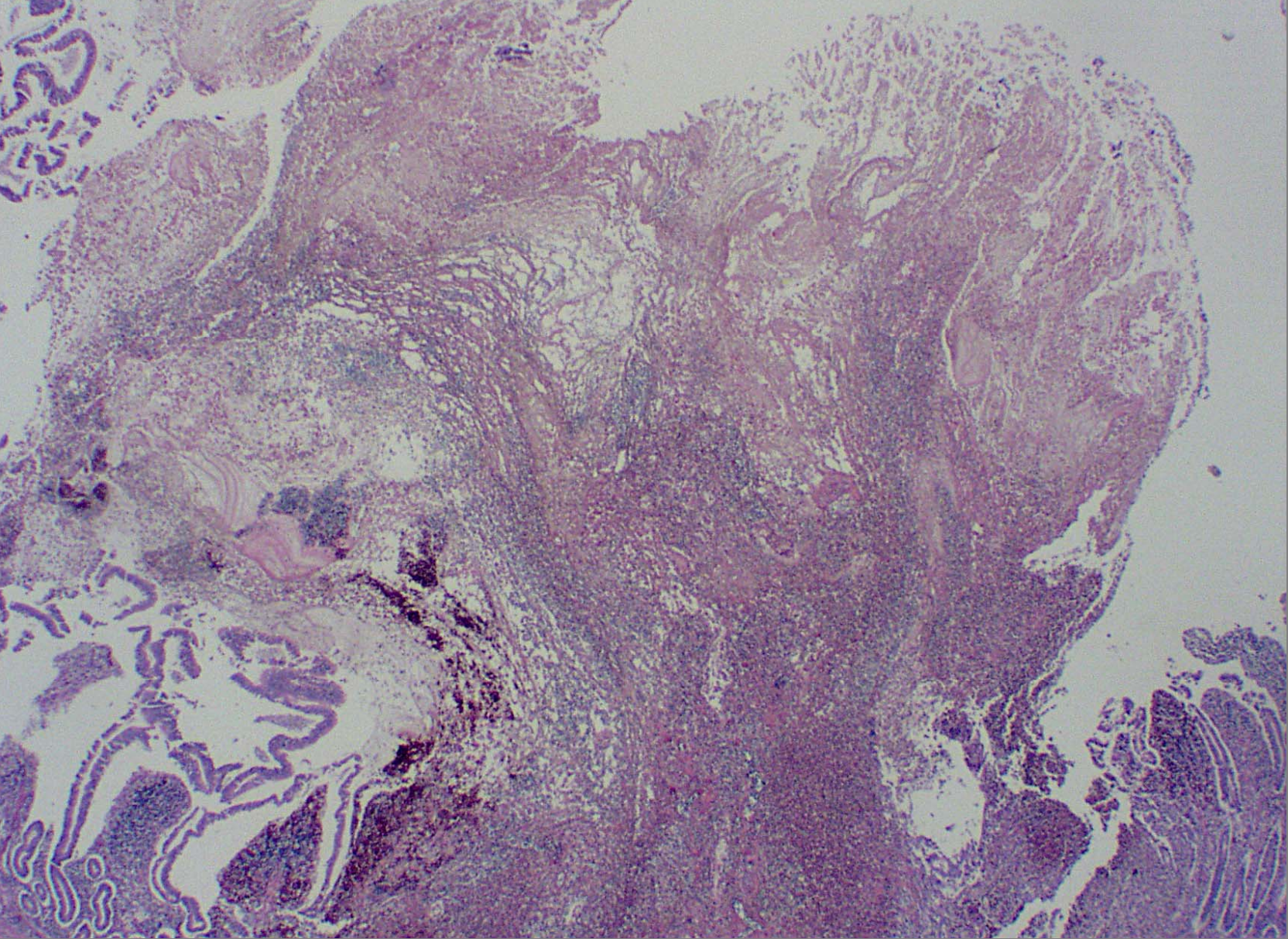
Intestinal hemorrhagic necrosis of lymphoid tissue – ND





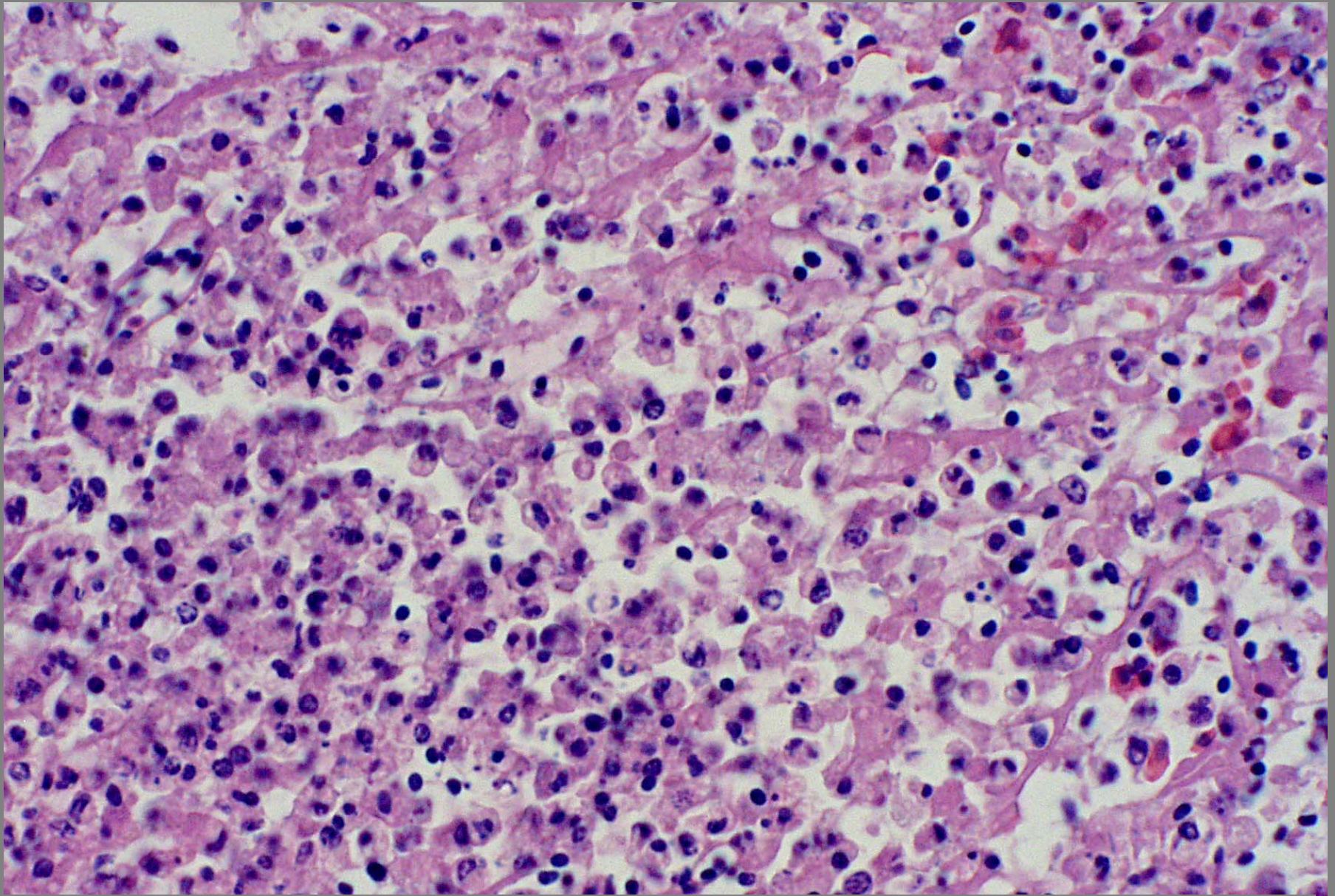
Cecal tonsil necrosis – ND (from Plum Island glass slides set)





Cecal tonsil necrosis – ND (from Plum Island glass slides set)





Cecal tonsil necrosis – ND (from Plum Island glass slides set)