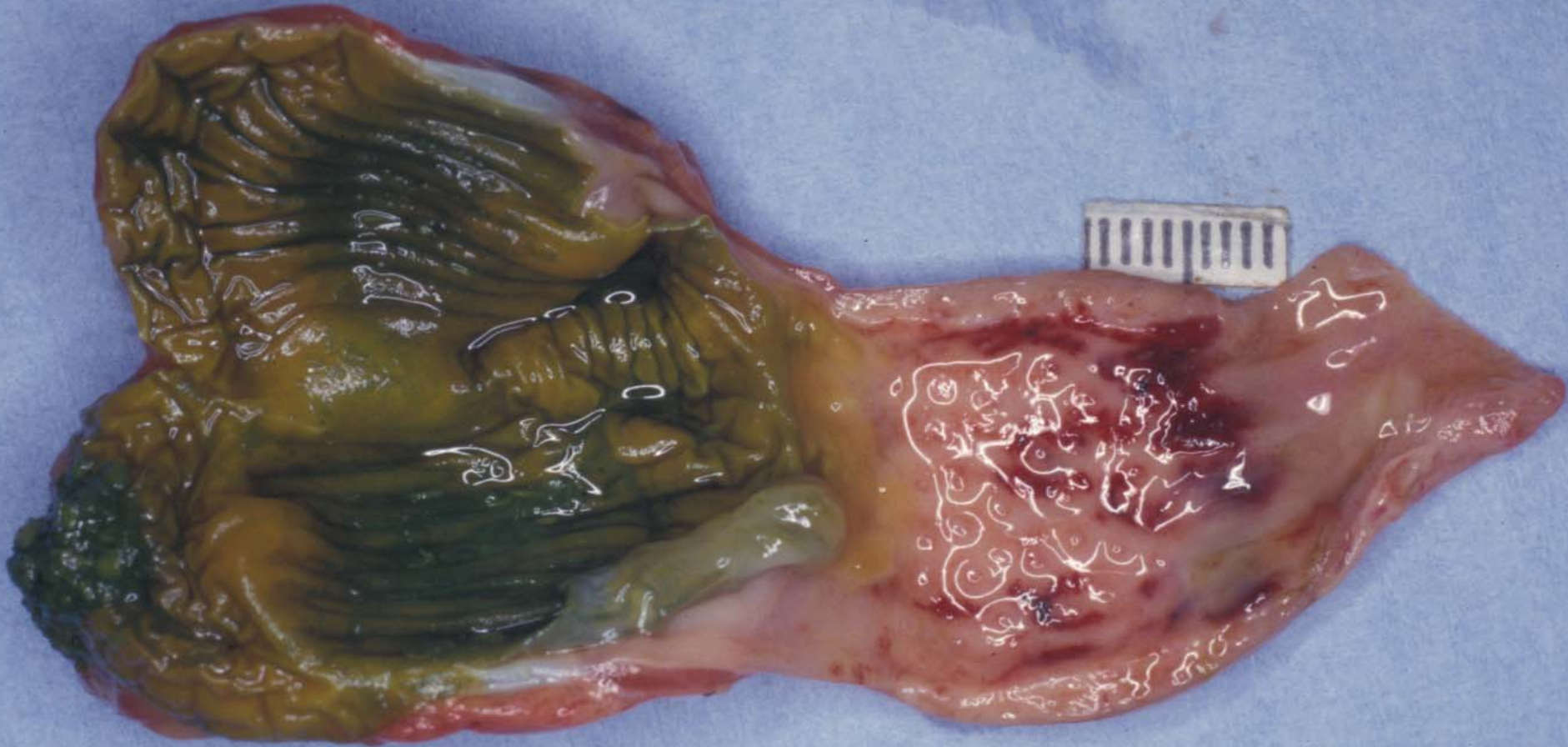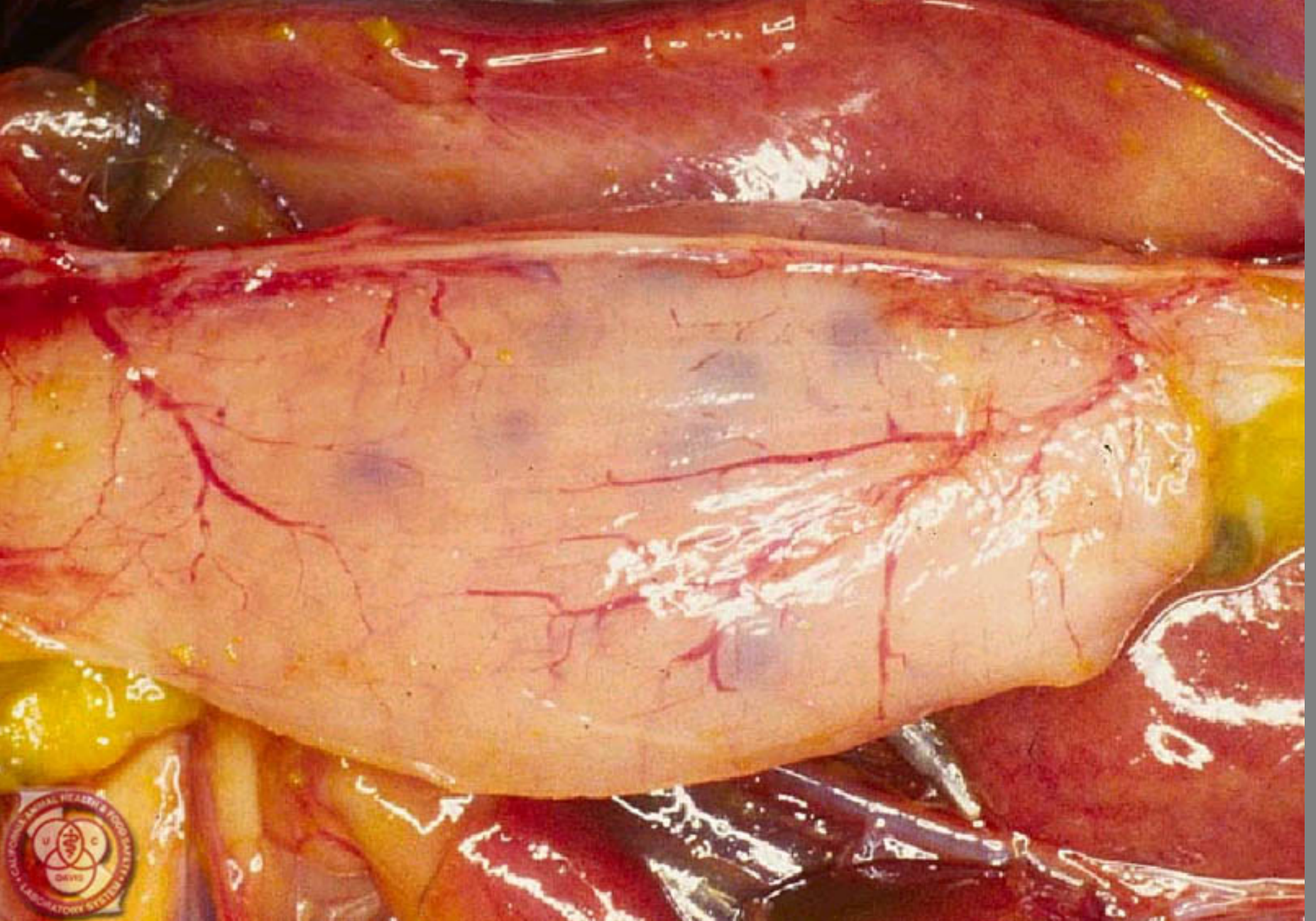
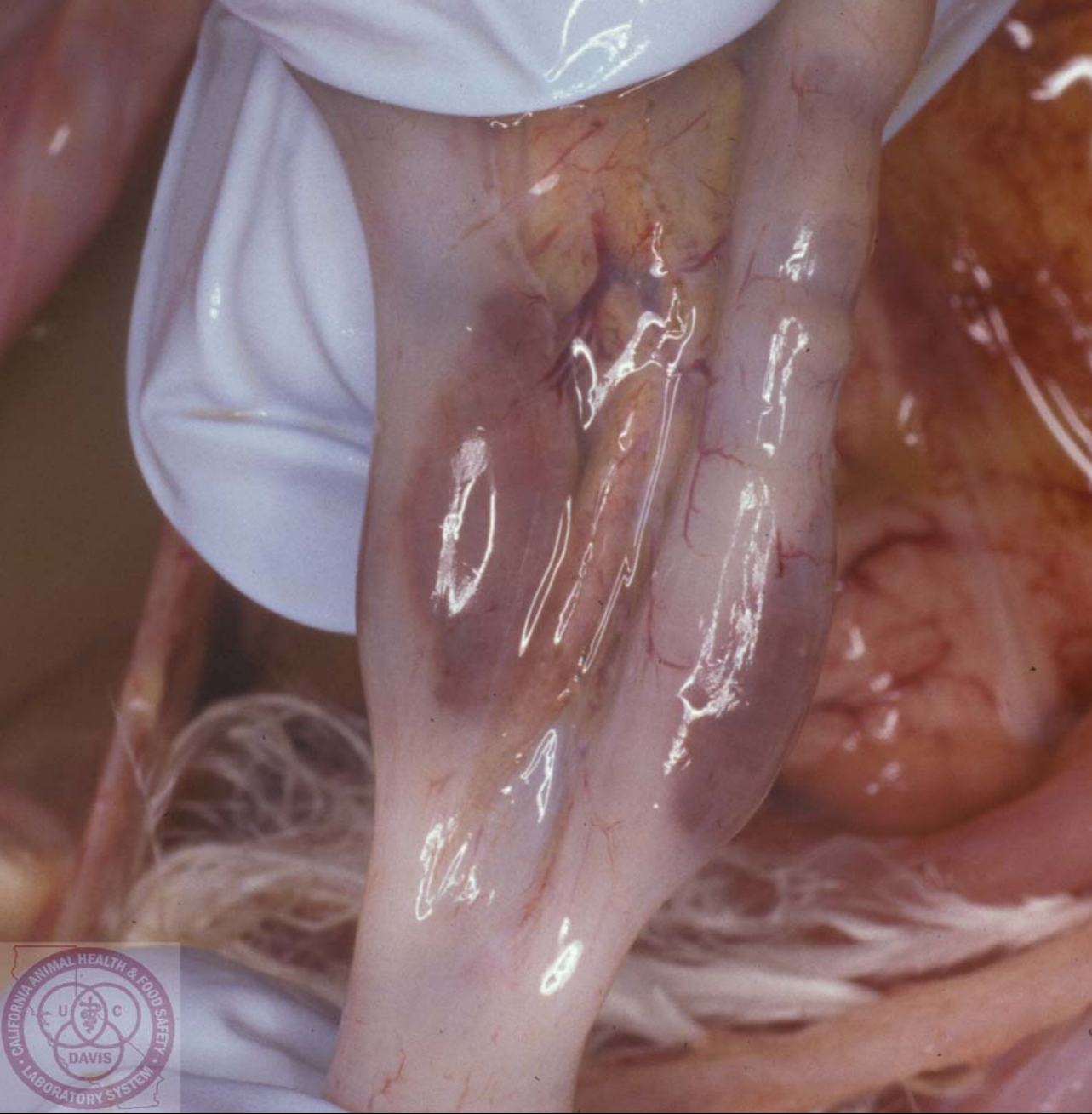


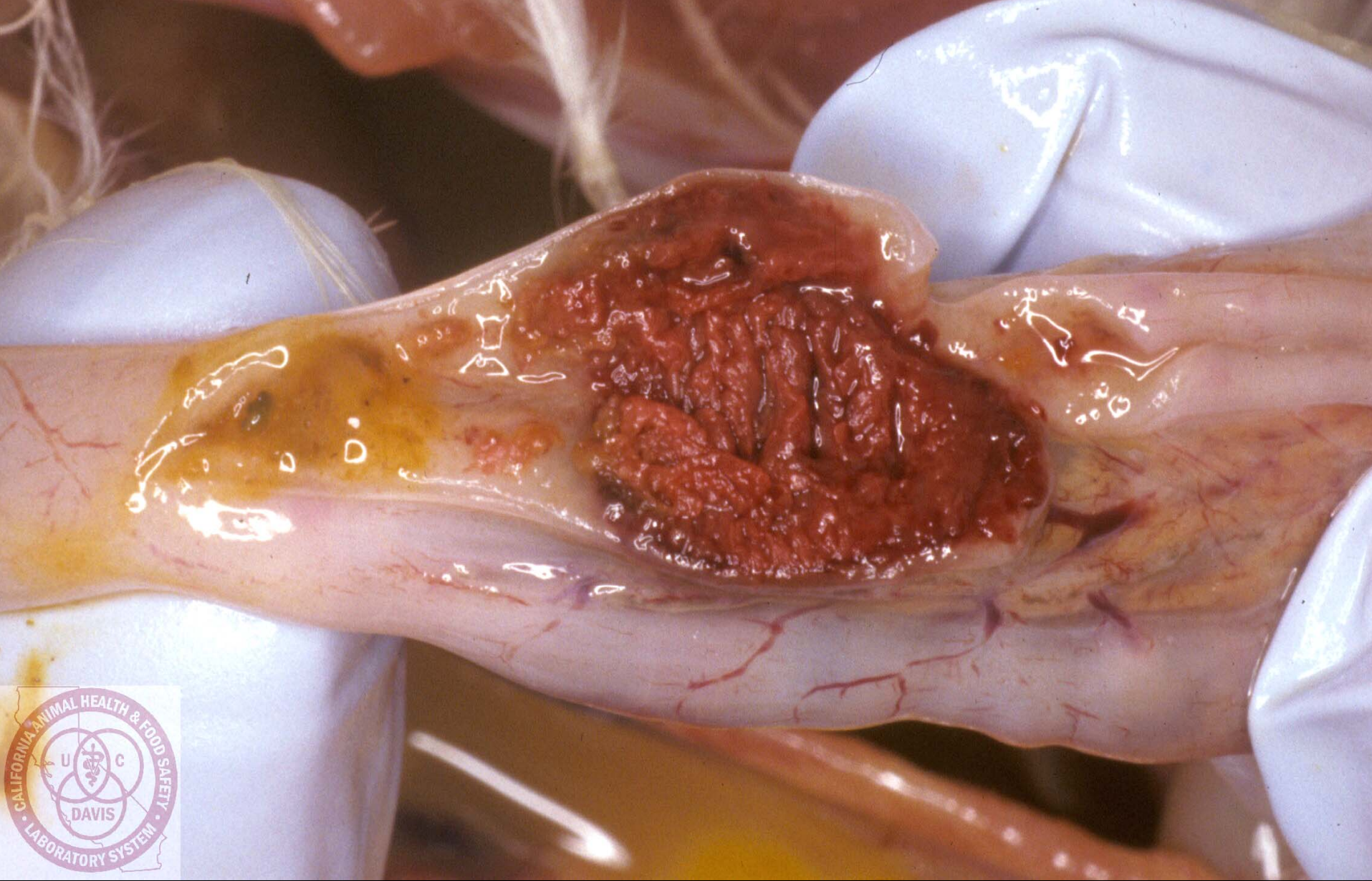
Proventricular hemorrhages and ulcers – ND



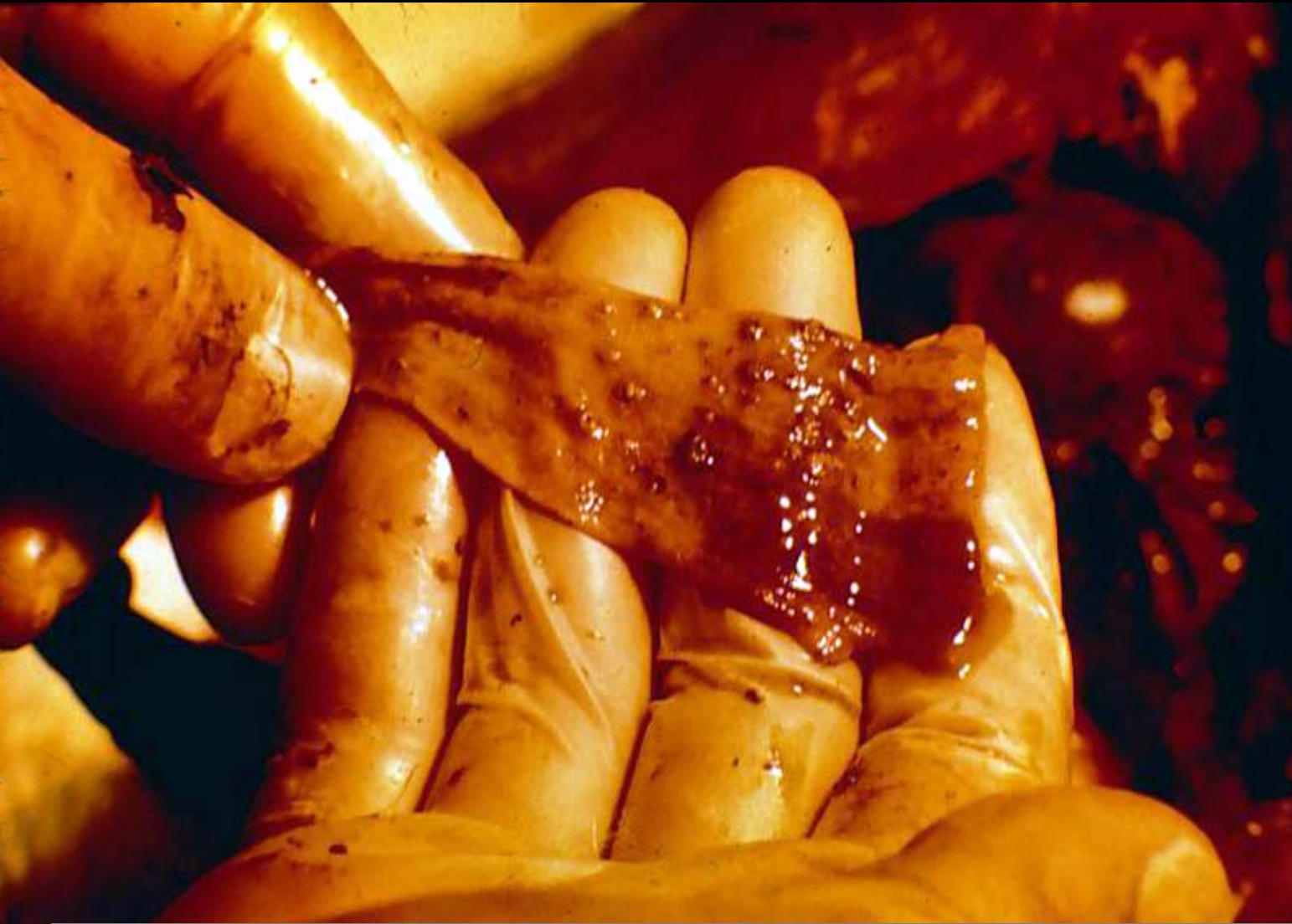Proventricular hemorrhages and ulcers – ND



Cecal tonsil necrosis and hemorrhage - ND



Cecal tonsil necrosis and hemorrhage – ND



Intestinal hemorrhagic necrosis of lymphoid tissue – ND