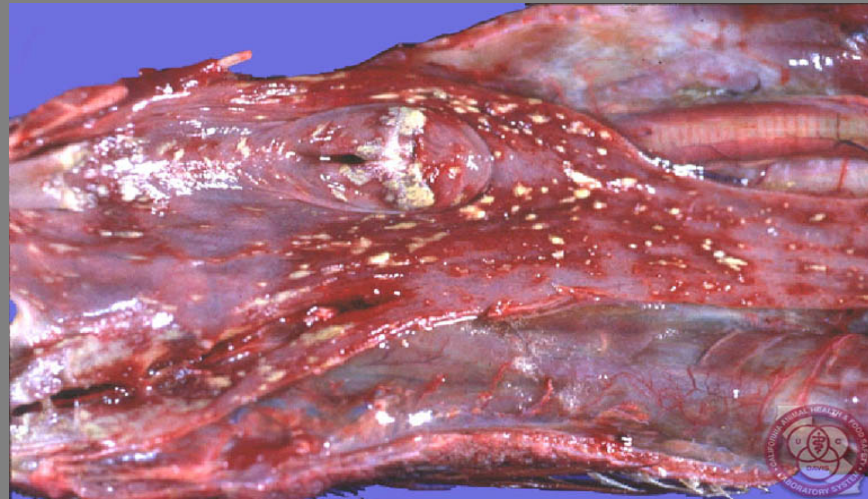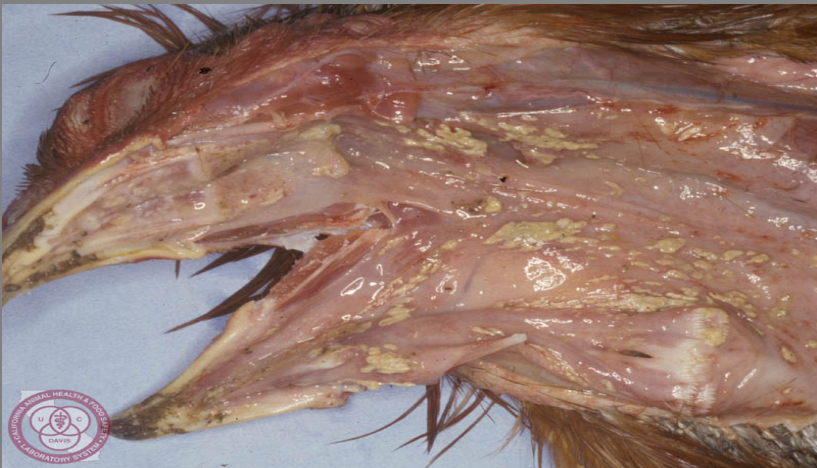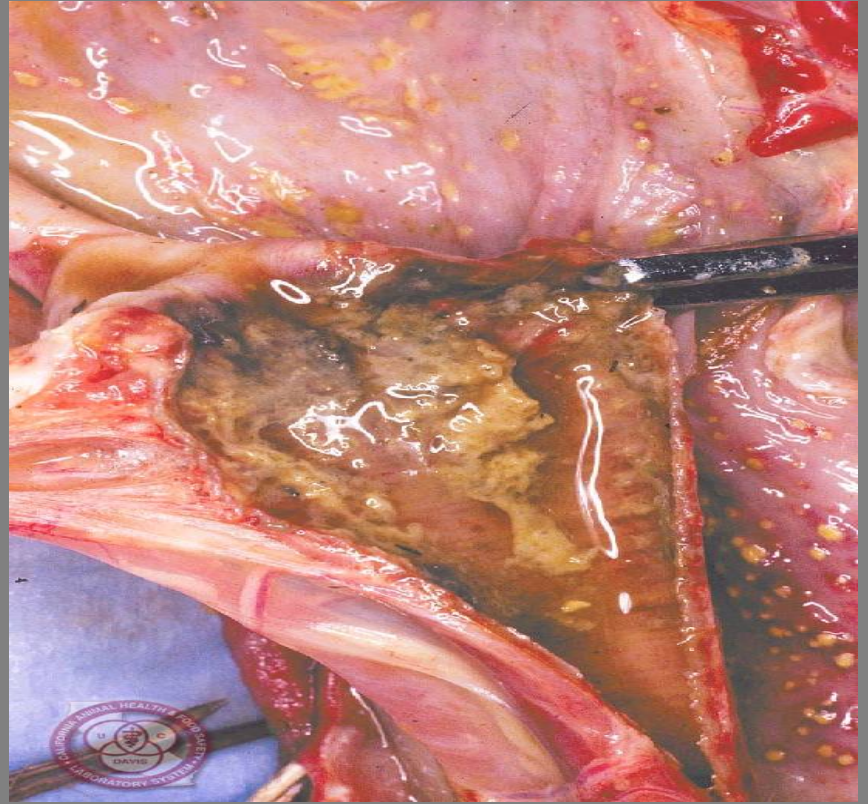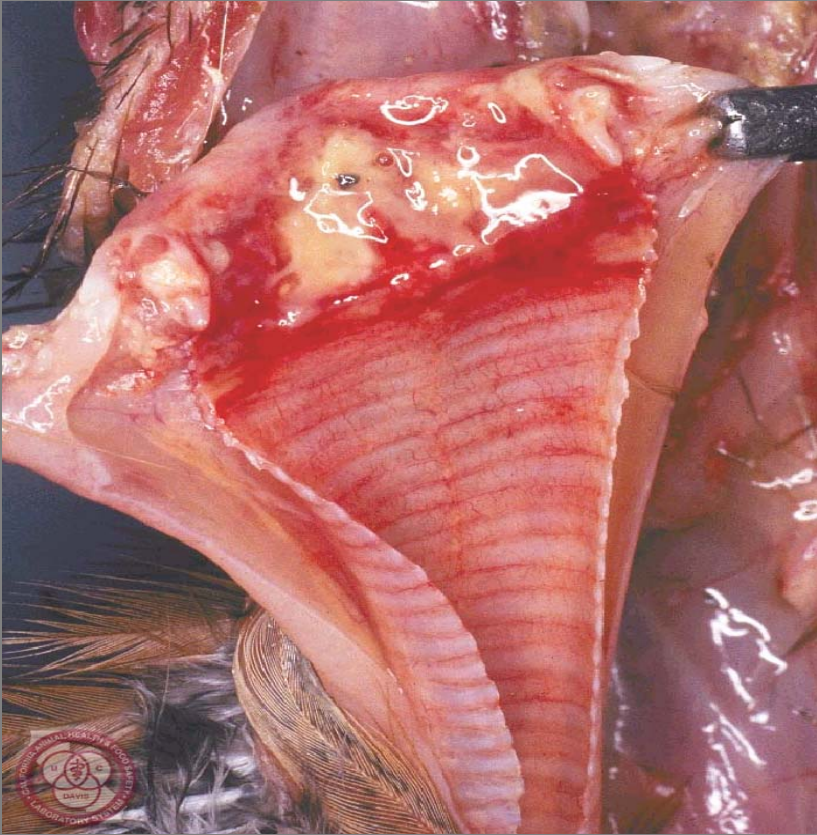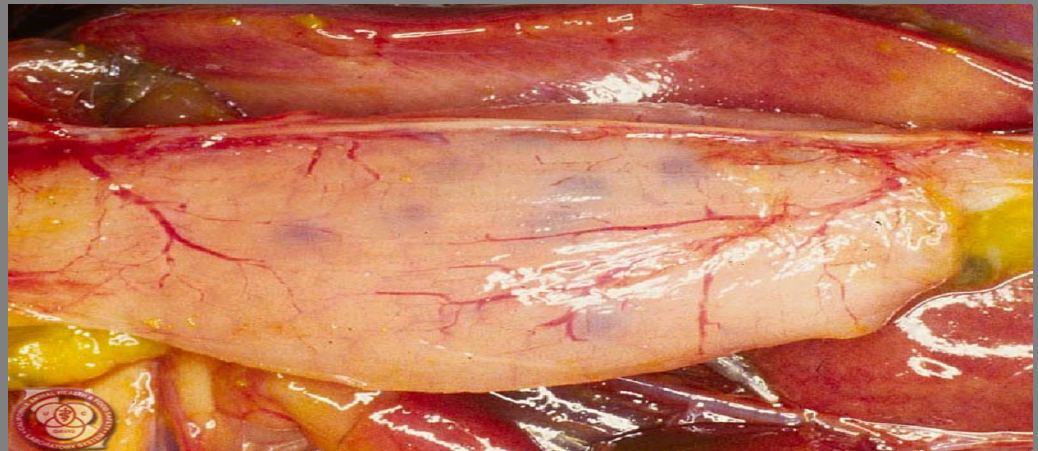
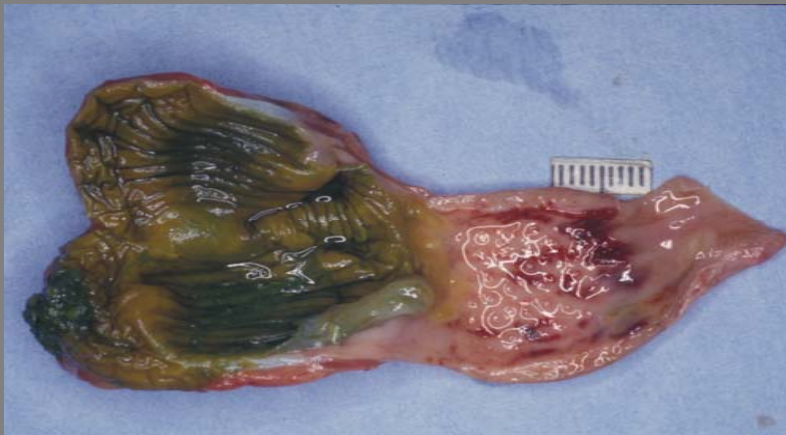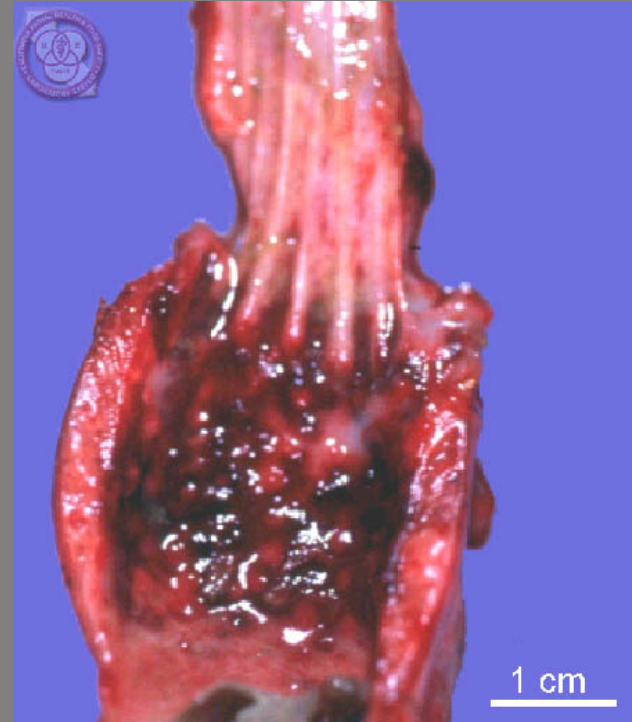
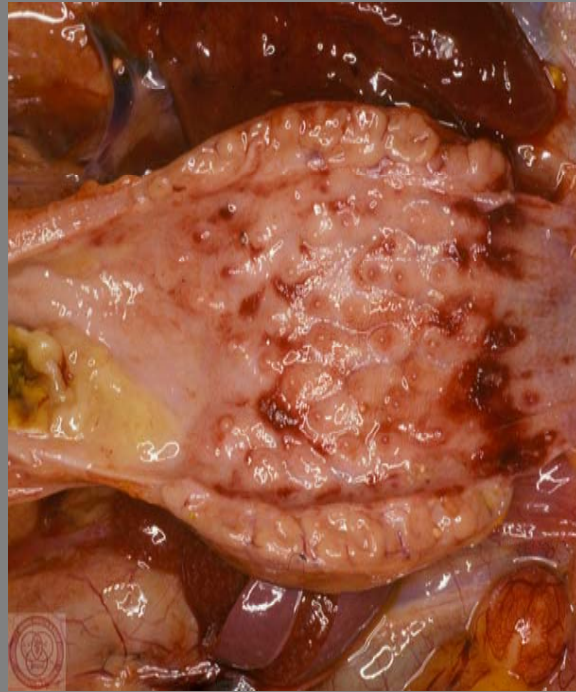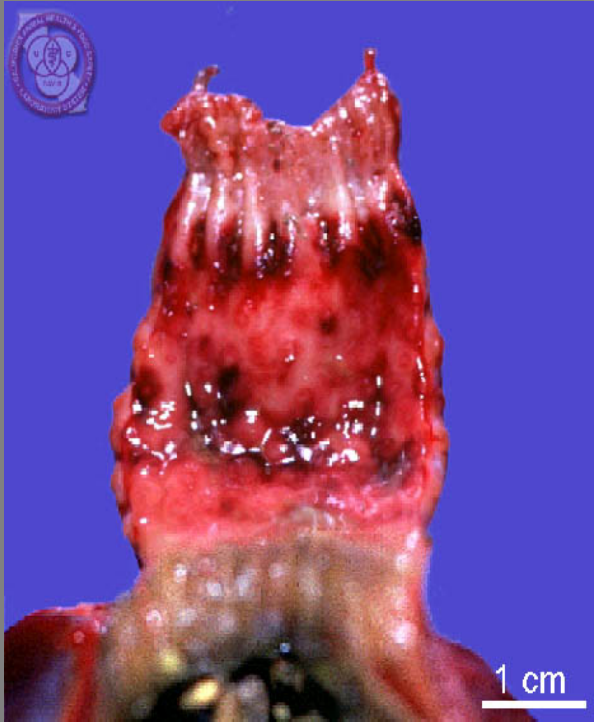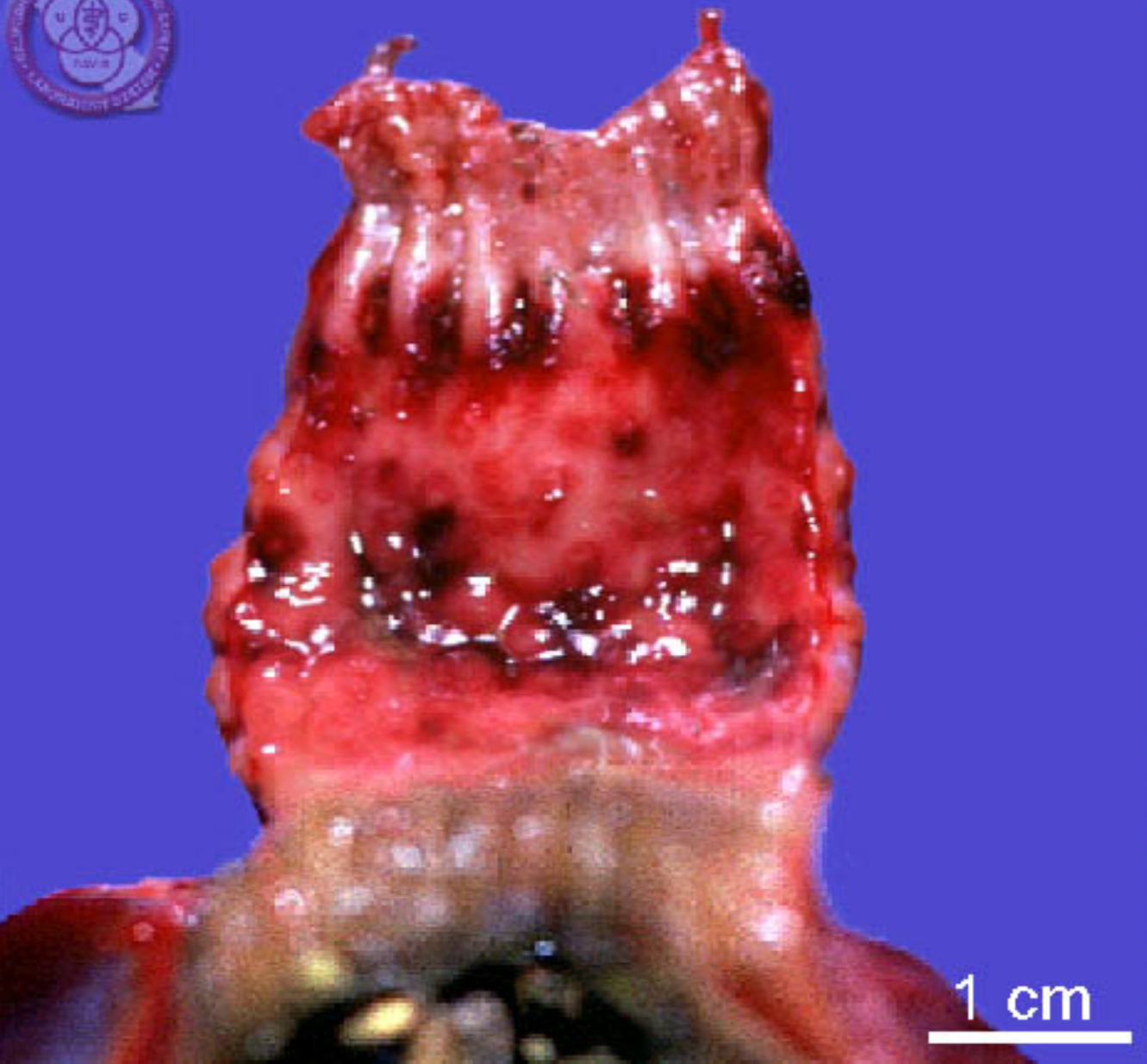




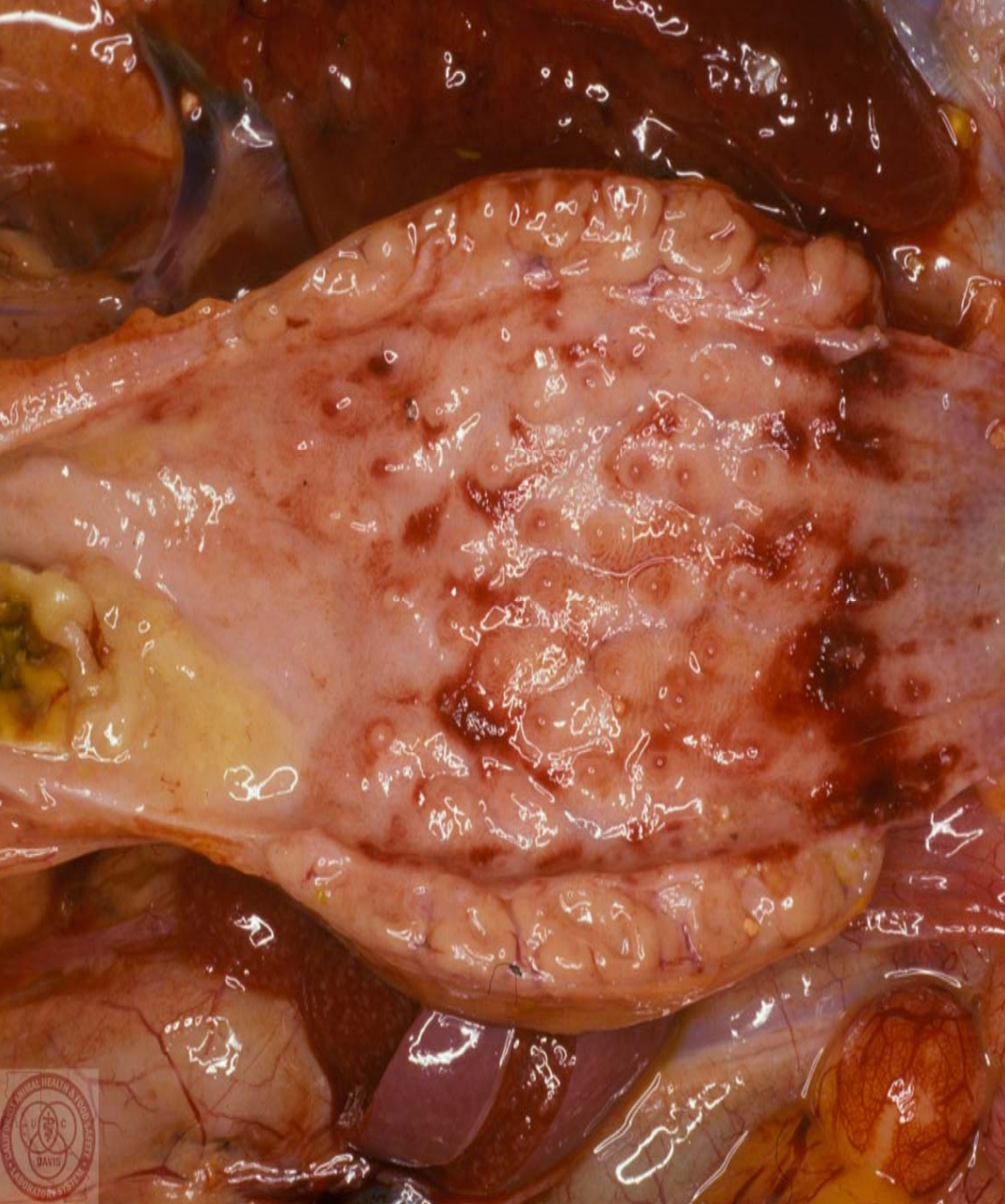Proventricular hemorrhages: multifocal/diffuse or at the esophageal junction; proventricular ulceration



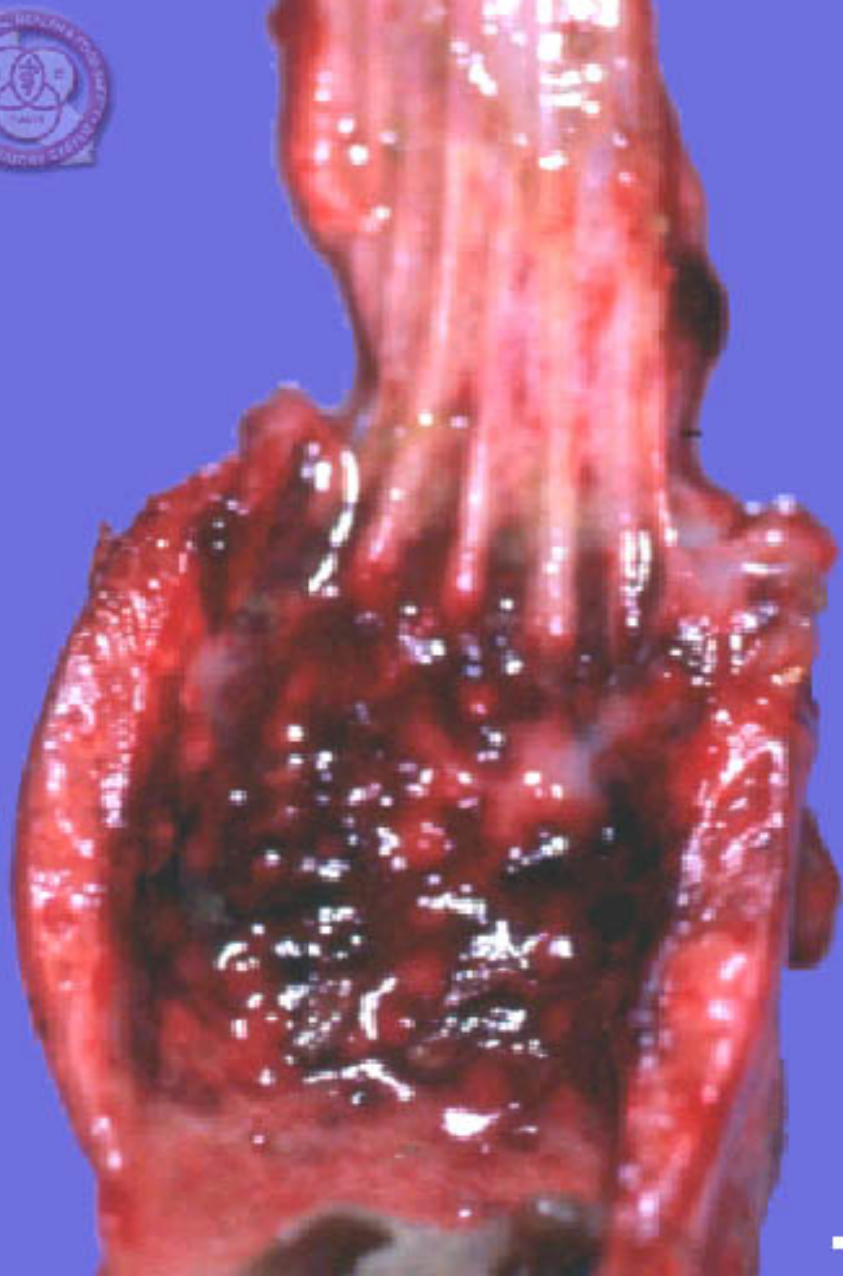

Proventricular hemorrhages – ND





Proventricular hemorrhages – ND



1 cm

Proventricular hemorrhages – ND