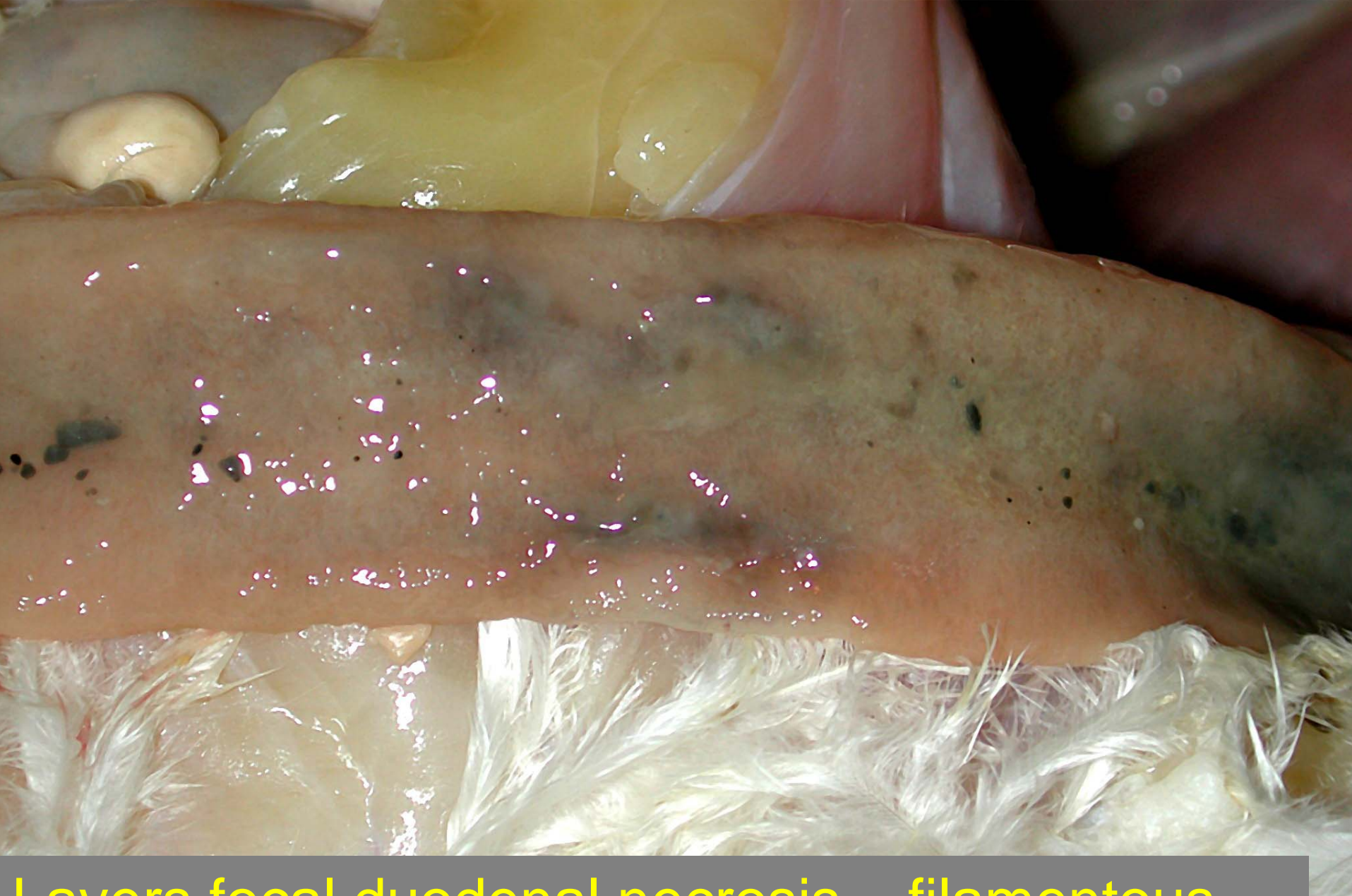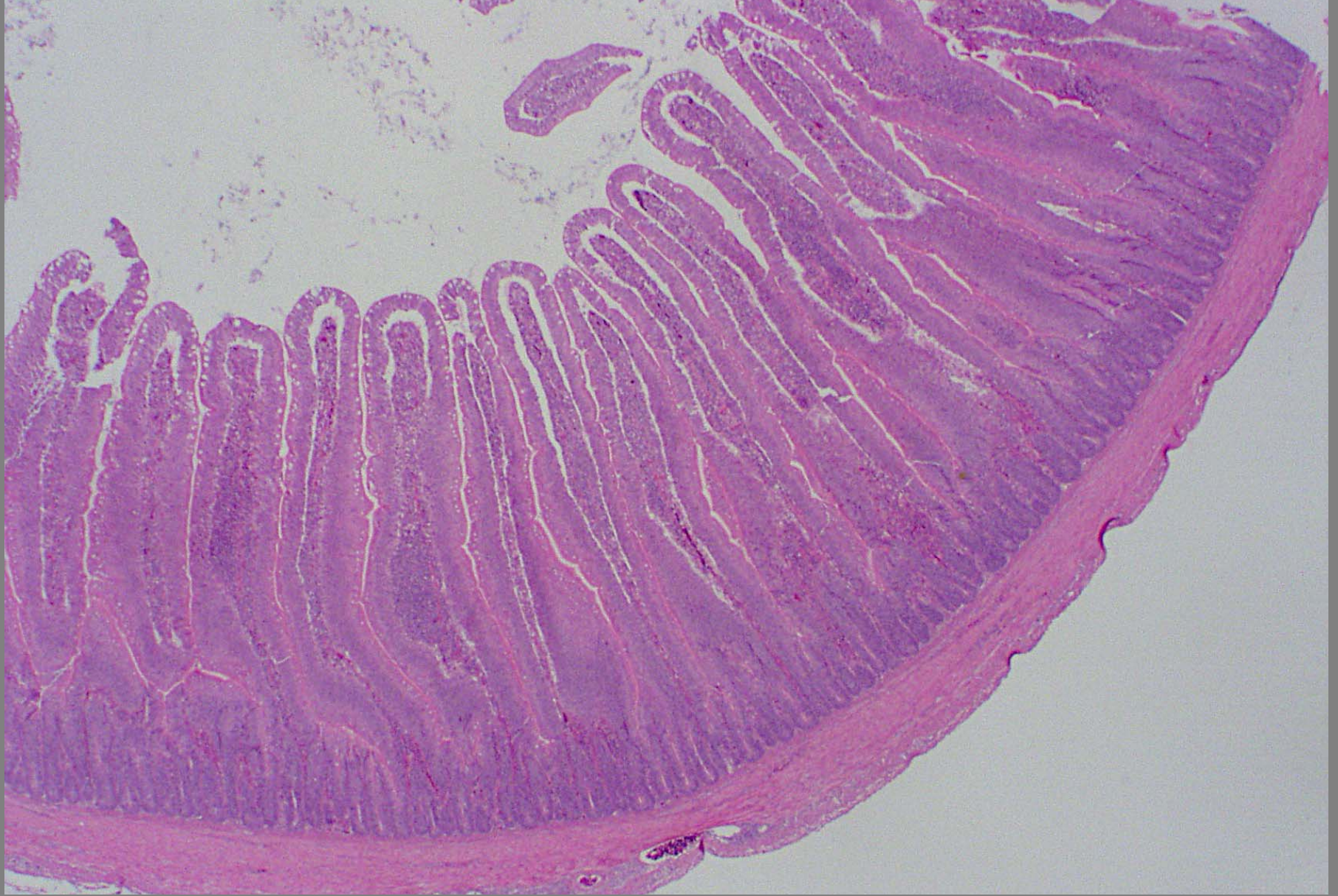


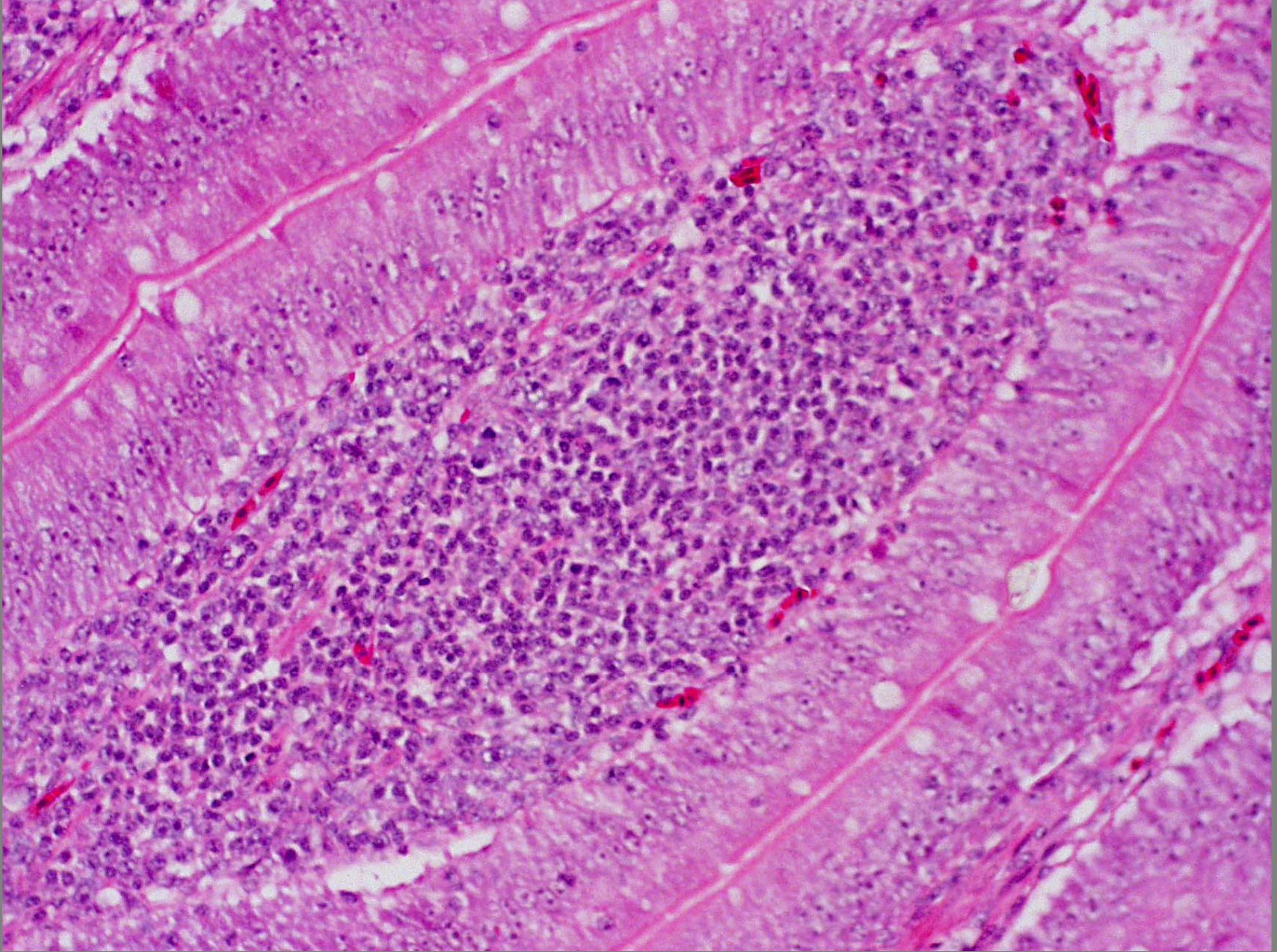
Layers focal duodenal necrosis – filamentous bacteria





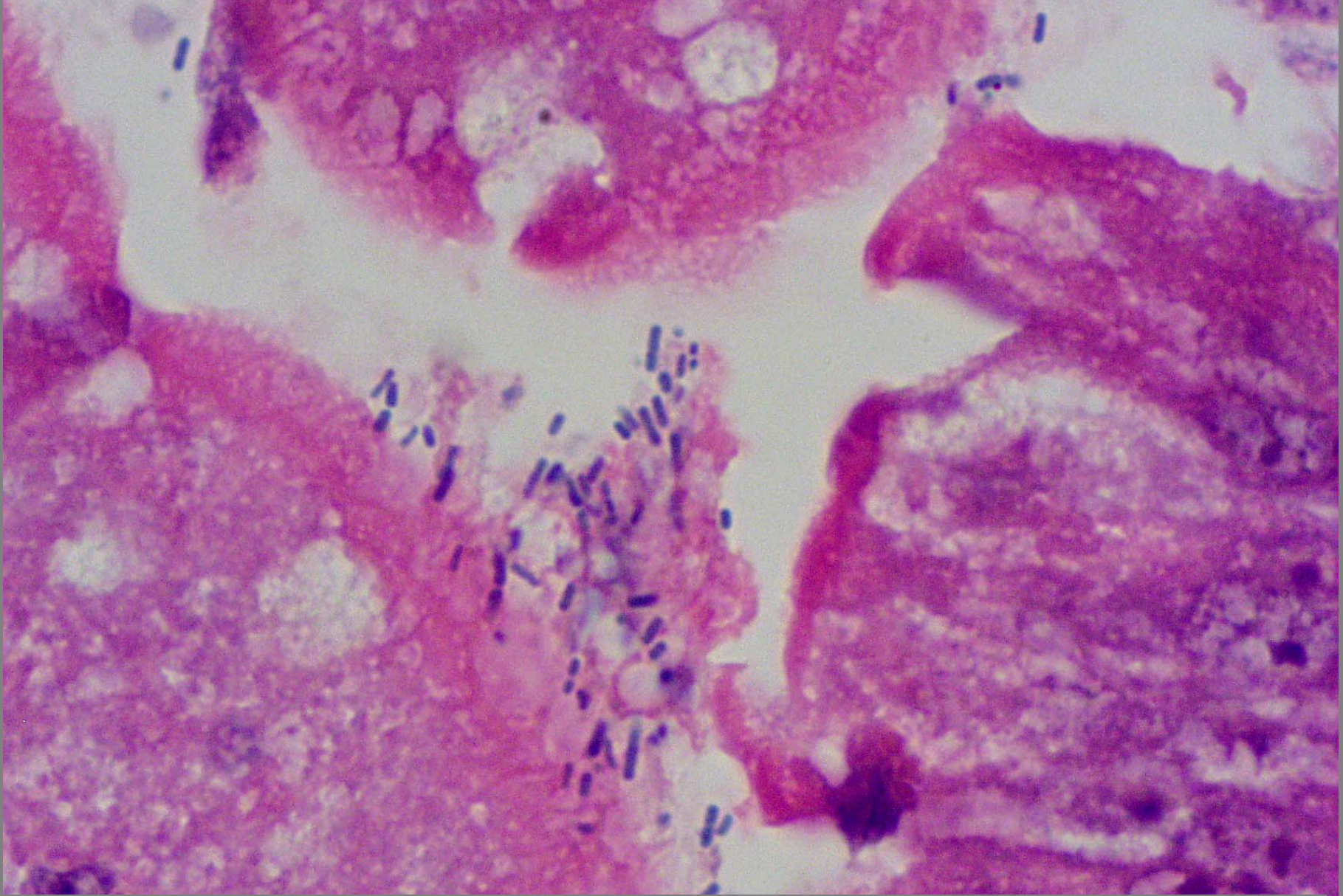
Chronic lymphoplasmacytic enteritis associated with short bacilli and poor growth





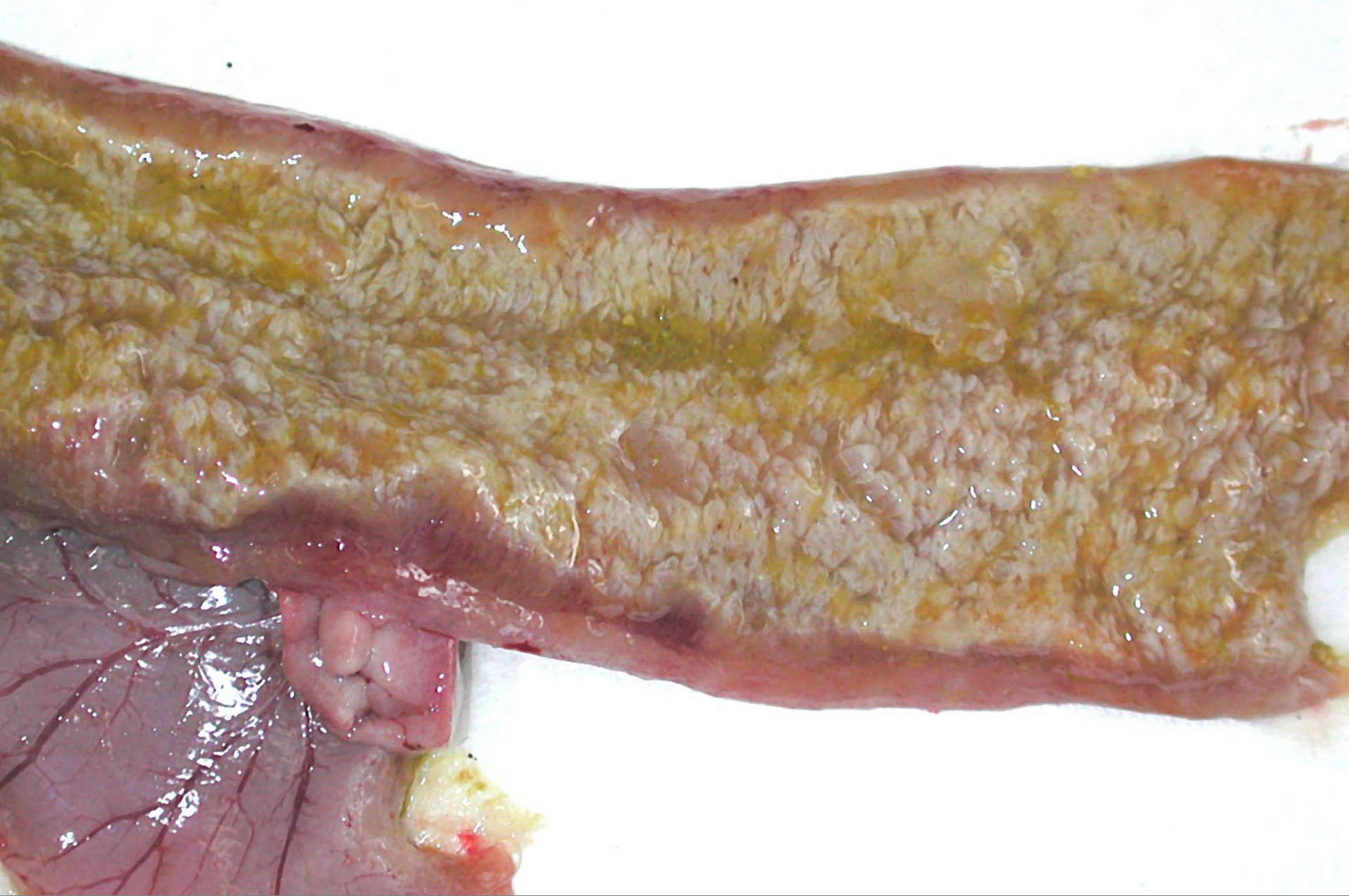
Chronic lymphoplasmacytic enteritis associated with poor growth





Chronic lymphoplasmacytic enteritis associated with short bacilli and poor growth





Young turkey – enteritis – ascarid larvae