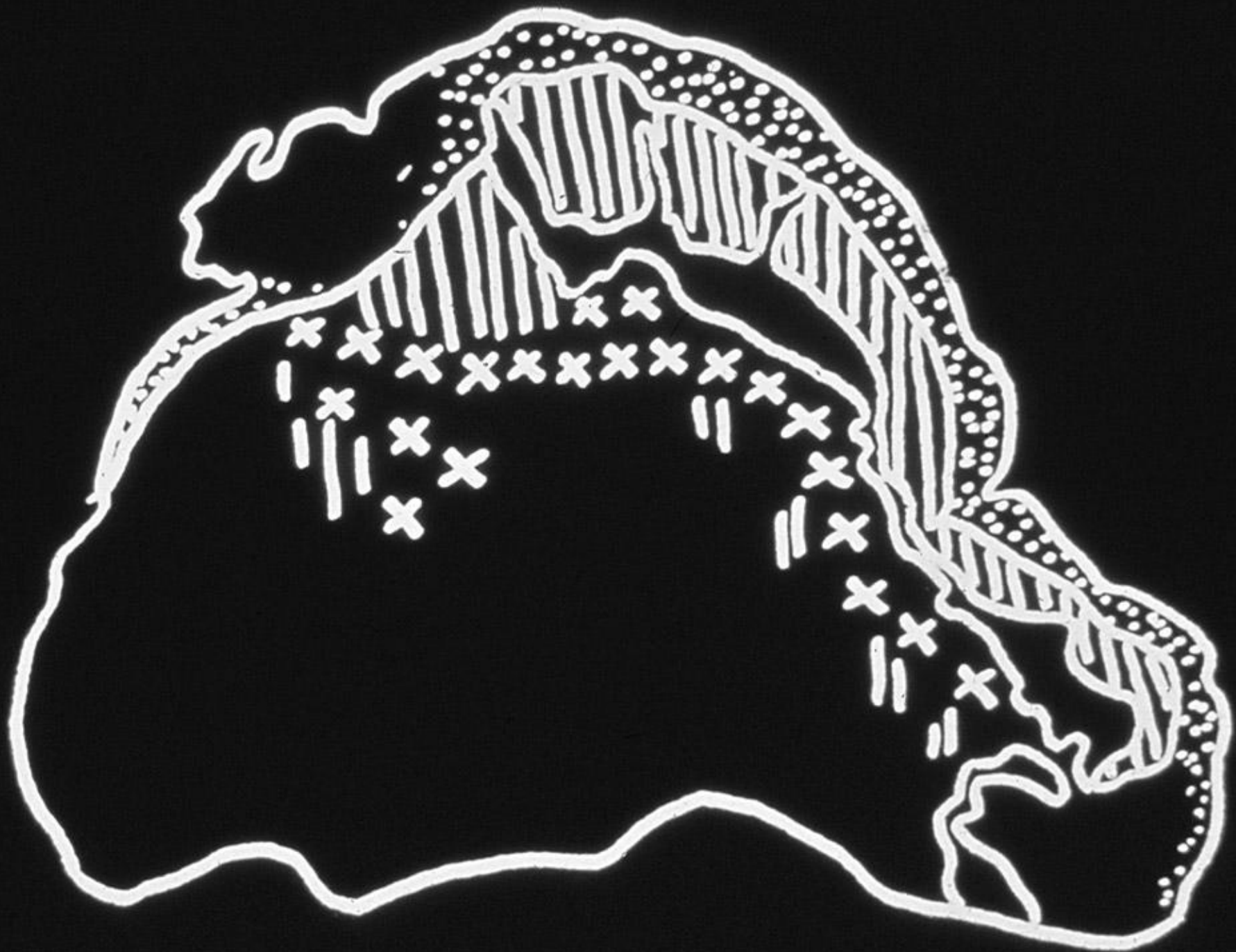
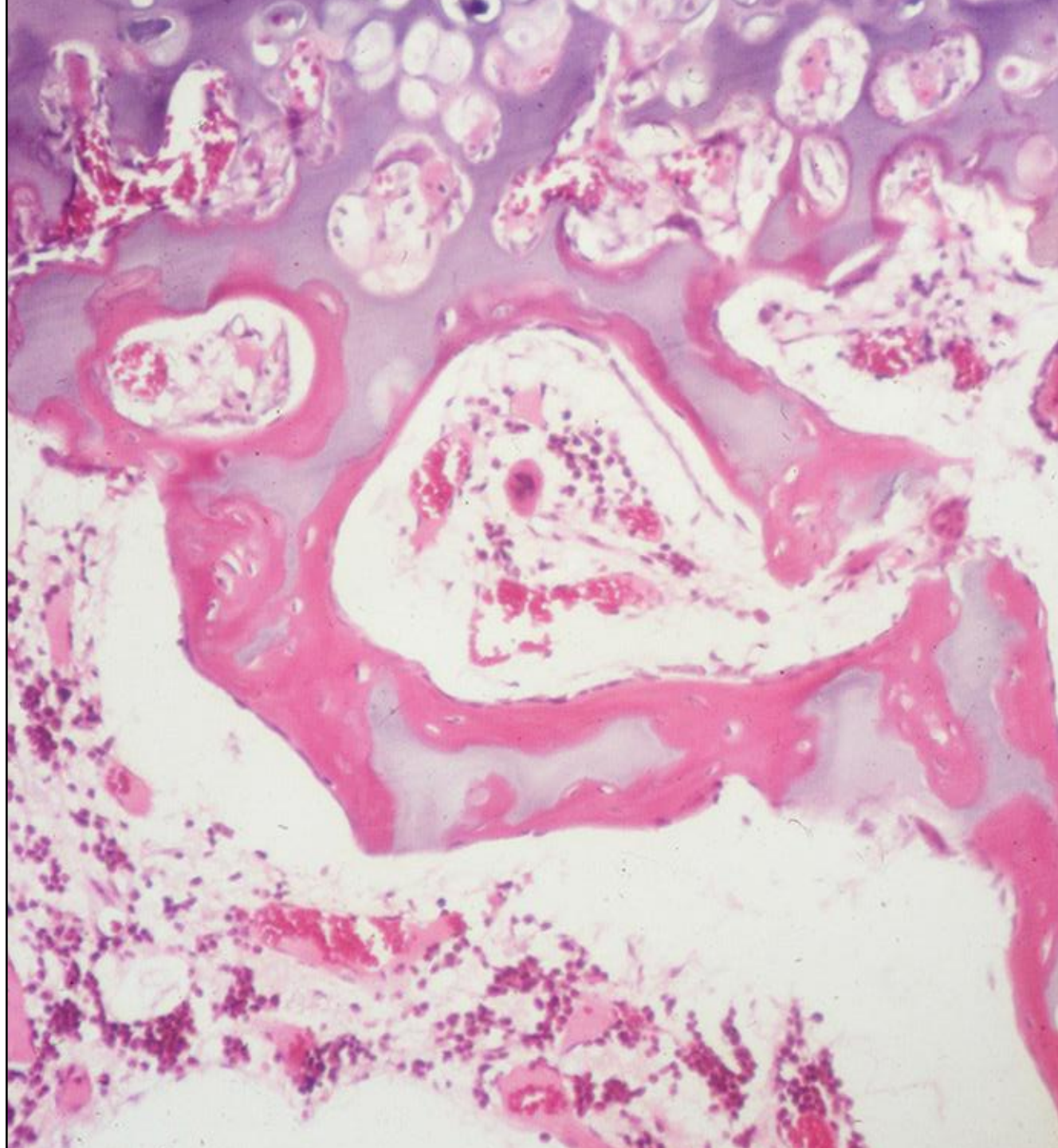


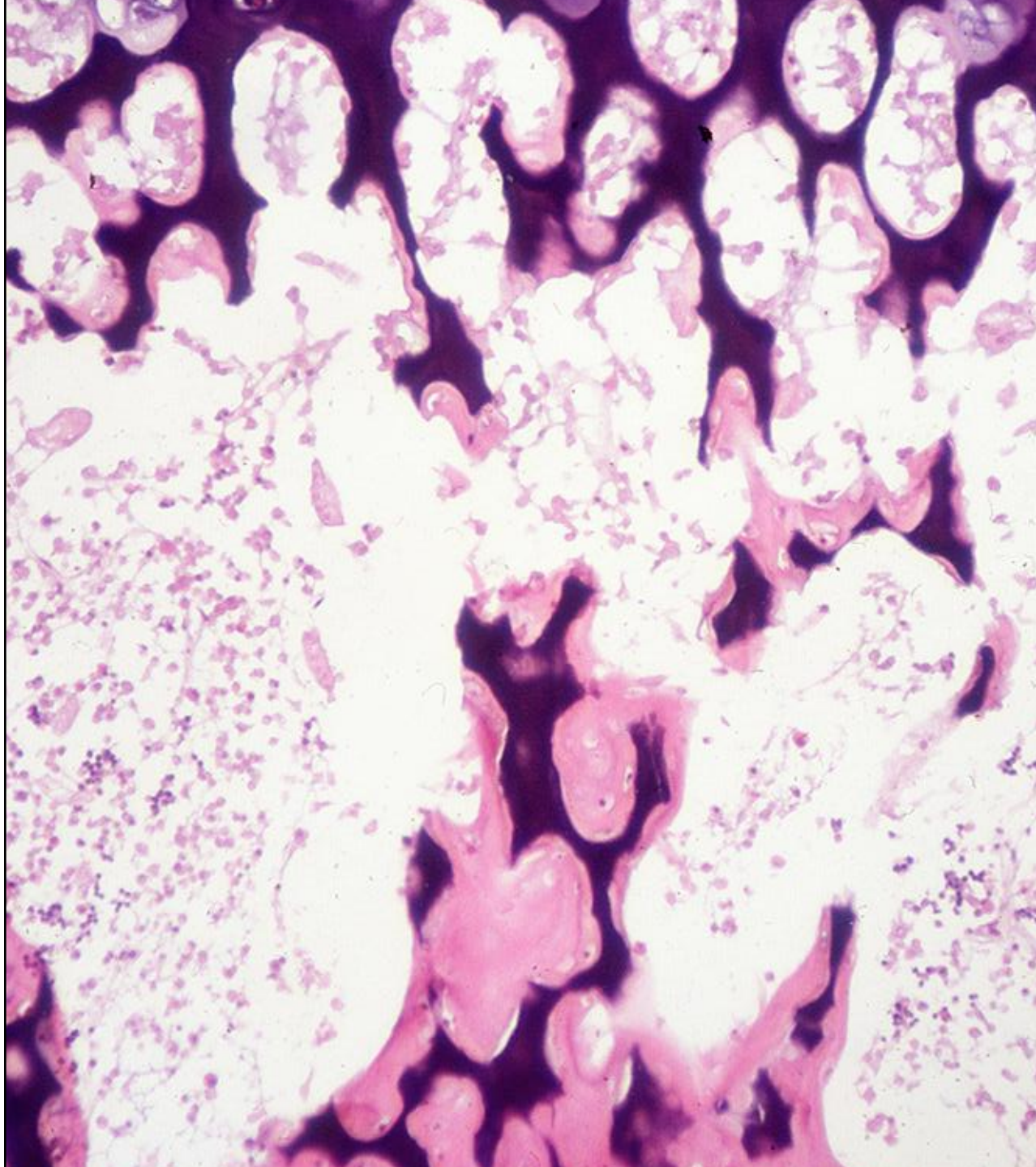
Sterile Bone Necrosis

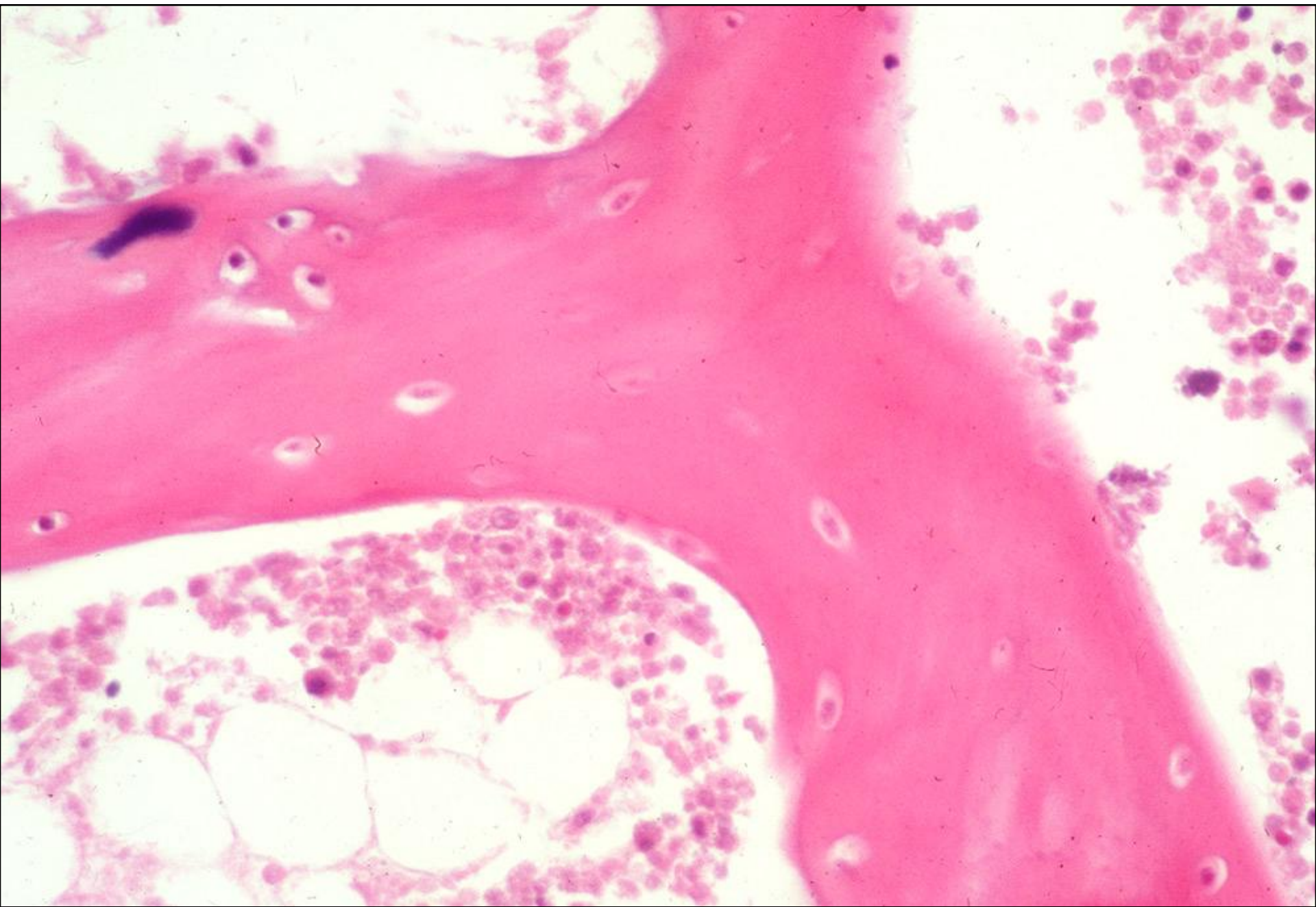
Idiopathic Necrosis of Femoral Head

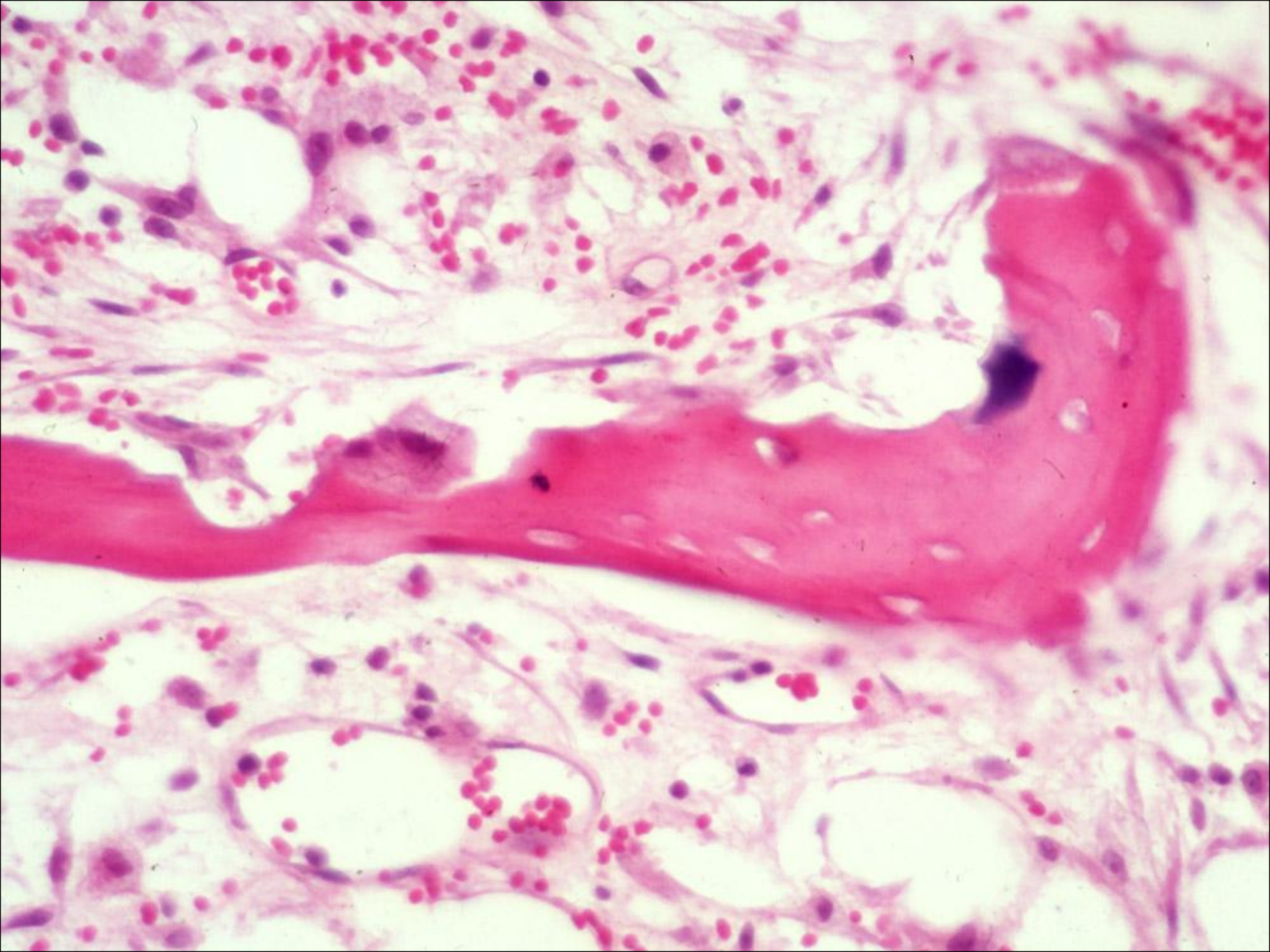


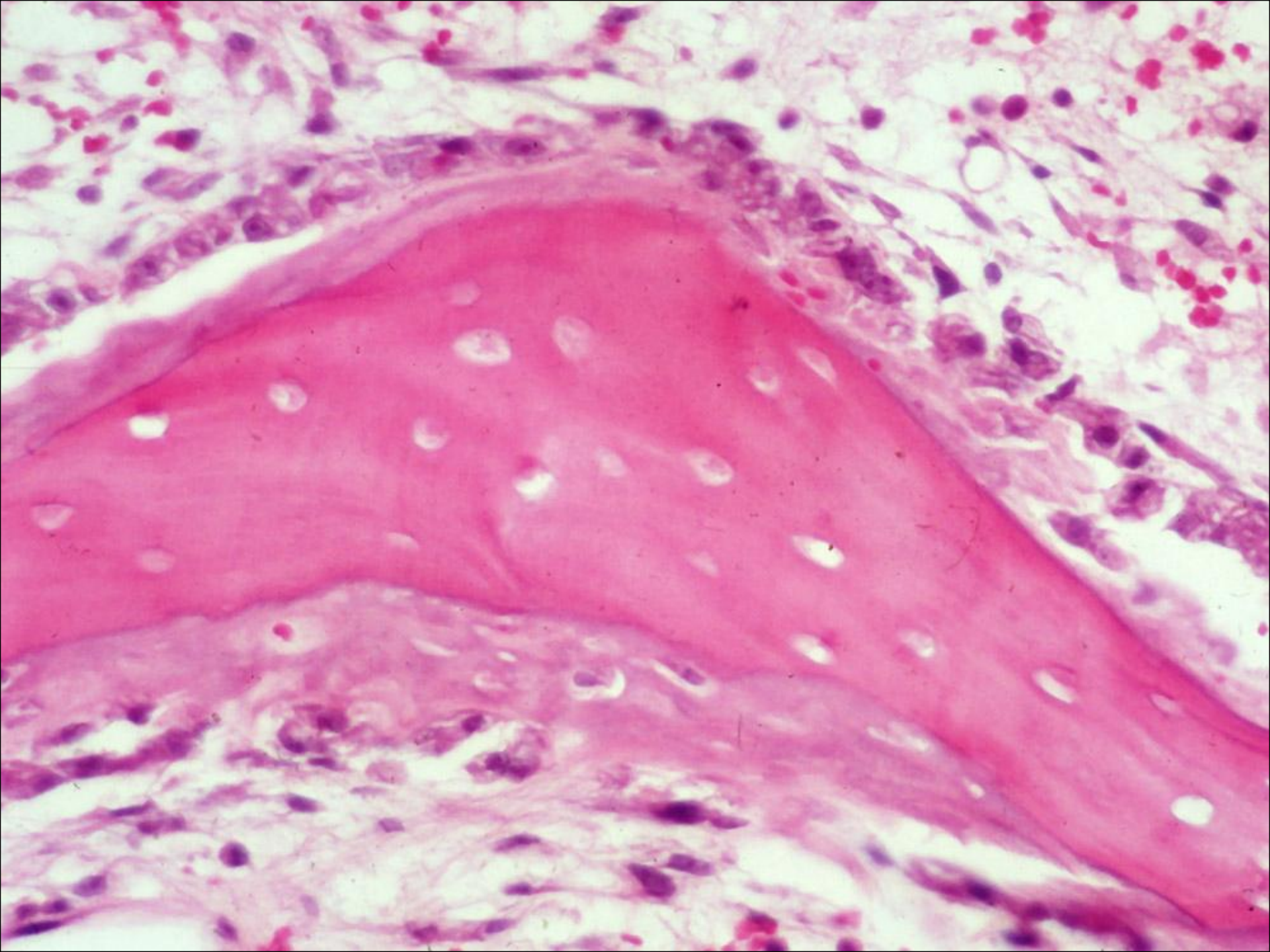


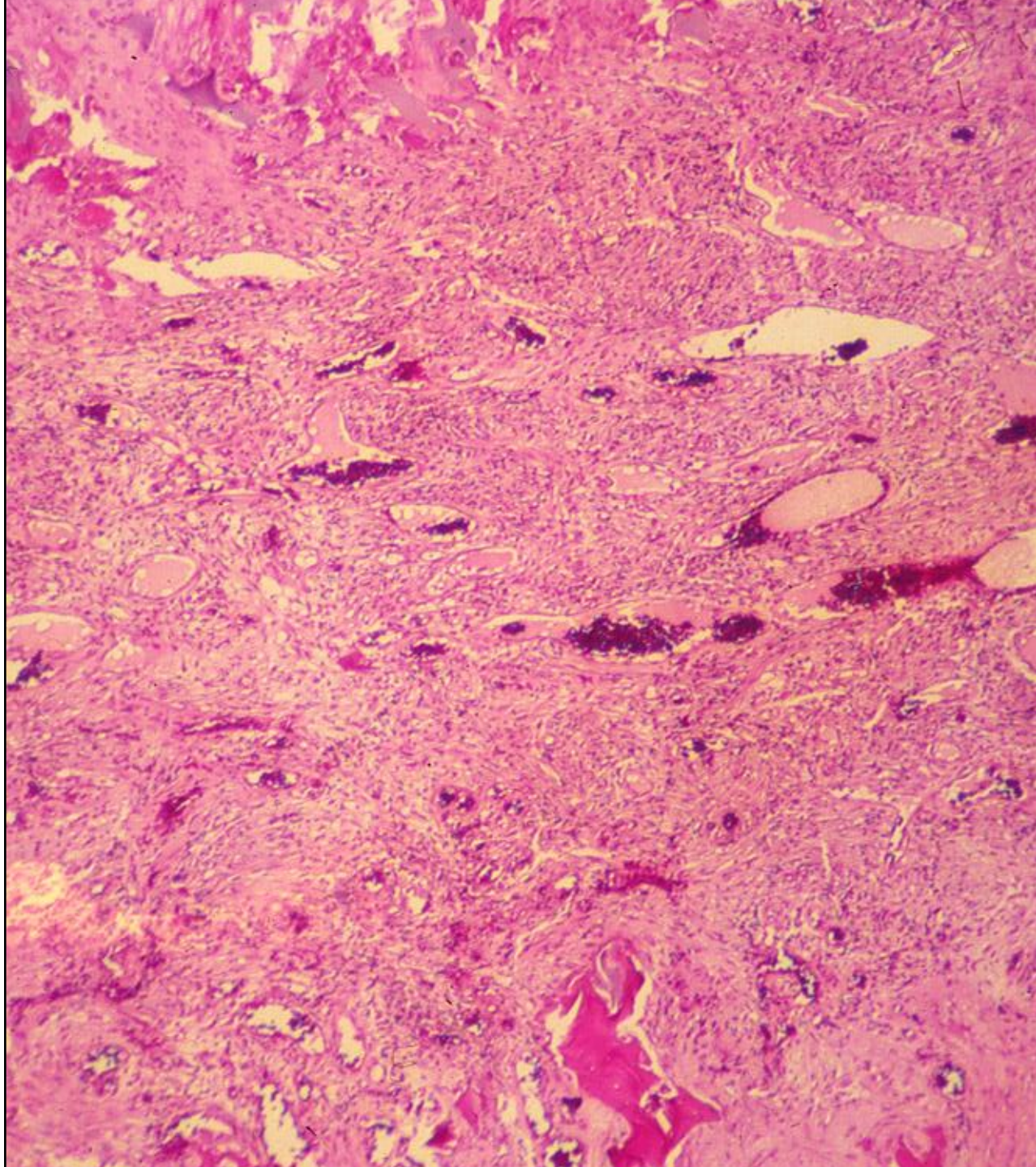




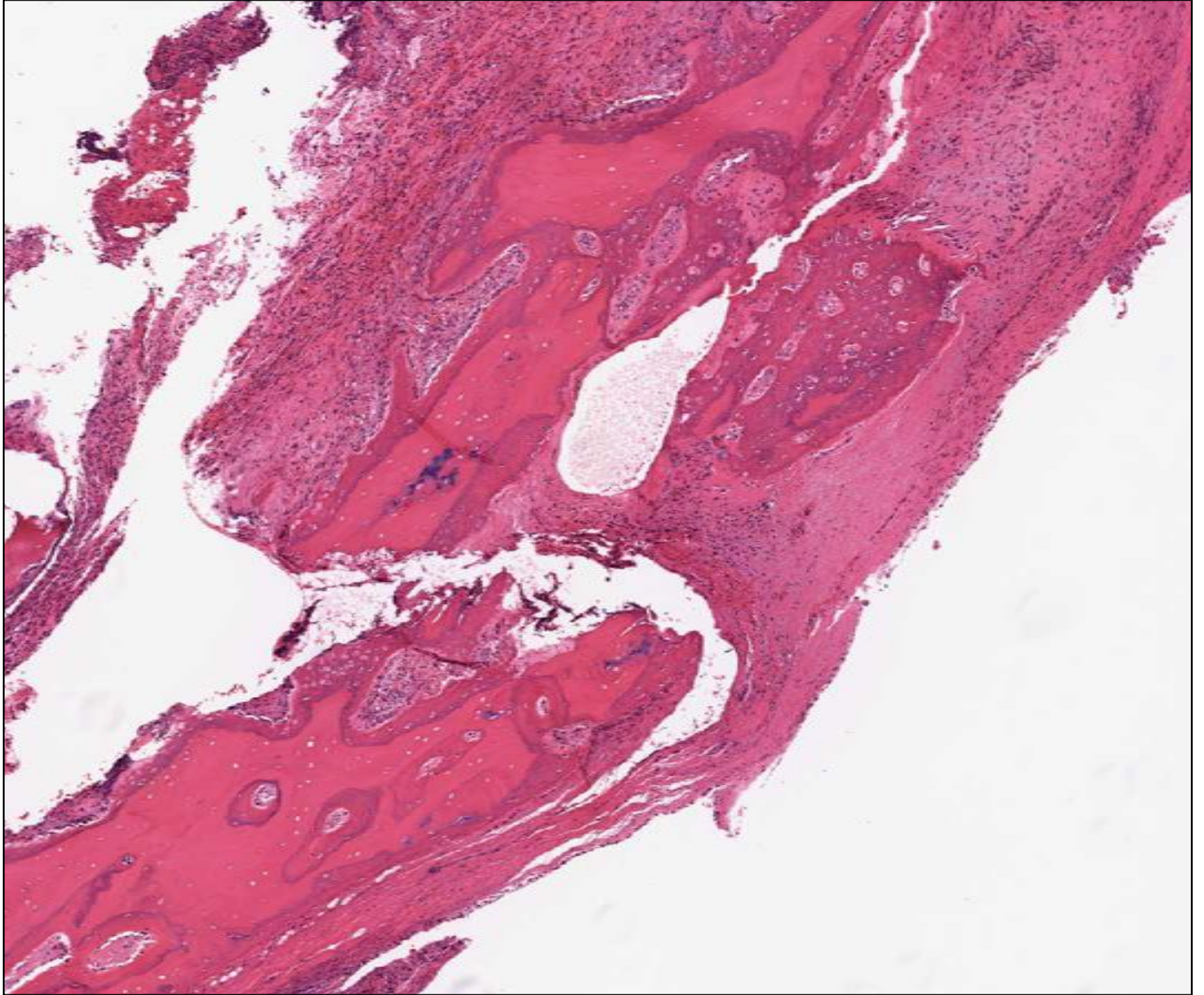


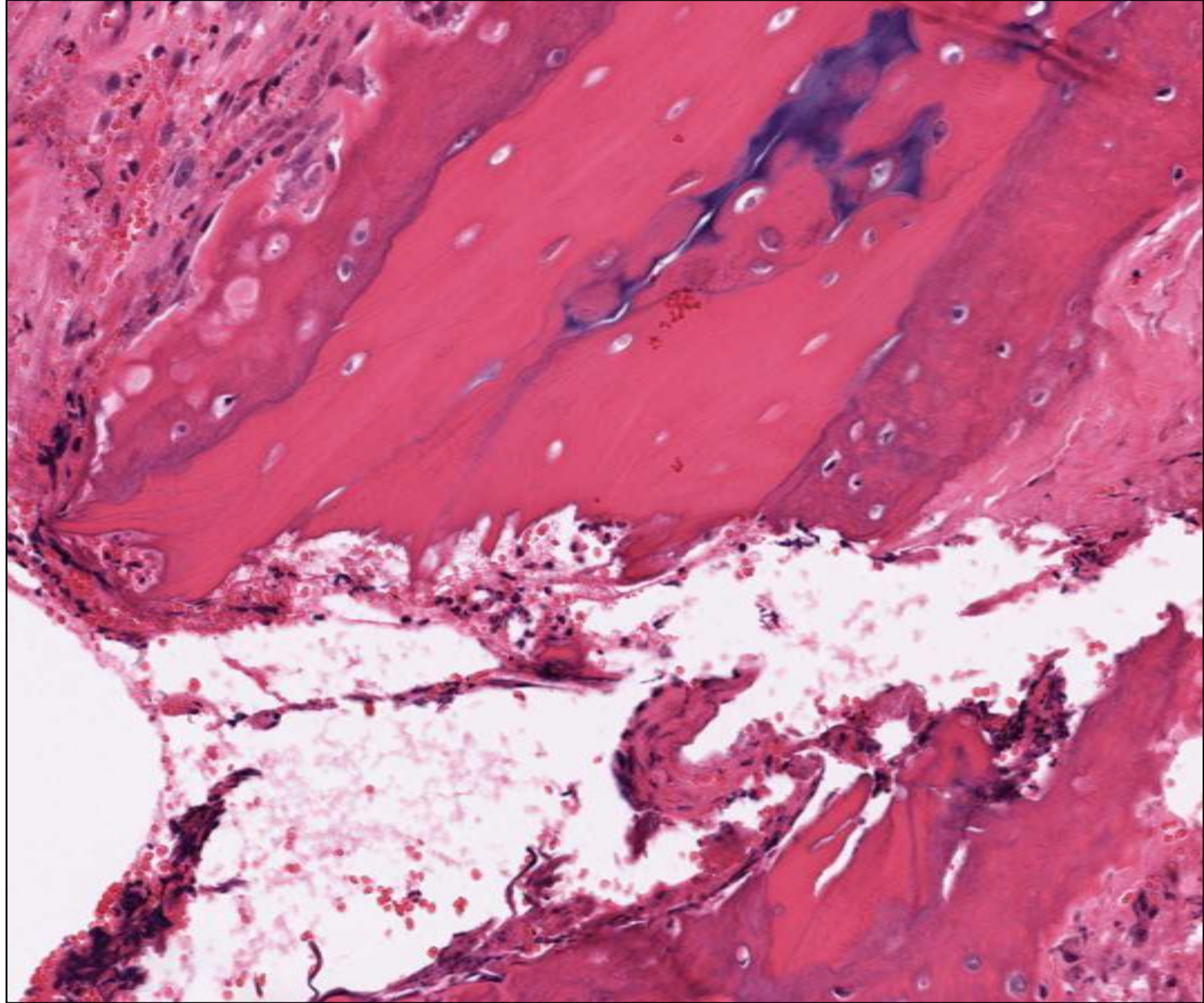






Ischemic Necrosis Secondary to Fracture





Sequestra usually are associated
with infectious inflammation

