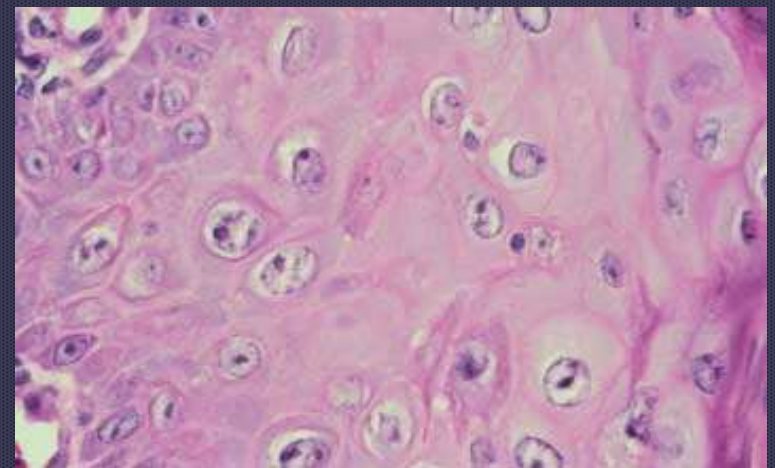
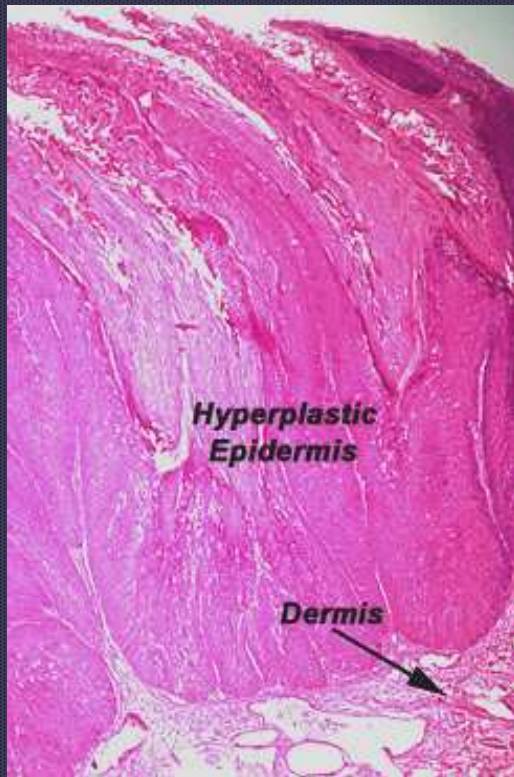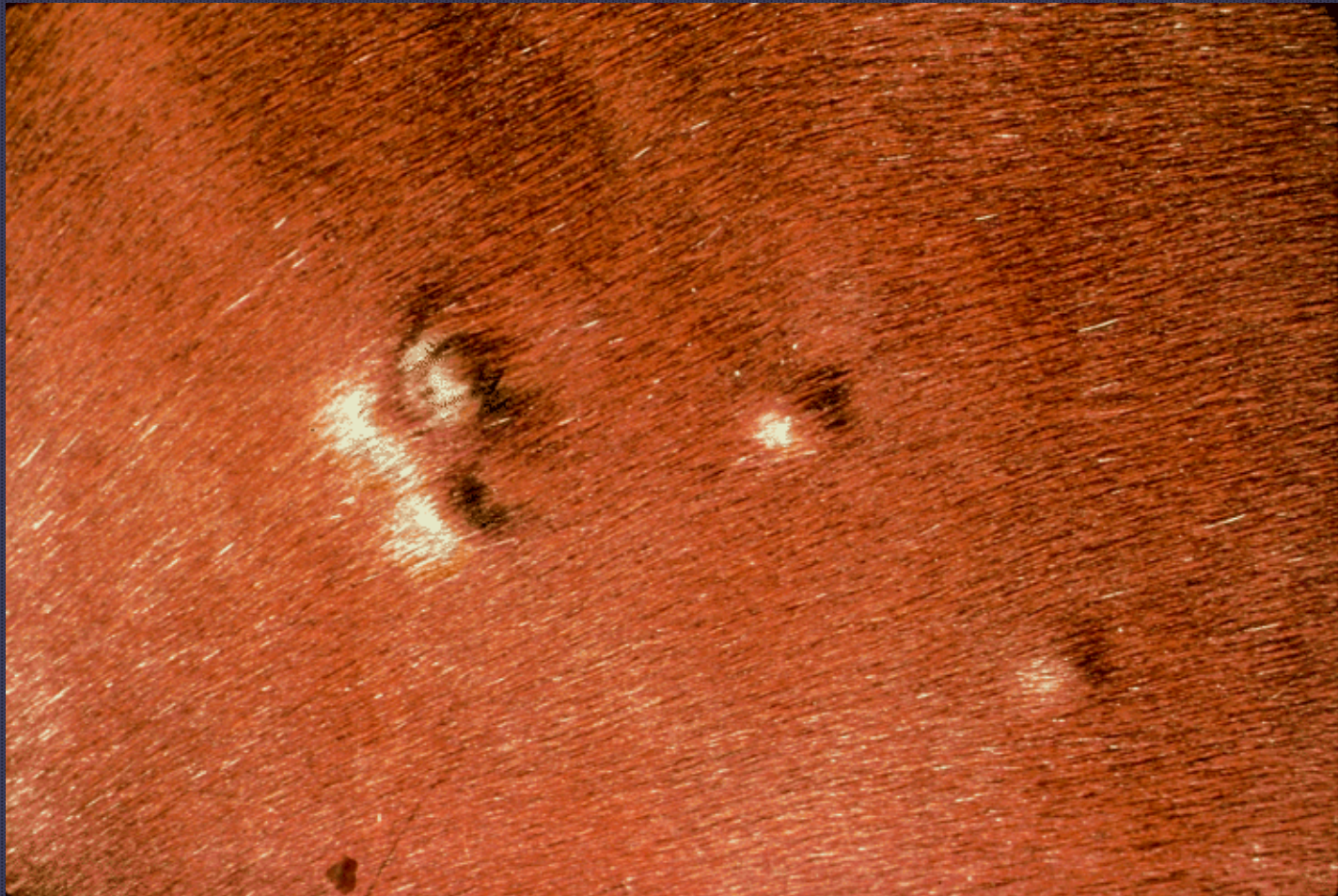


Papillomavirus infection

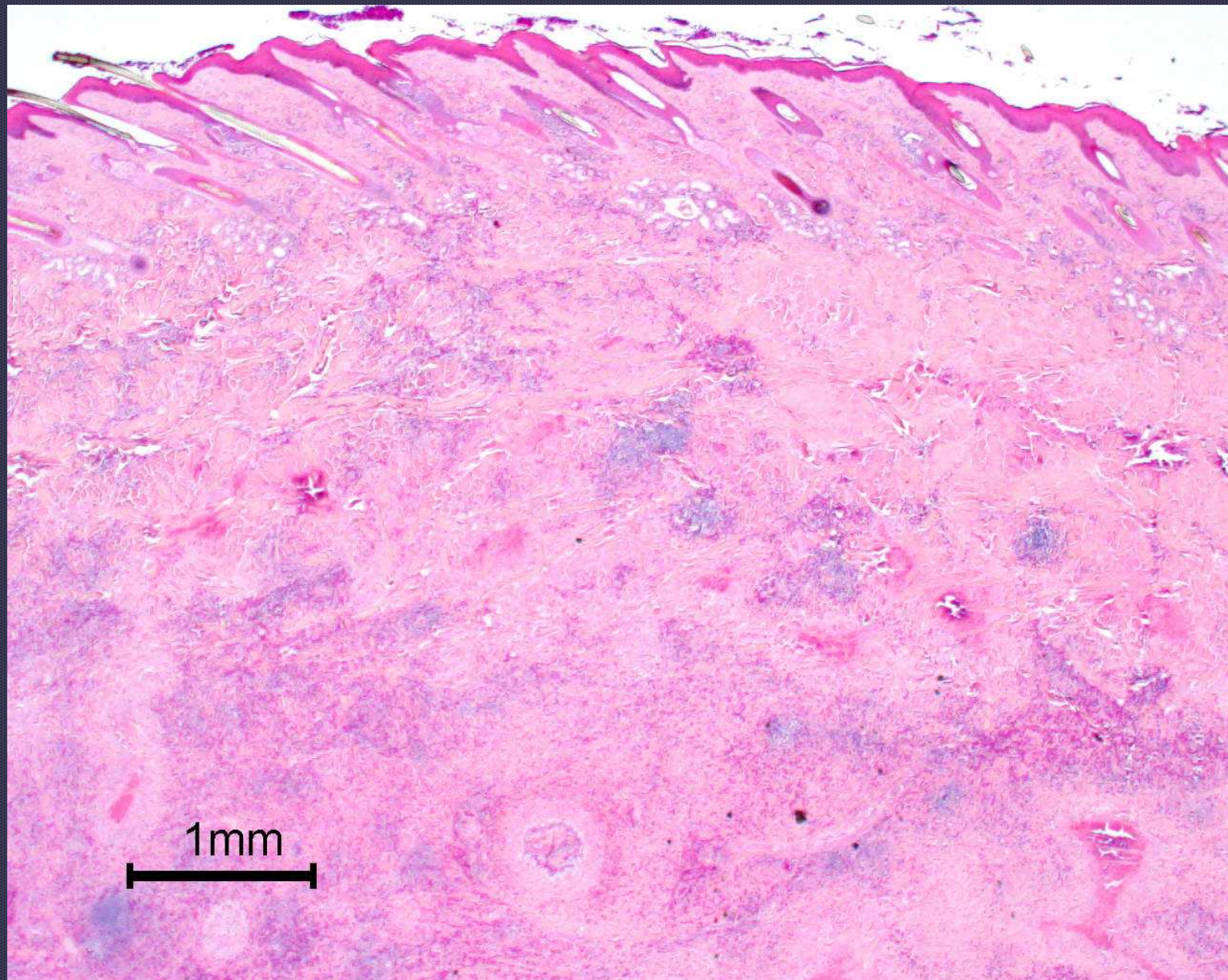


- **Postey, RC et. al. Evaluation of equine papillomas, aural plaques, and sarcoids for the presence of Equine papillomavirus DNA and Papillomavirus antigen, Can J Vet Res. 2007 Jan;71(1):28-33**

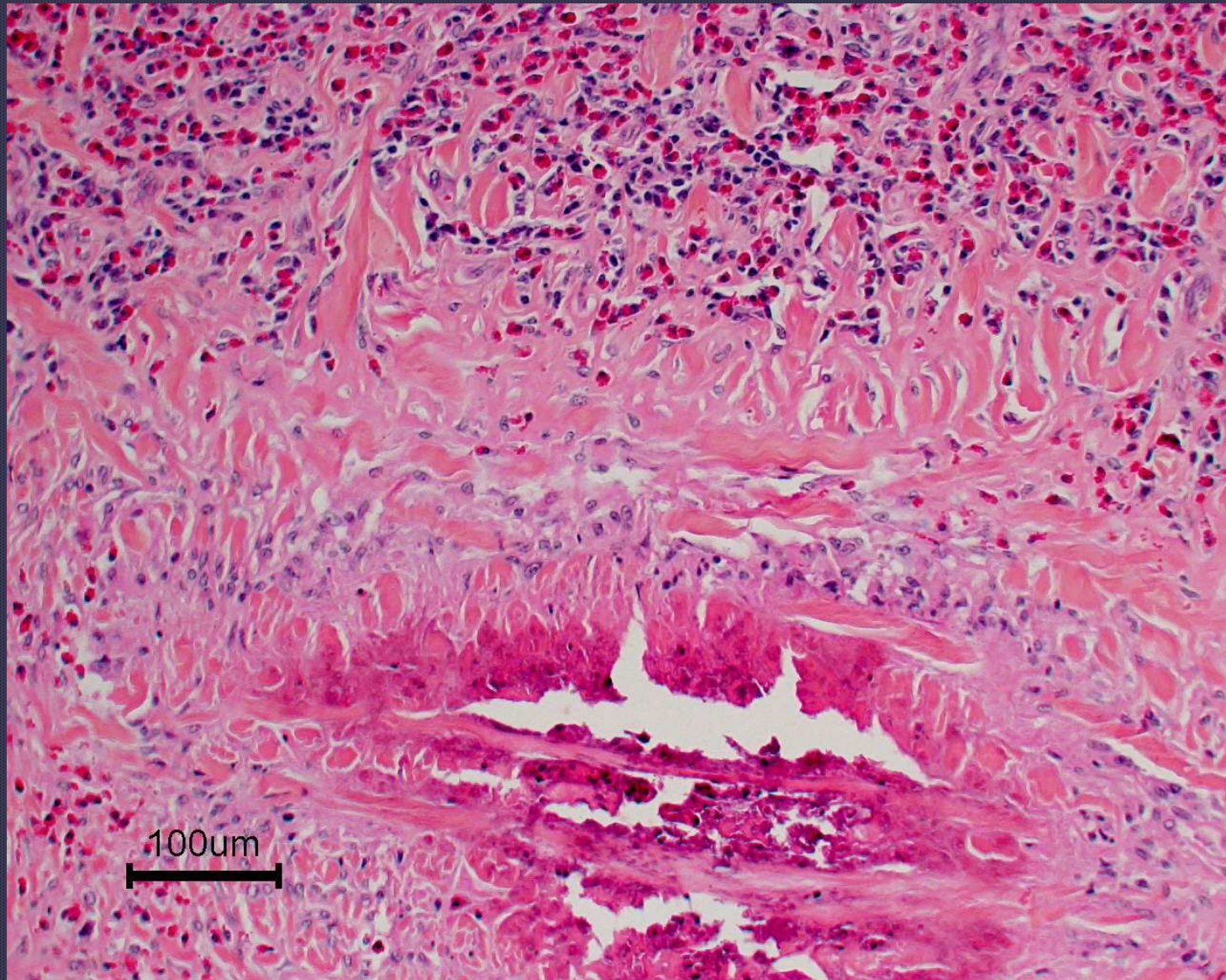


Eosinophilic granulomas

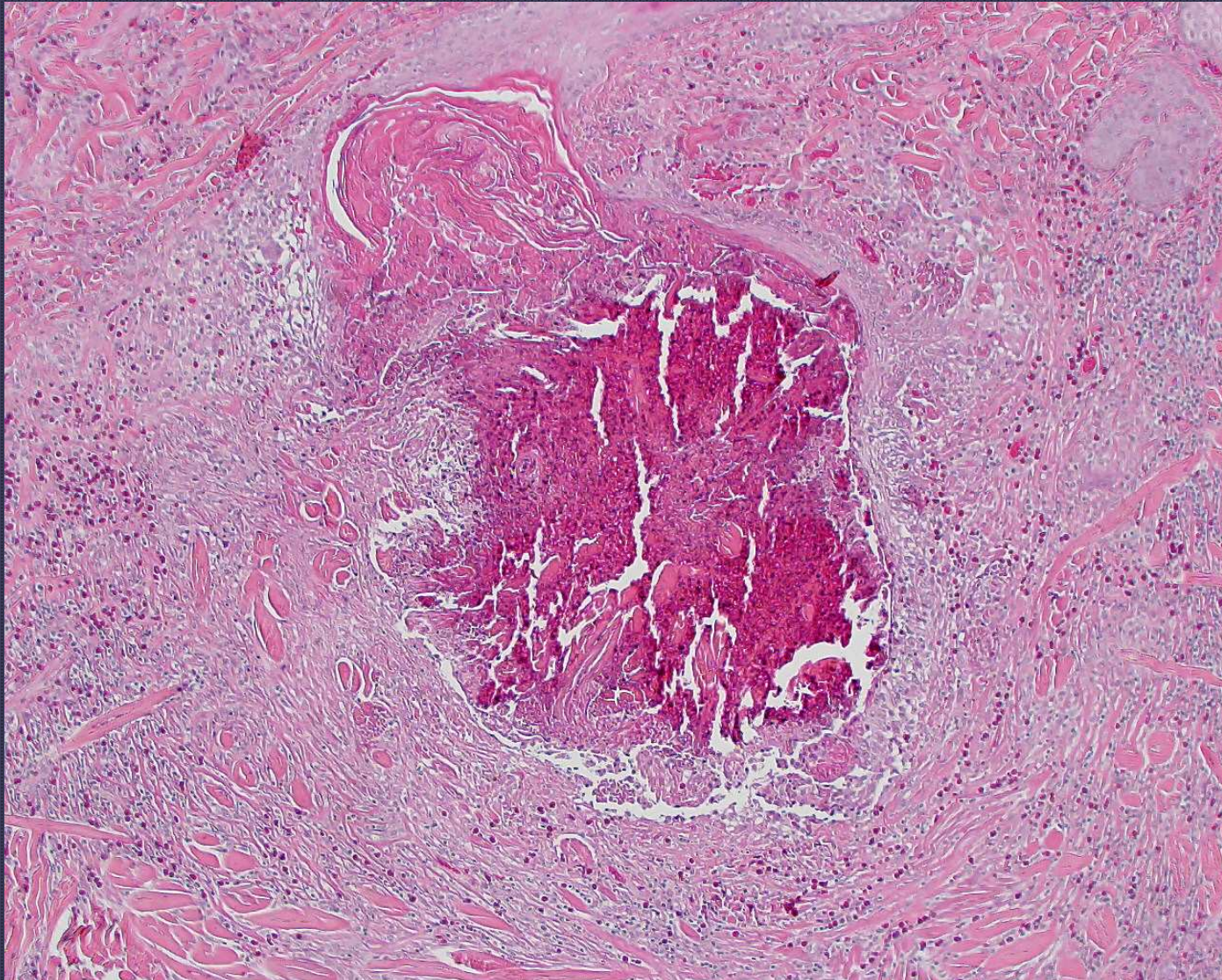
*Stannard's notes
Vet Derm Sept 2000*



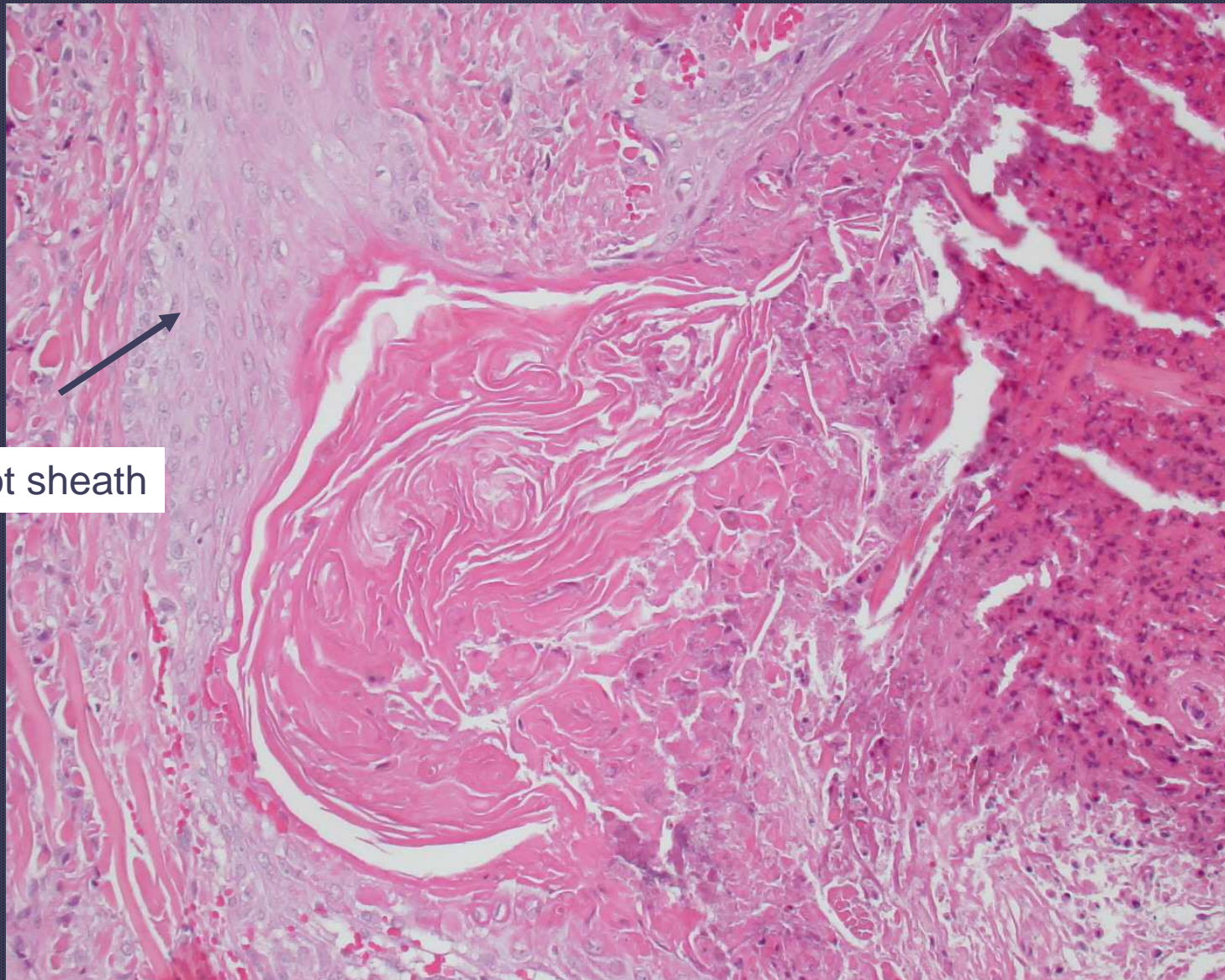
Eosinophilic granuloma



Collagen flame figures in eosinophilic granuloma



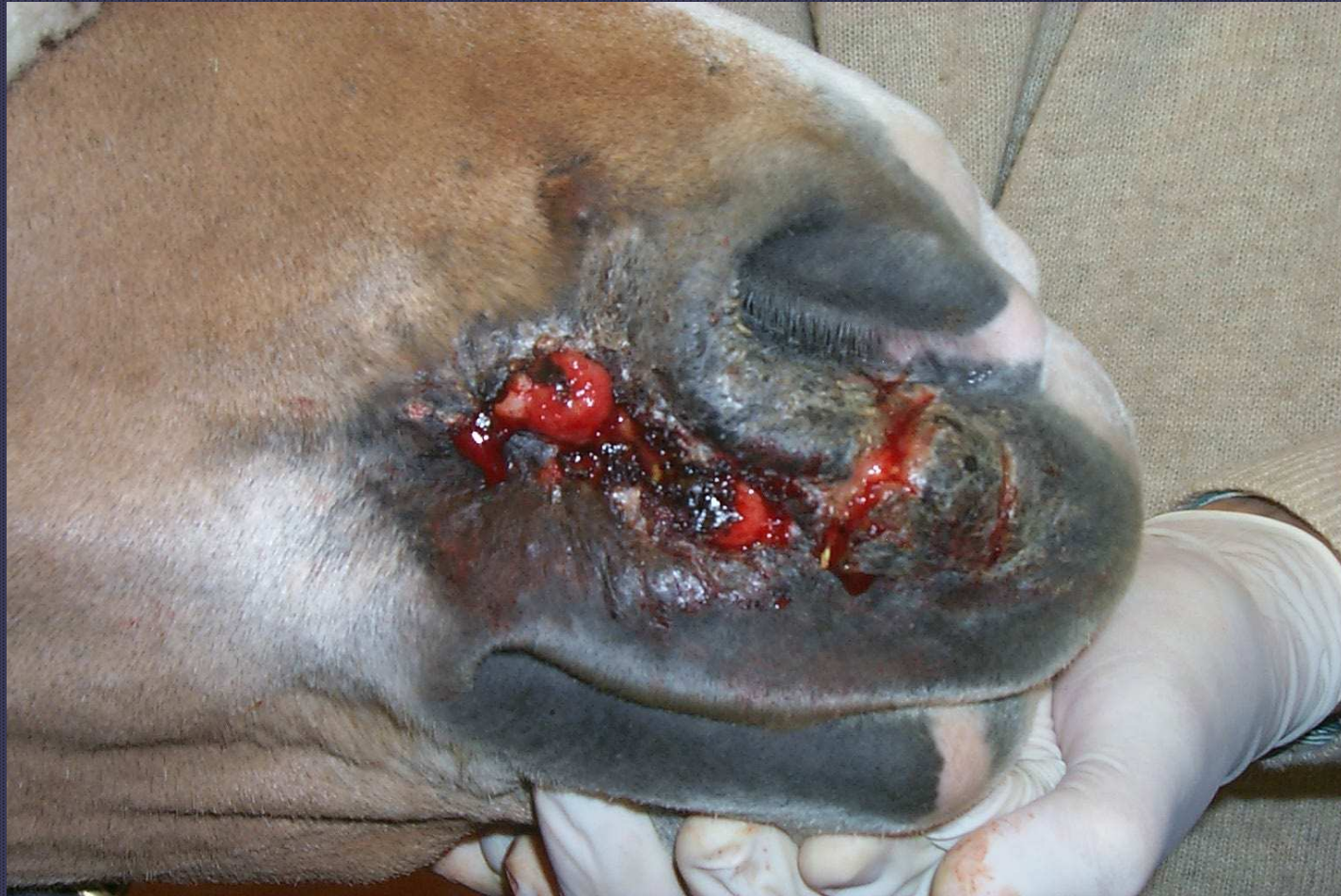This case shows transfollicular elimination of the collagen



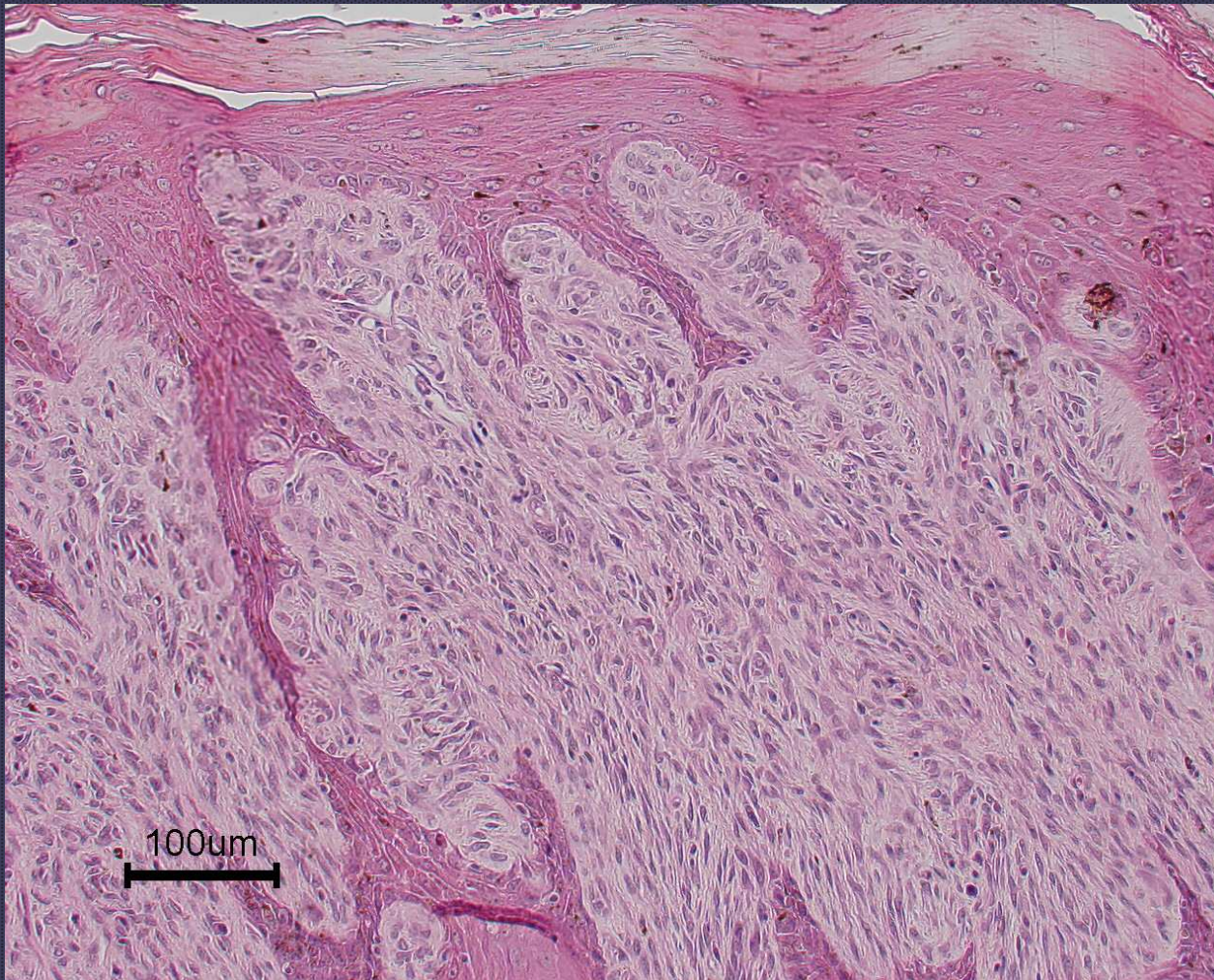
Outer root sheath

This case shows transfollicular elimination of the collagen

- *Slovis NM, Watson JL, Affolter VK. Injection site eosinophilic granulomas and collagenolysis in 3 horses. Journal of Veterinary Internal Medicine 1999; 13: 606-612.*



Sarcoid



Sarcoid