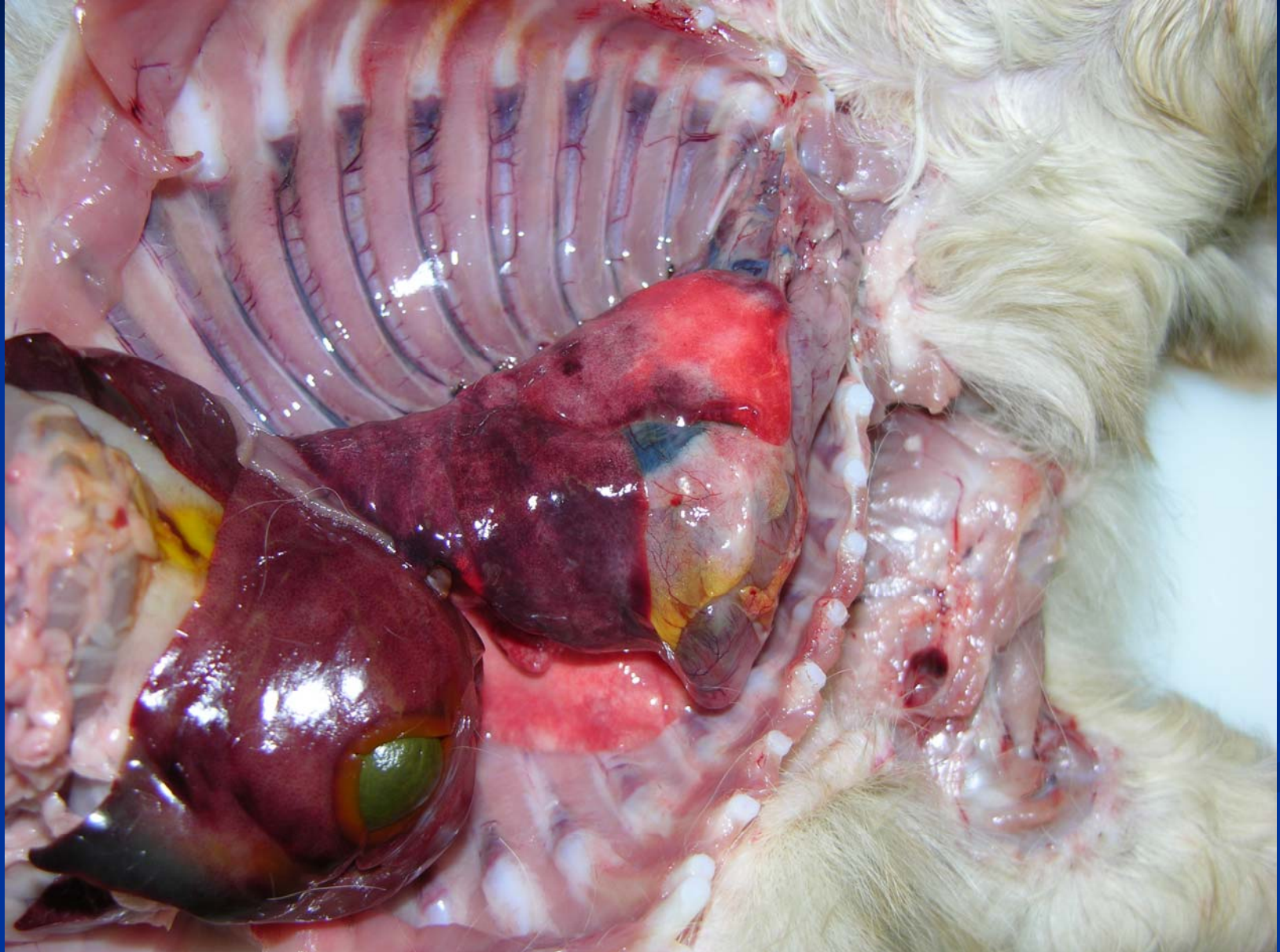


# *Streptococcus* sp. - Puppy



# Infectious Pneumonias of Cats

- Uncommon in cats except with immunosuppression or following aspiration
- Viral
- Bacterial
  - *Chlamydophila felis* - generally mild
  - *Mycoplasma felis*
  - Occasional secondary infections
    - *Pasteurella* spp
    - *Bordetella bronchiseptica*

# Other Infectious Pneumonias in Cats

## ■ Mycotic

- *Cryptococcus neoformans*, *C. gatti*
- *Histoplasma capsulatum*

## ■ Protozoal

- *Toxoplasma gondii*
- *Cytauxzoon felis* (USA only)

## ■ Other parasitic

# Mycotic Pneumonia

- Immune compromised individuals
  - Malnutrition
  - Corticosteroid treatment
  - Cats with FIV, FLV
- Lesions
  - Multifocal granulomas to pyogranulomatous pneumonia
  - Other organs may be affected

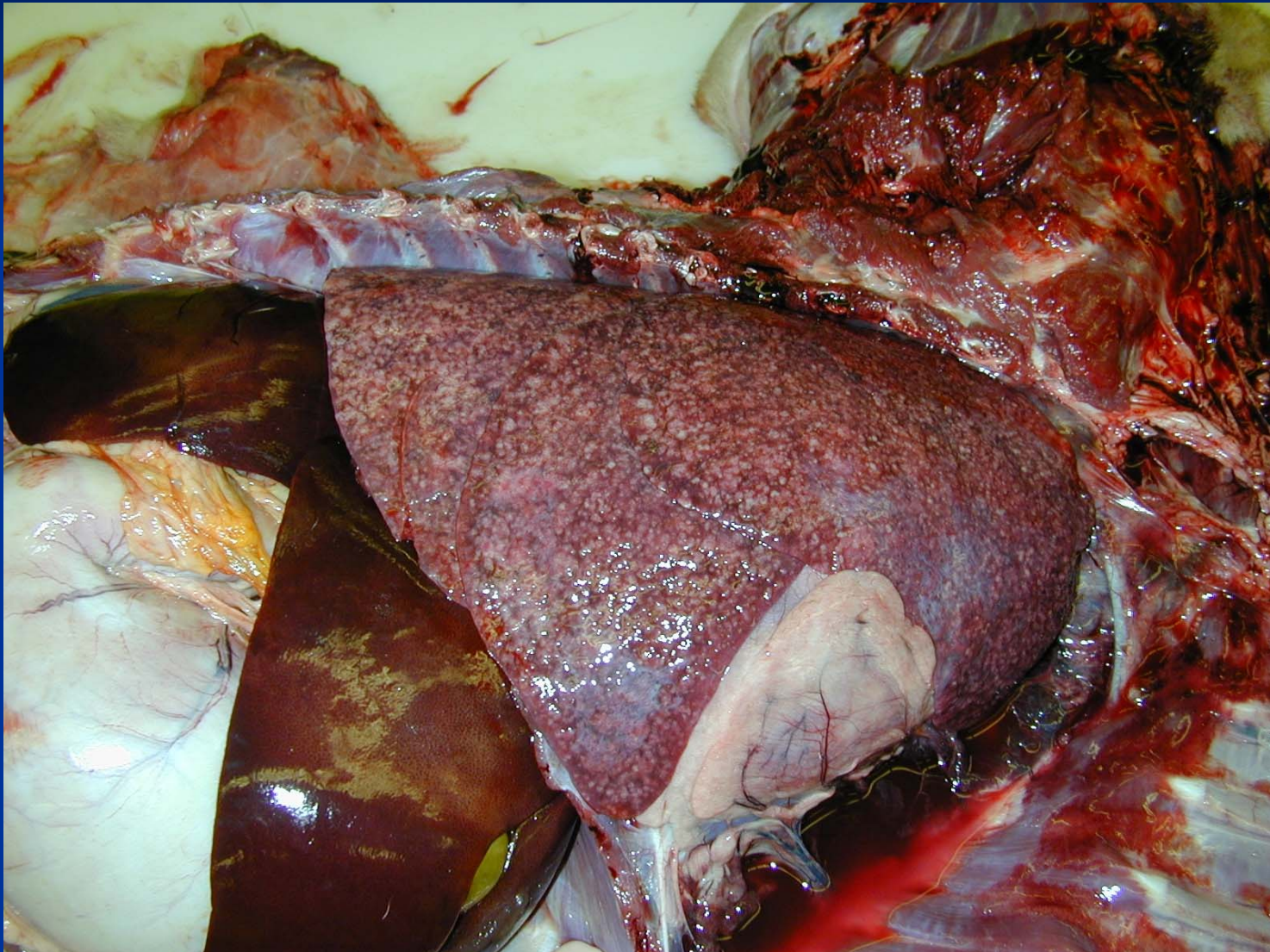# Mycotic Pneumonias of Dogs and Cats

- Etiologic agents
  - *Histoplasma capsulatum*
  - *Cryptococcus neoformans*, *C. gatti*
  - *Aspergillus spp.*
  - *Pneumocystis carinii*
  - *Blastomycosis dermatiditis*
  - *Coccidioides immitis*

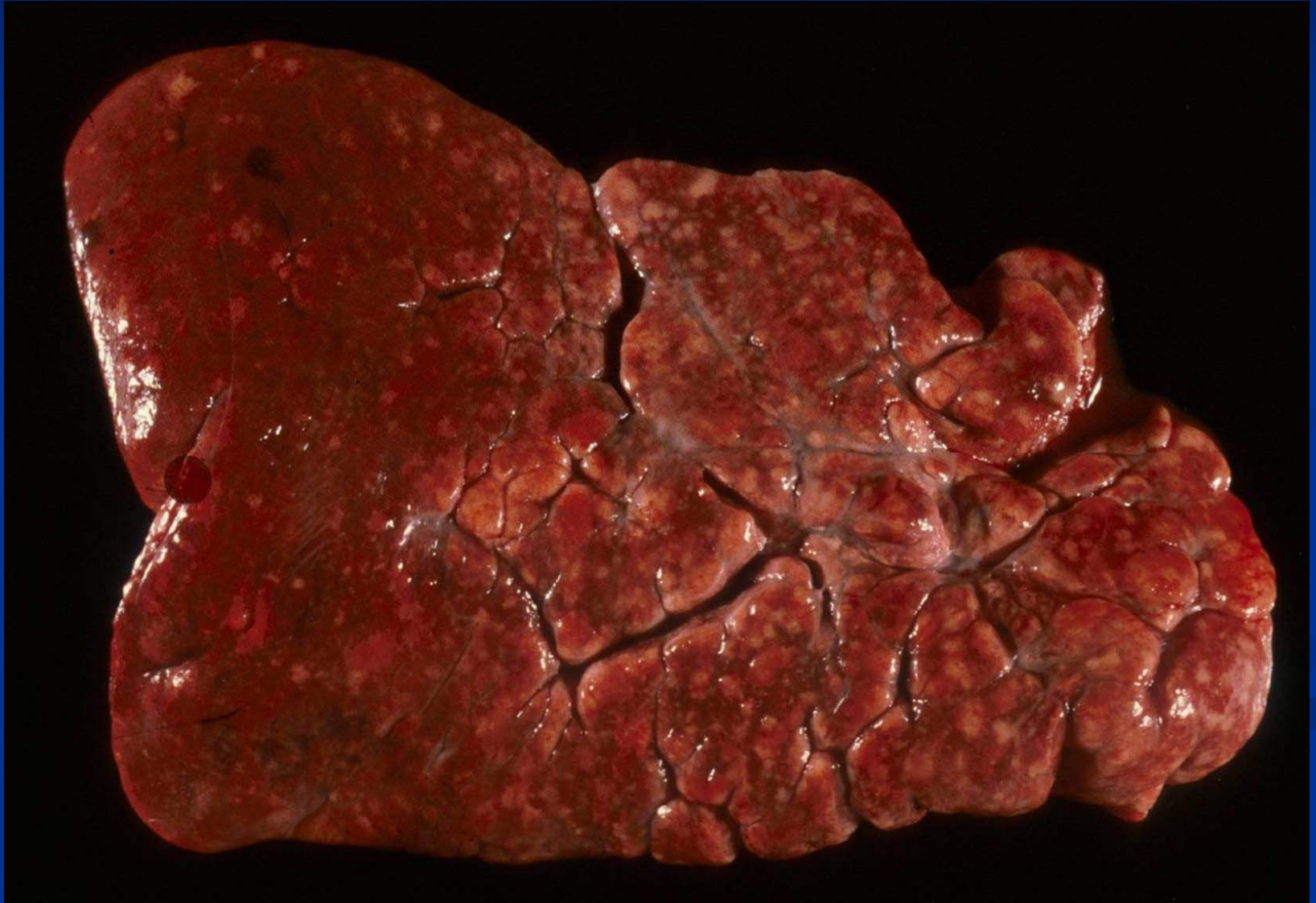
# Blastomycosis

- Geographical distribution: Missouri valley in USA
- Common in dogs but rare in cats
- Disease
  - Pulmonary
  - Cutaneous
  - Disseminated
- Pyogranulomatous response

# Blastomycosis

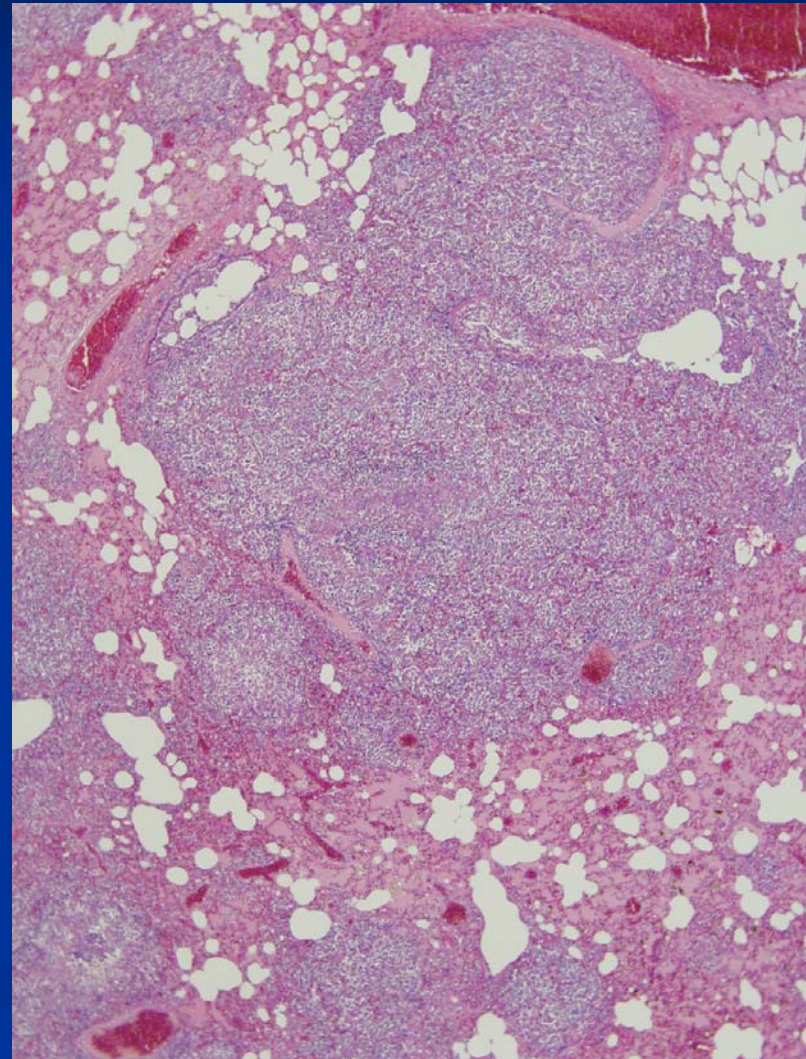
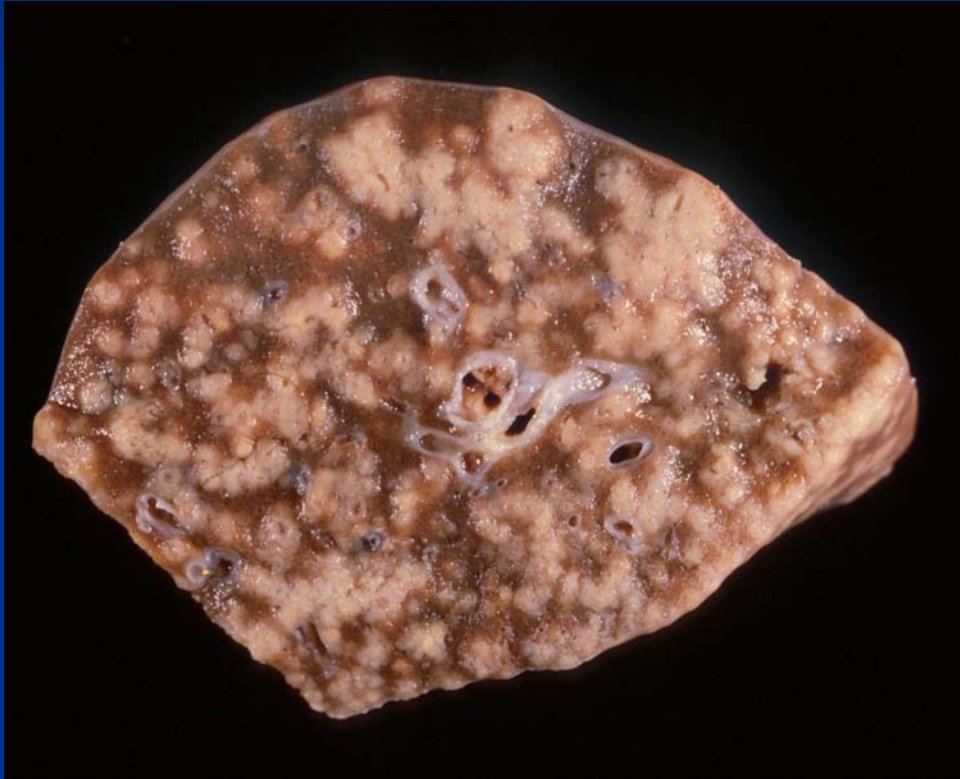


# Blastomycosis - Dog





# Blastomycosis



# Blastomycosis —Rottweiler

