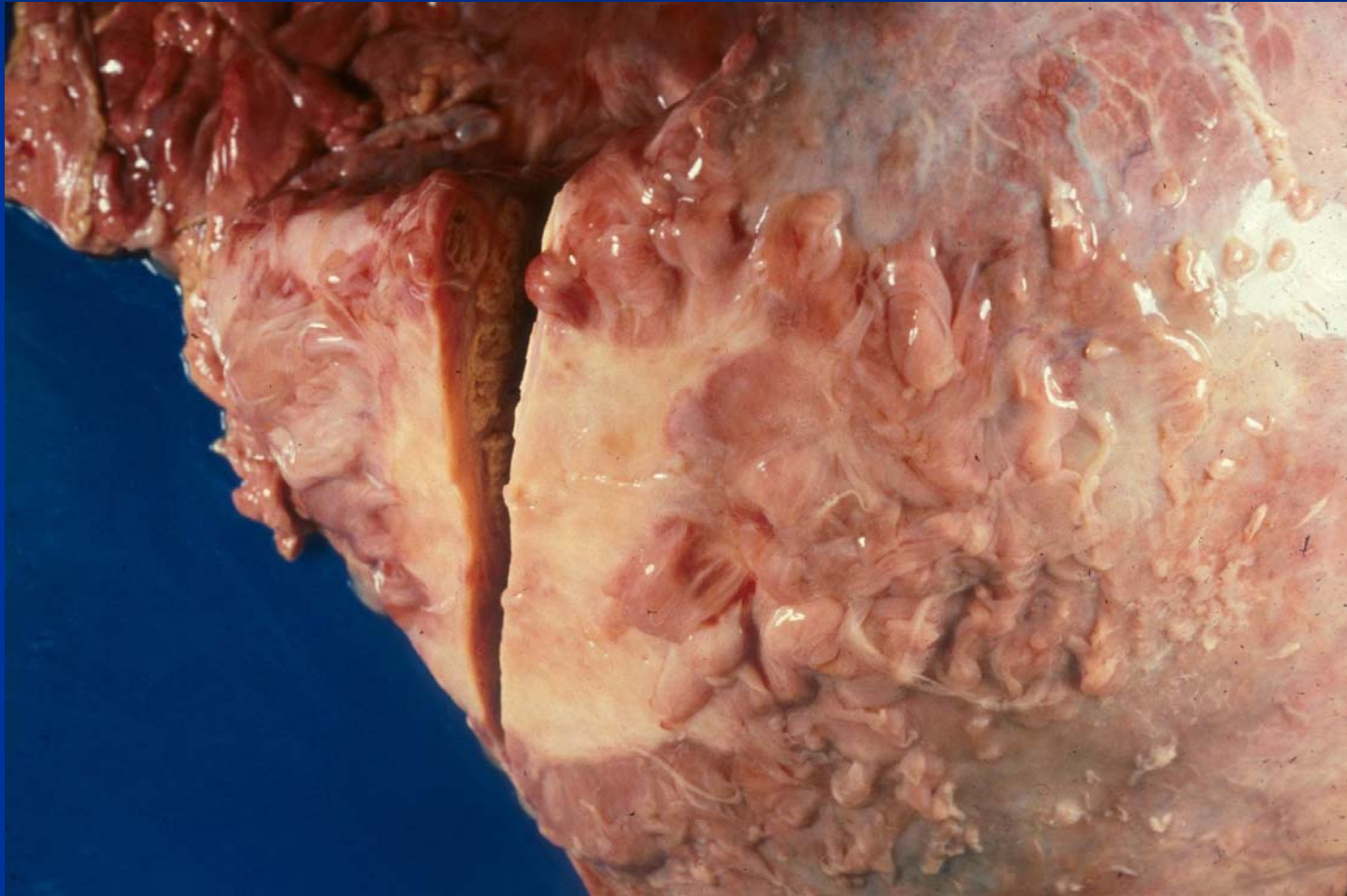

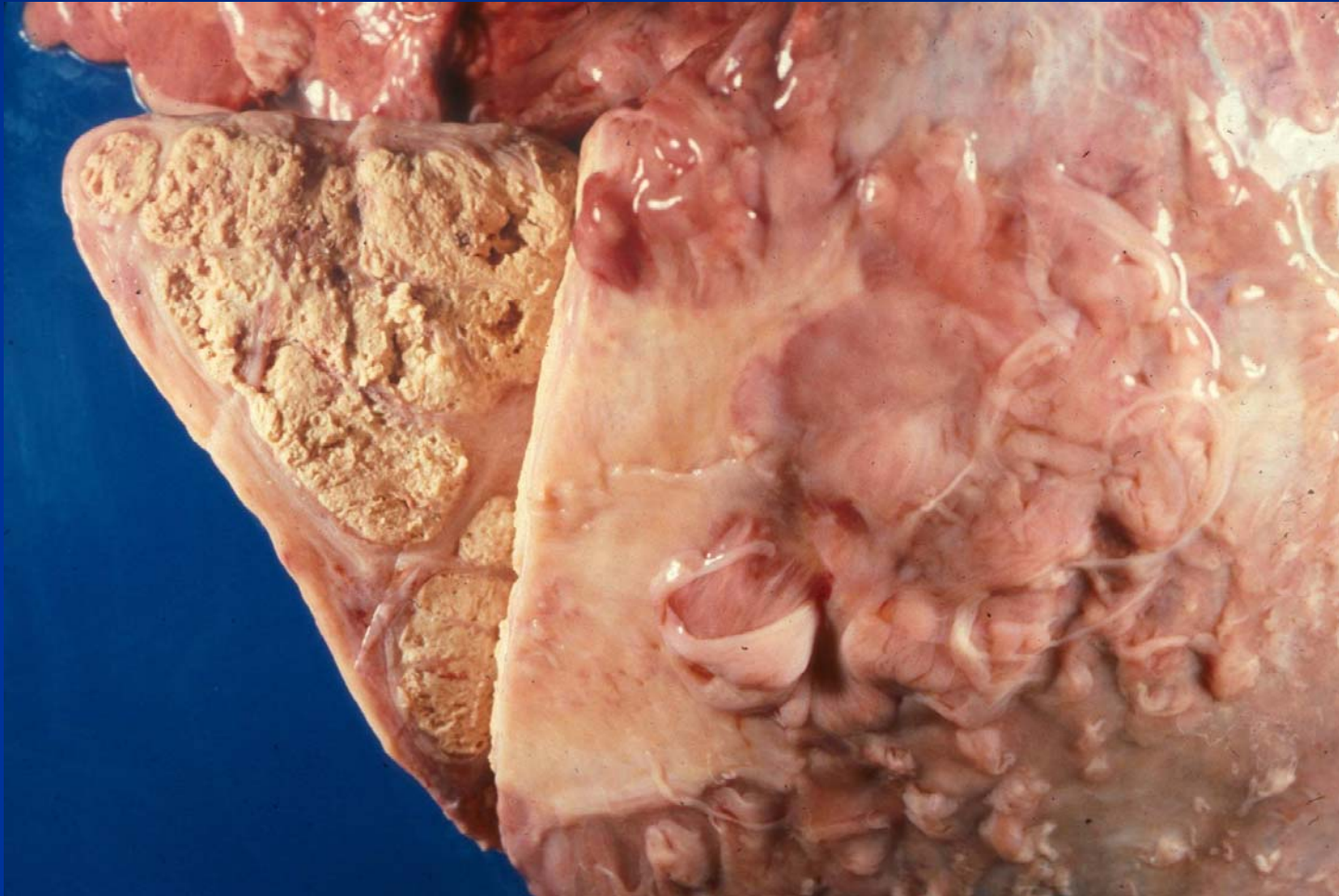
# Mycobacteriosis

Pulmonary granuloma with chronic pleuritis



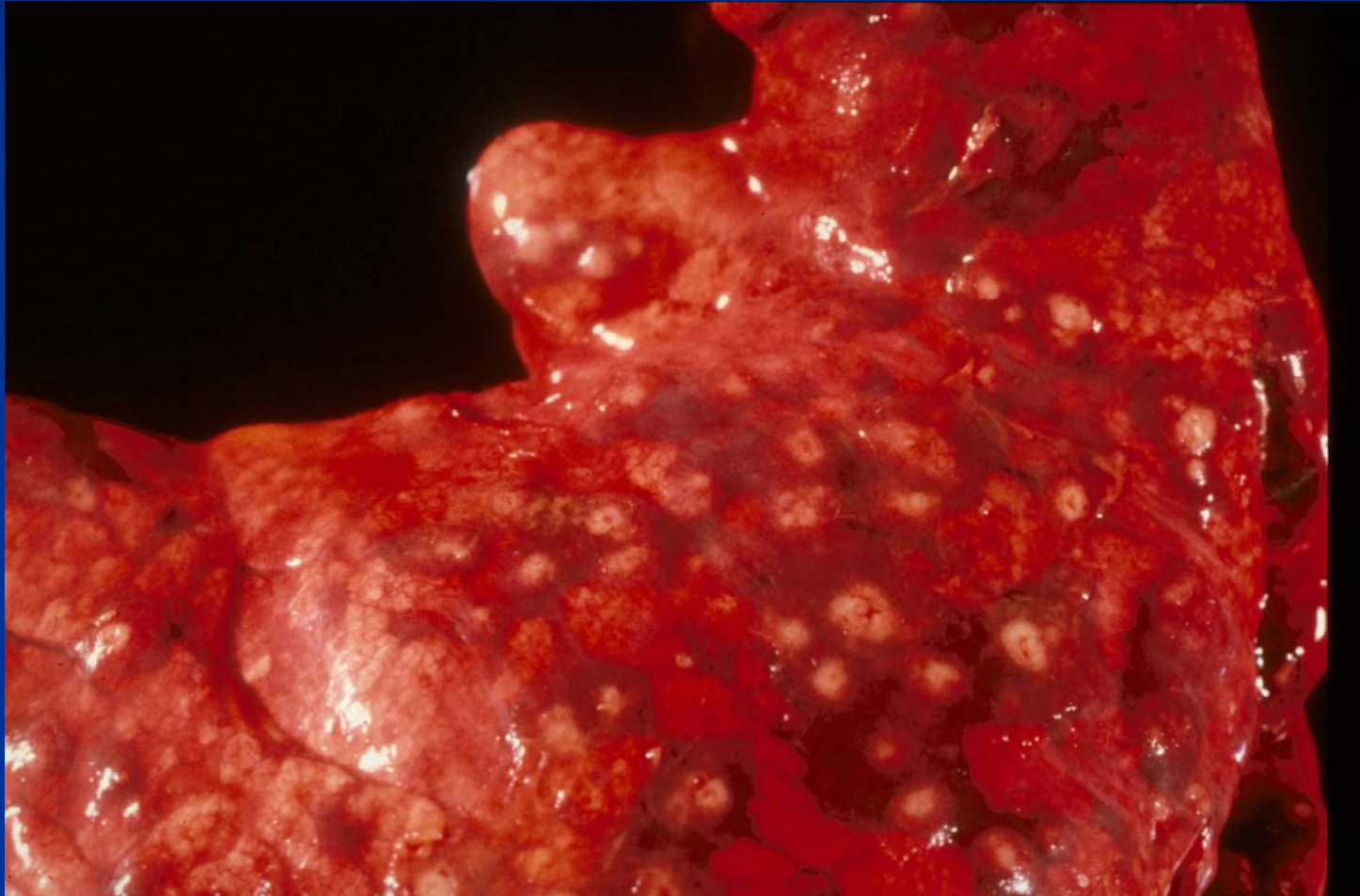
# Mycobacteriosis

Pulmonary granuloma with chronic pleuritis



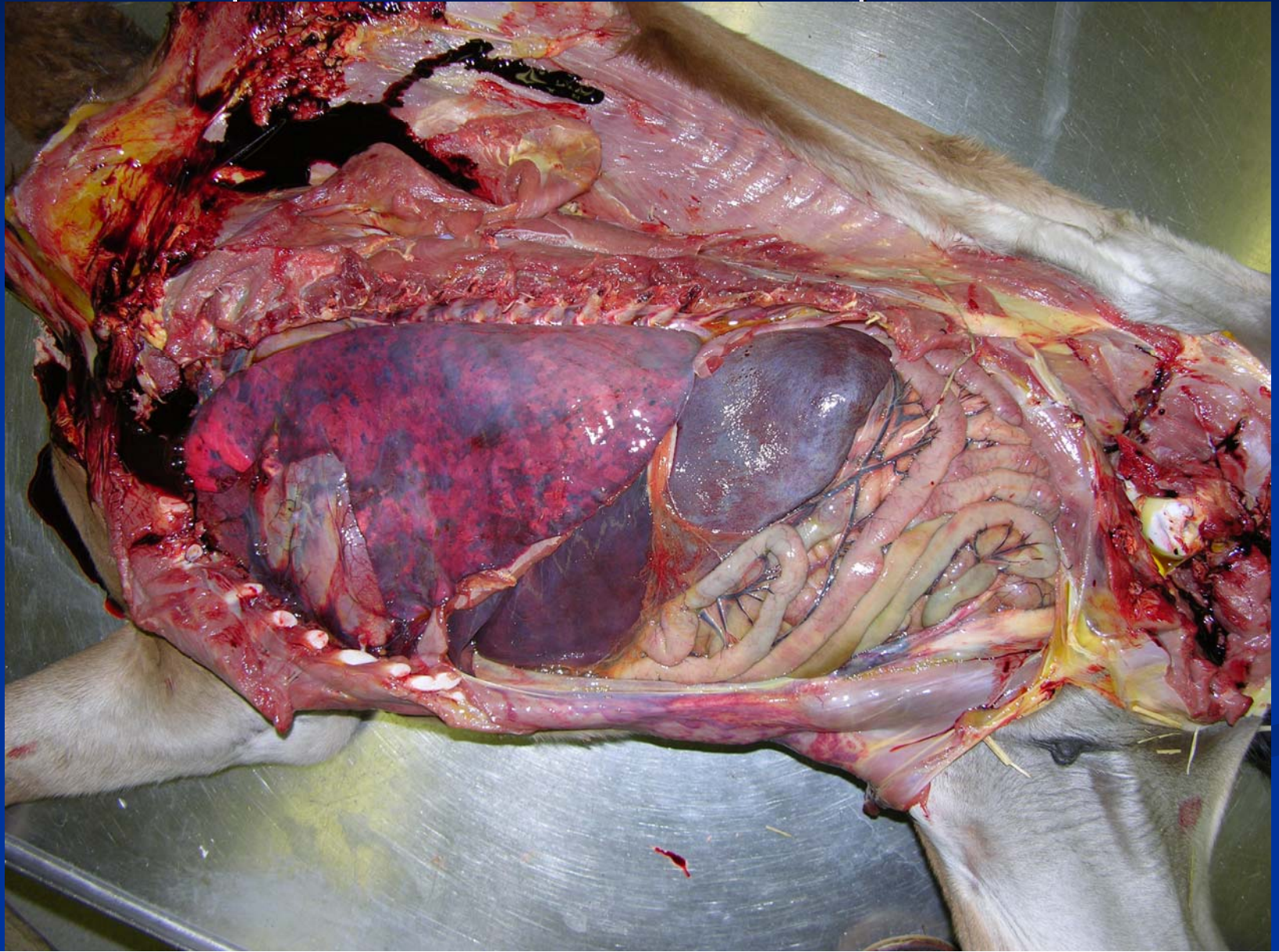
# Embolic Pneumonia

Multiple abscesses

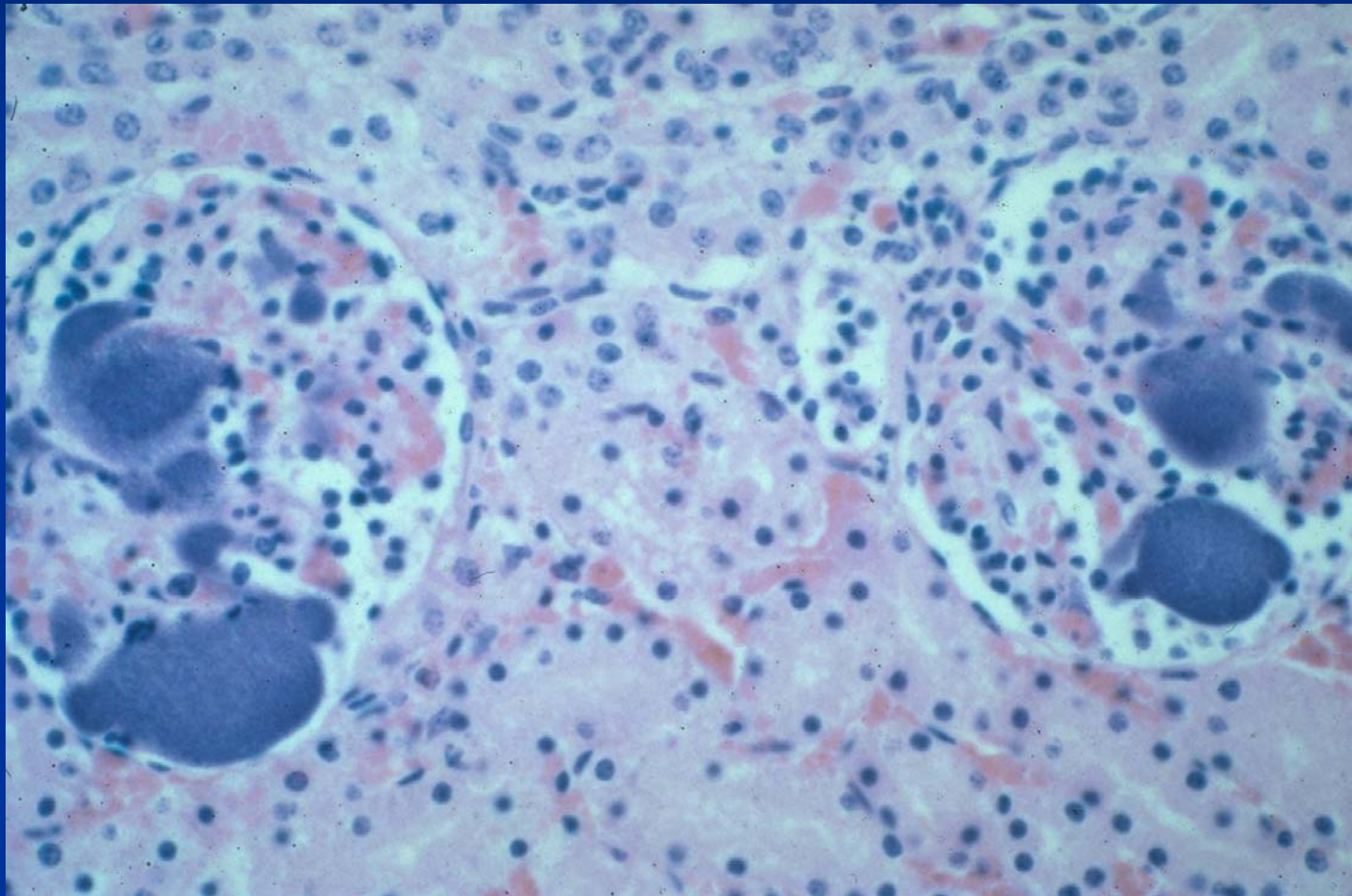


# *Actinobacillus* sp. – Foal

Multiple abscesses – embolic pneumonia



*Actinobacillus sp*—Foal Kidney  
Embolic shower to glomeruli



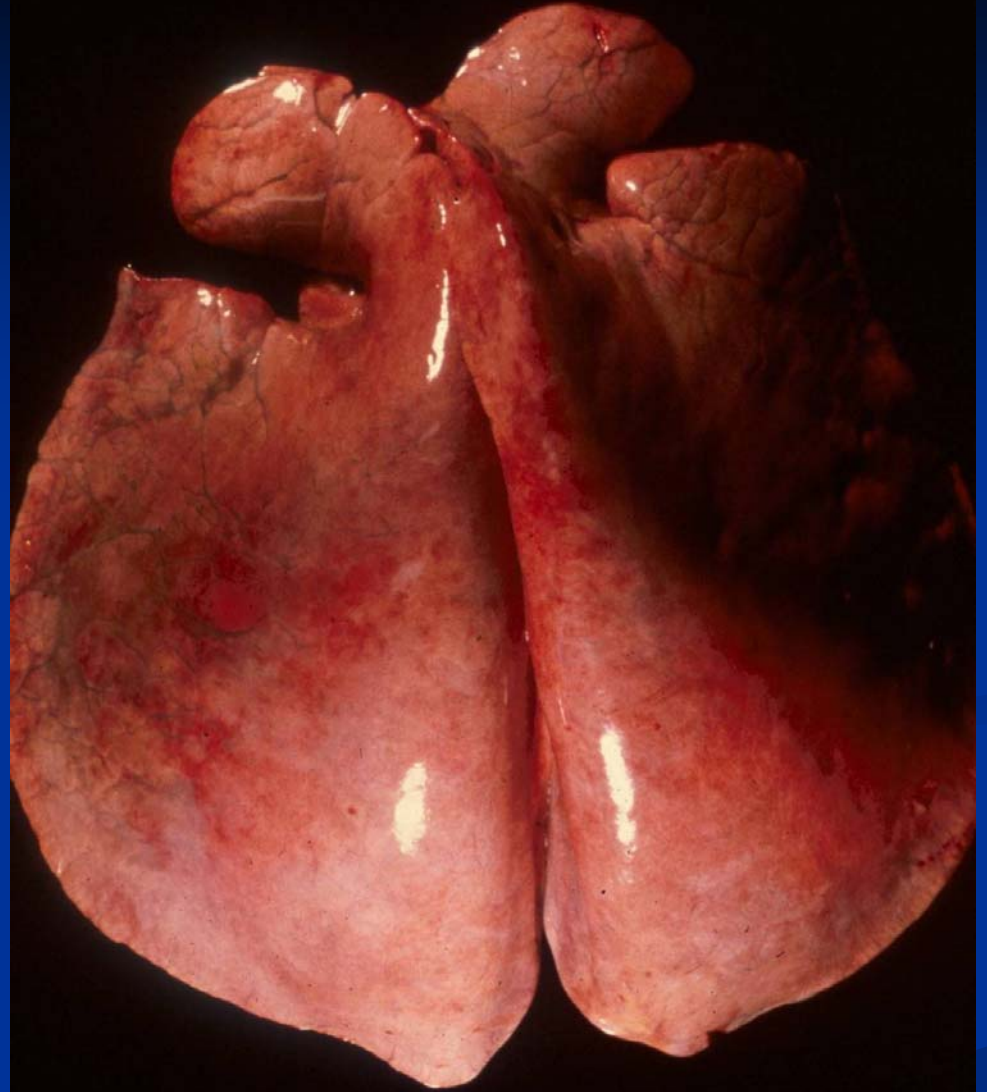
# Mycotic Pneumonia

- Pneumocystosis
  - *Pneumocystis carinii* (GMS stain)
  - Immunosuppressed, such as CID foals, often with adenovirus
  - Organisms pack alveoli with foamy appearance
- *Cryptococcus neoformans* (mucicarmine stain)

# Pneumocystosis

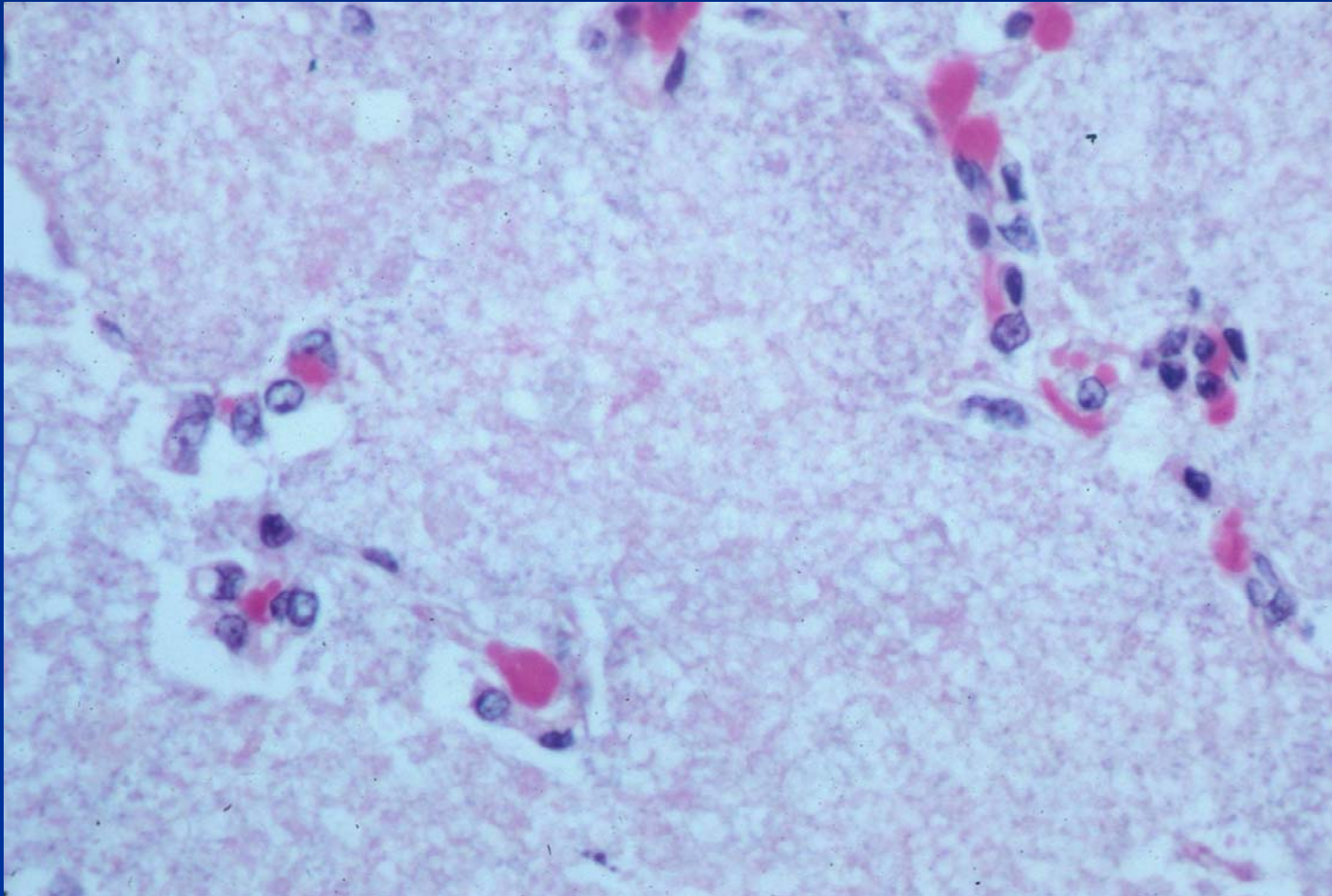
## – Arabian Foal

Interstitial pneumonia



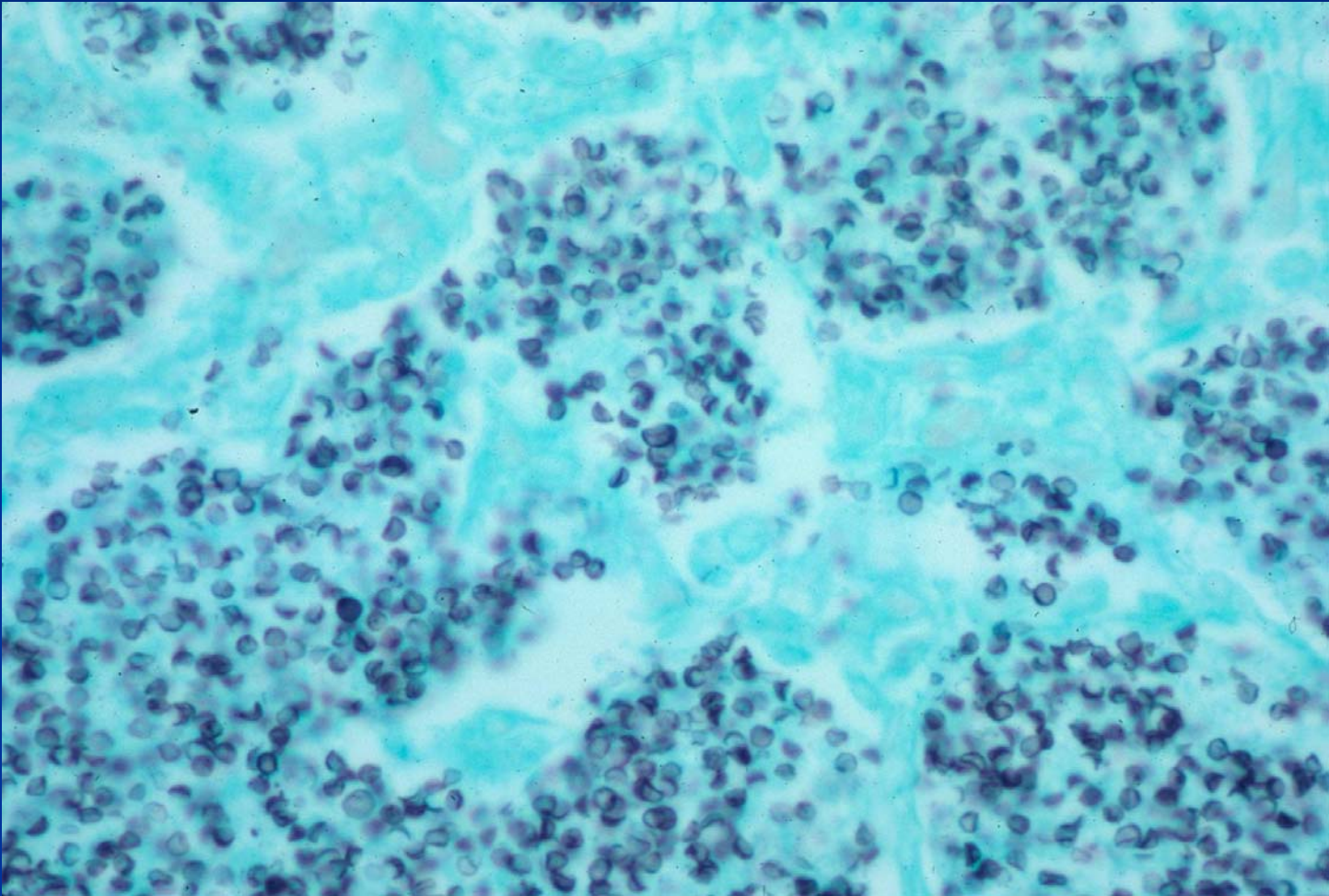
# Pneumocystosis

Granular material in alveoli





# Pneumocystosis Silver Stain (GMS)



# Parasitic Pneumonia

- *Parascarus equorum*
  - Larvae migrate causing necrosis
  - Dead larvae induce granulomas
  - Associated eosinophils
  
- *Dictyocaulus arnfeldi*
  - Donkeys are natural hosts
  - Non-febrile coughing horse
  - Dorsocaudal lung
  - Eosinophilic bronchitis, focal atelectasis