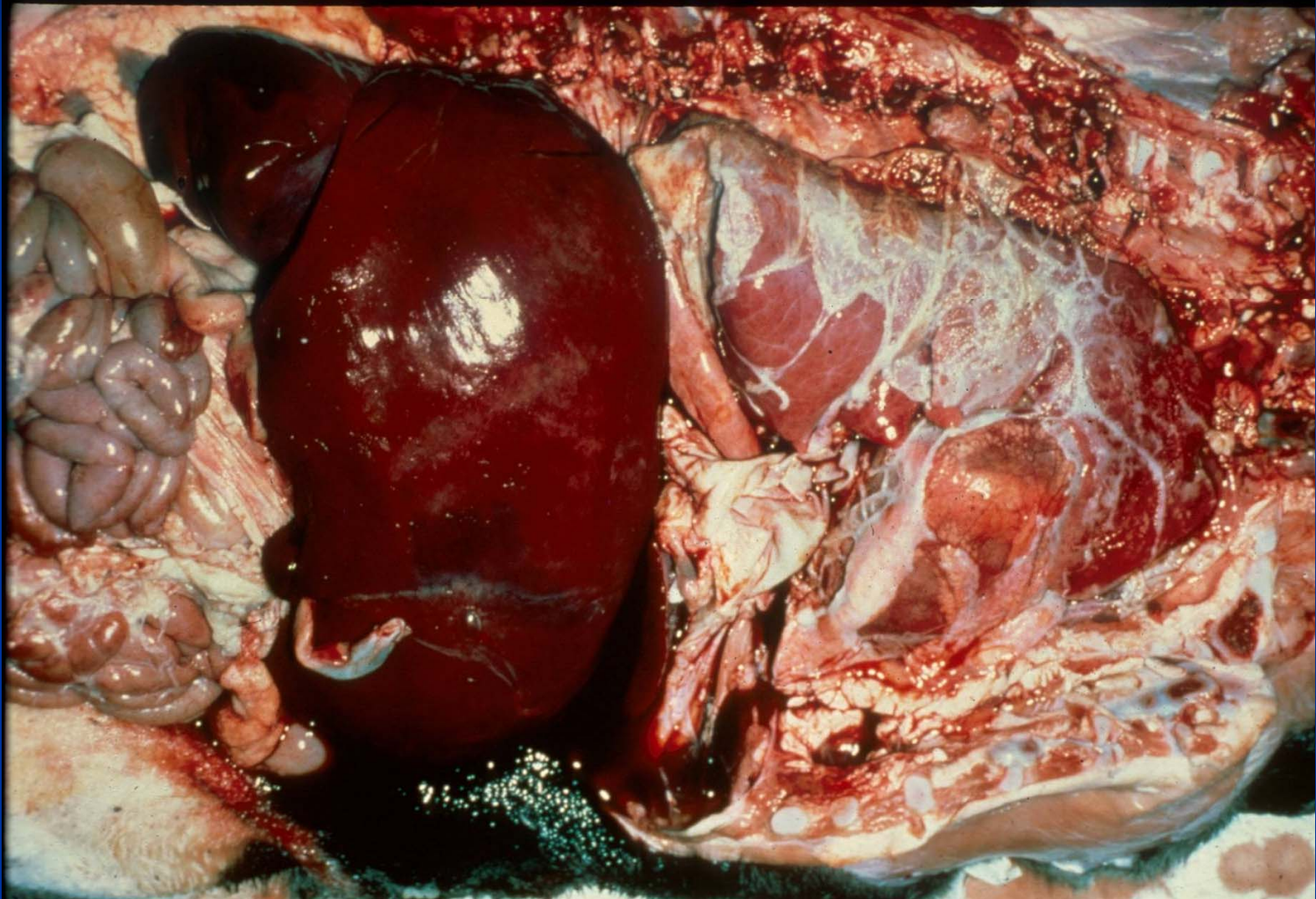


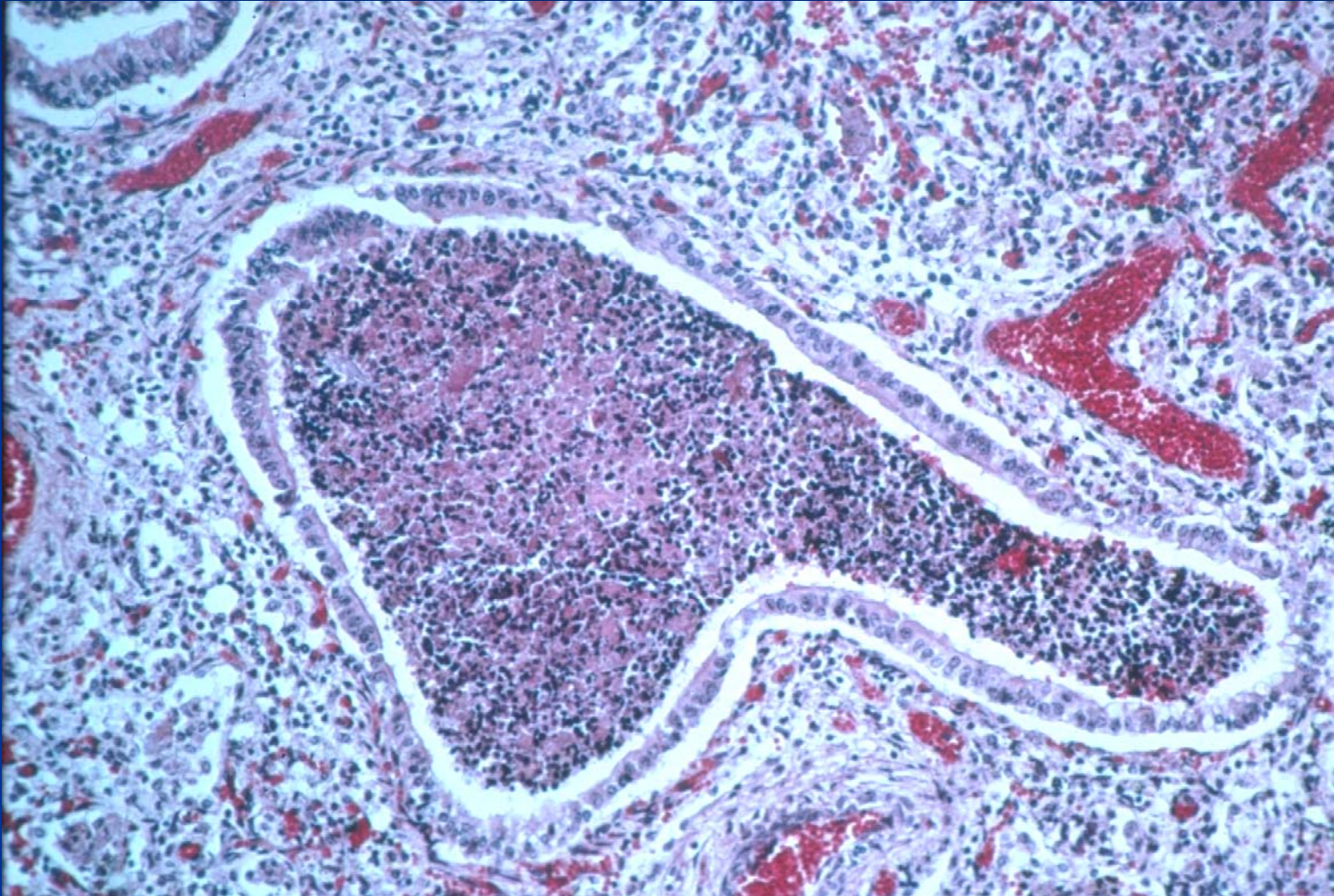
Brucellosis

- Brucellosis eradicated from Australia
- In US, reservoir in bison – occasionally “escapes” to cattle around national parks
- Affected cattle can abort and fetuses have a bronchopneumonia

Fetal Pneumonia - Brucellosis



Fetal Pneumonia - Brucellosis



Embolic Pneumonia

■ Etiology

■ Bacterial (abscesses)

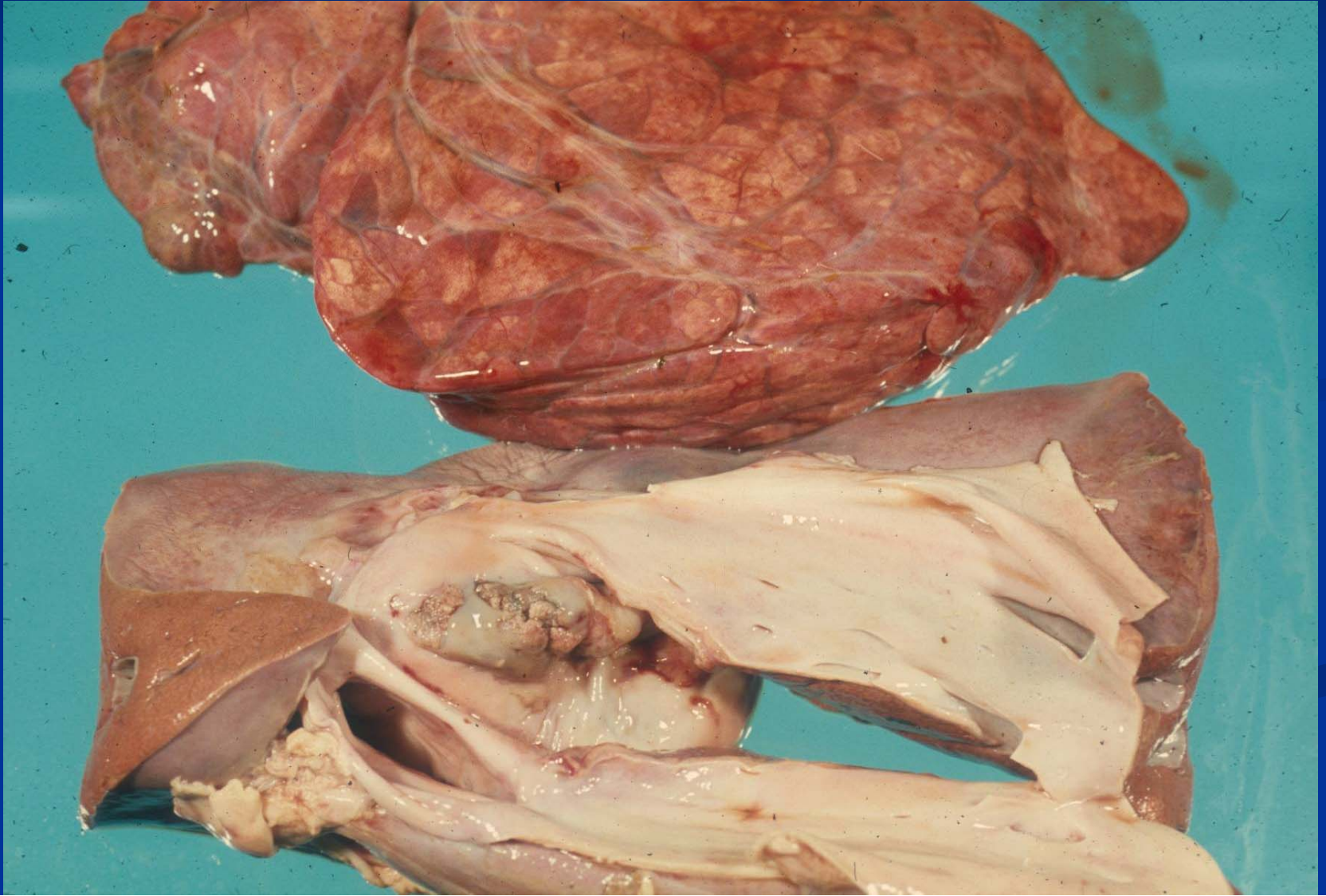
- Ruptured liver abscess
- Hardware disease
- Vegetative endocarditis
- *C. pseudotuberulosis* in sheep
- *B. holderia* (pseudoglanders) in sheep and goats

■ Mycotic (granulomas)

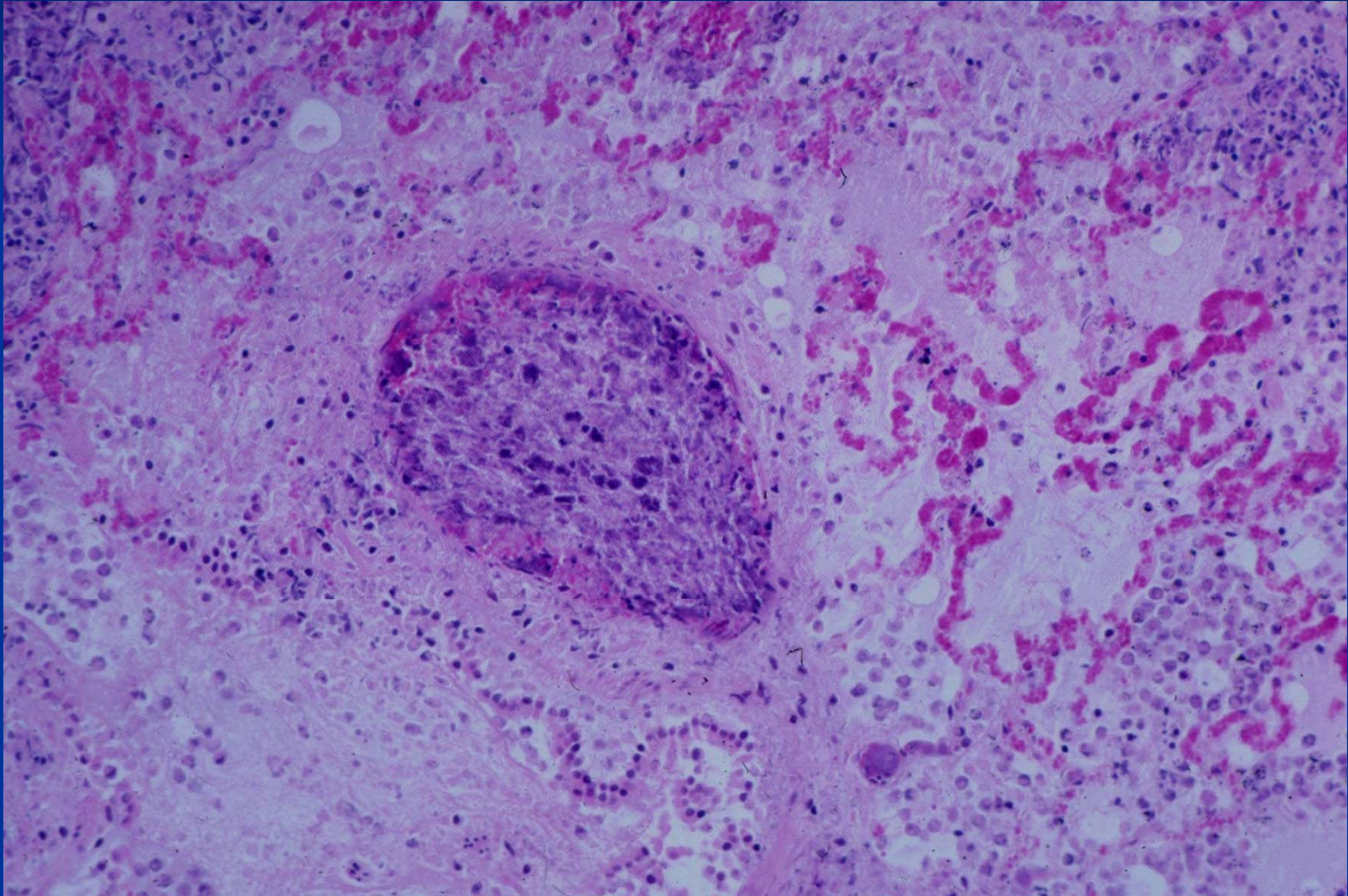
- Rumenal ulcers
- Foreign body (iv injection)

■ Sequella

Embolic Pneumonia – Ruptured Liver Abscess - Cow



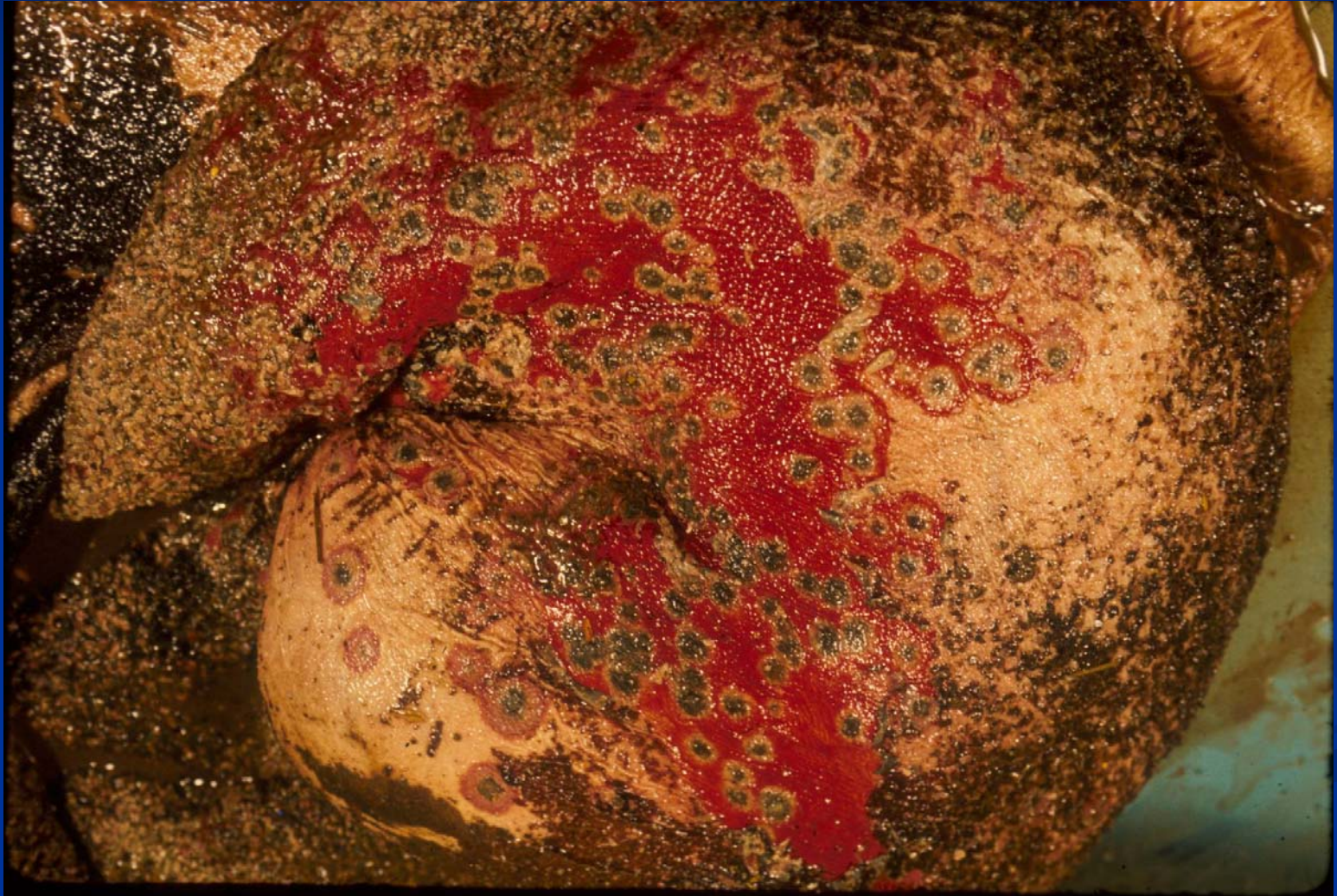
Embolic Pneumonia – Ruptured Liver Abscess - Deer



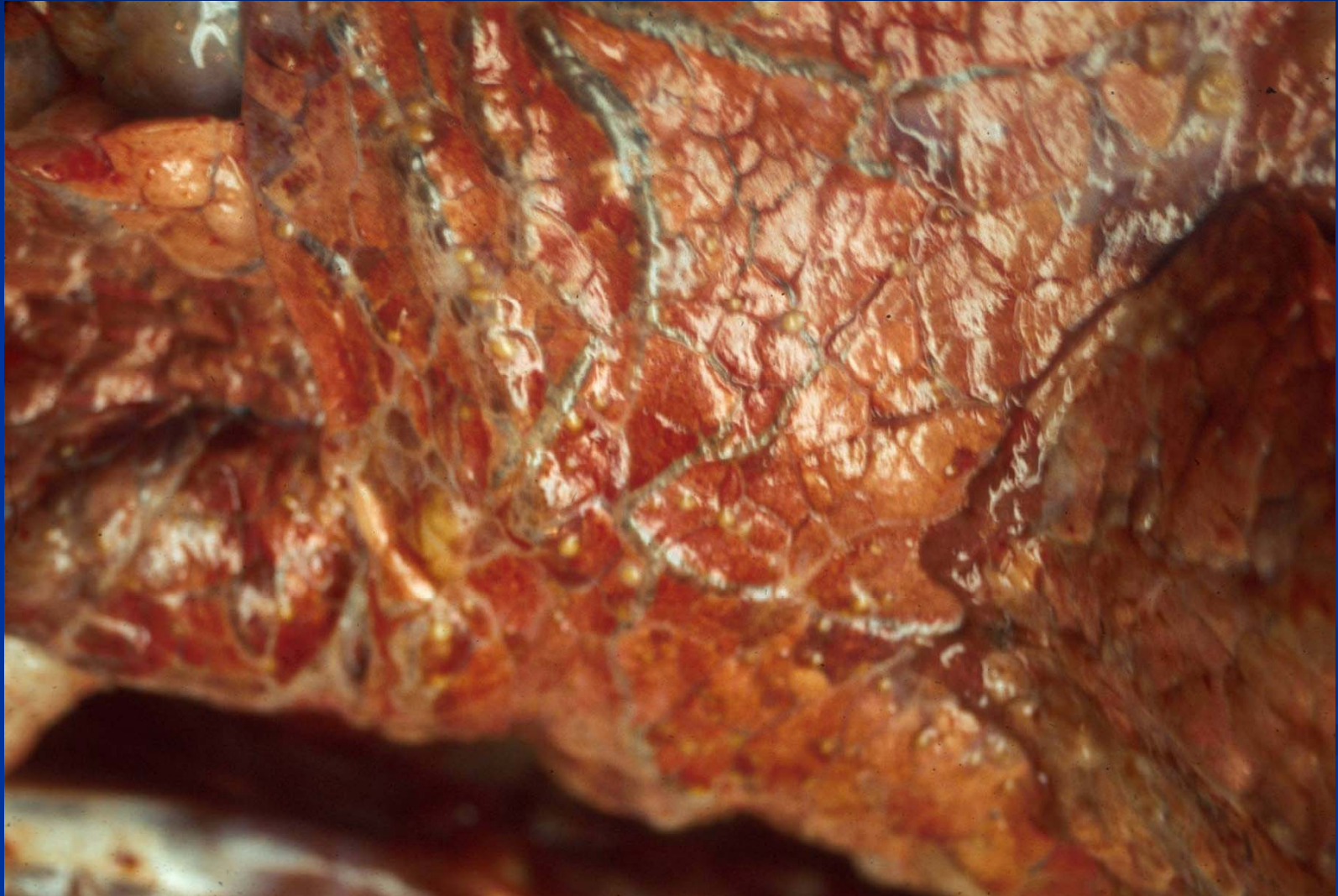
Mycotic Granulomas

- Pulmonary granulomas (embolic)
 - *Aspergillus spp.* most commonly
 - Usually rumenal ulcers allow invasion of blood vessels, may go to lung or to gravid uterus.

Rumen Ulcers - Cow



Embolic Pneumonia - Mycotic



Mycotic Granulomas

