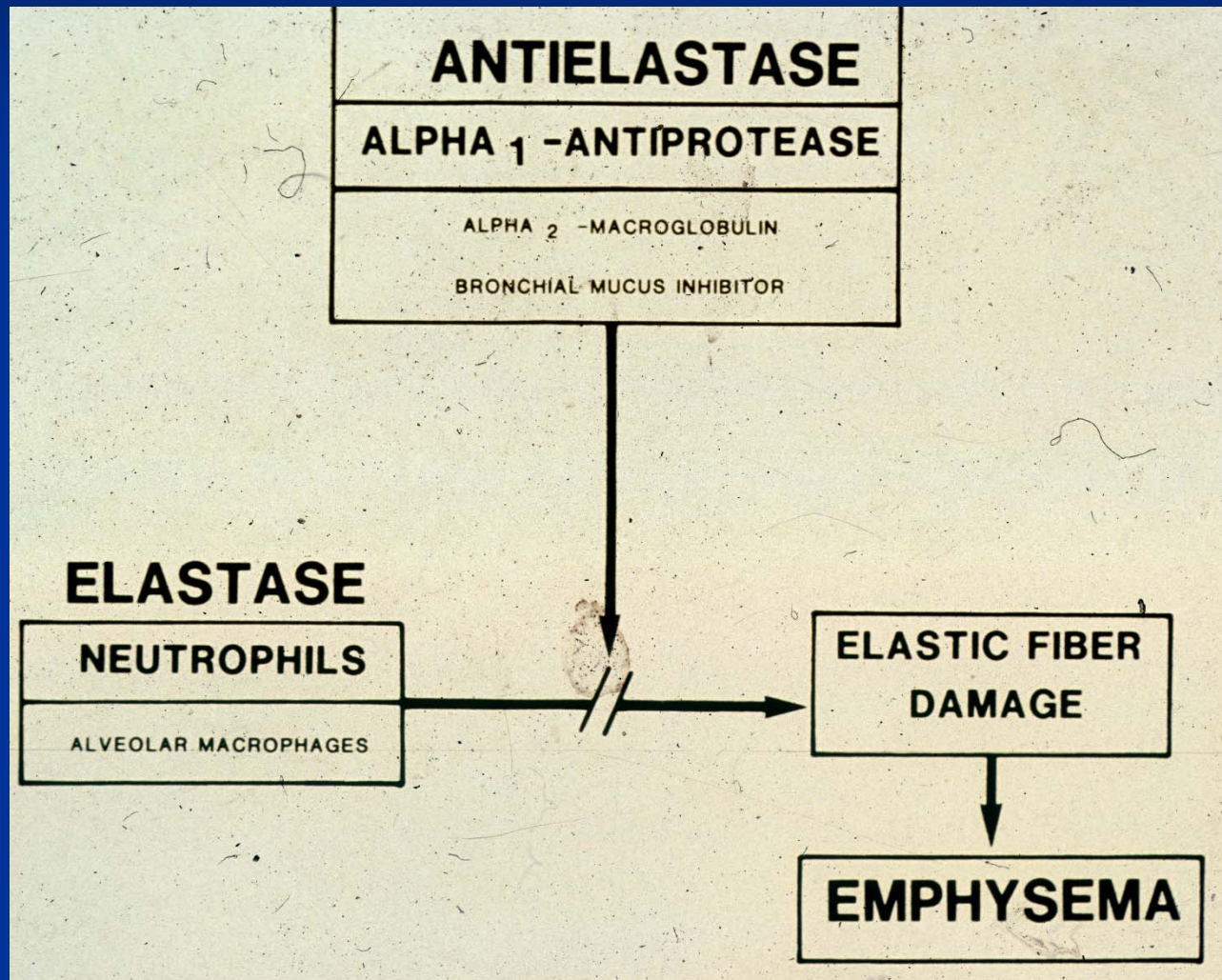
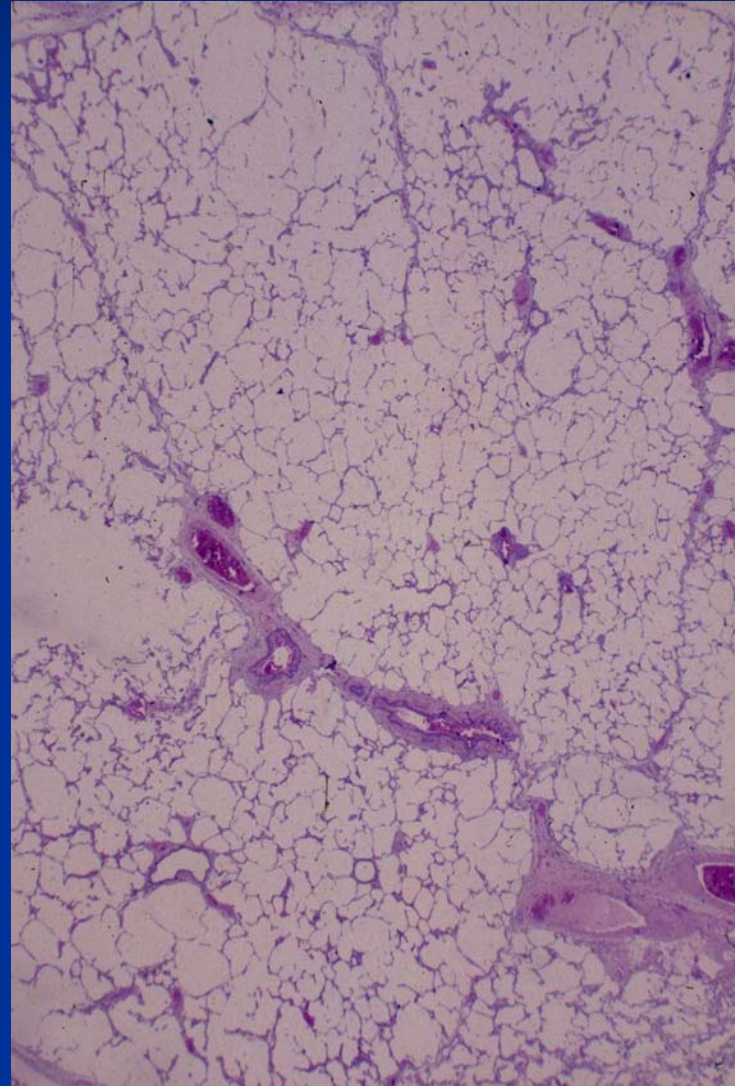
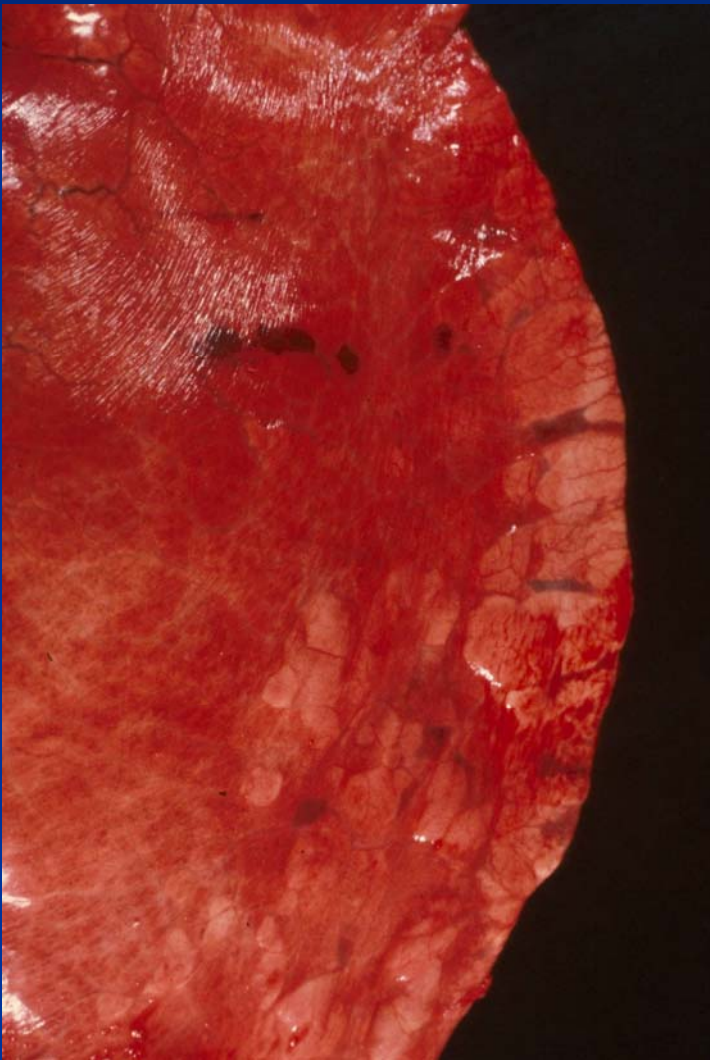


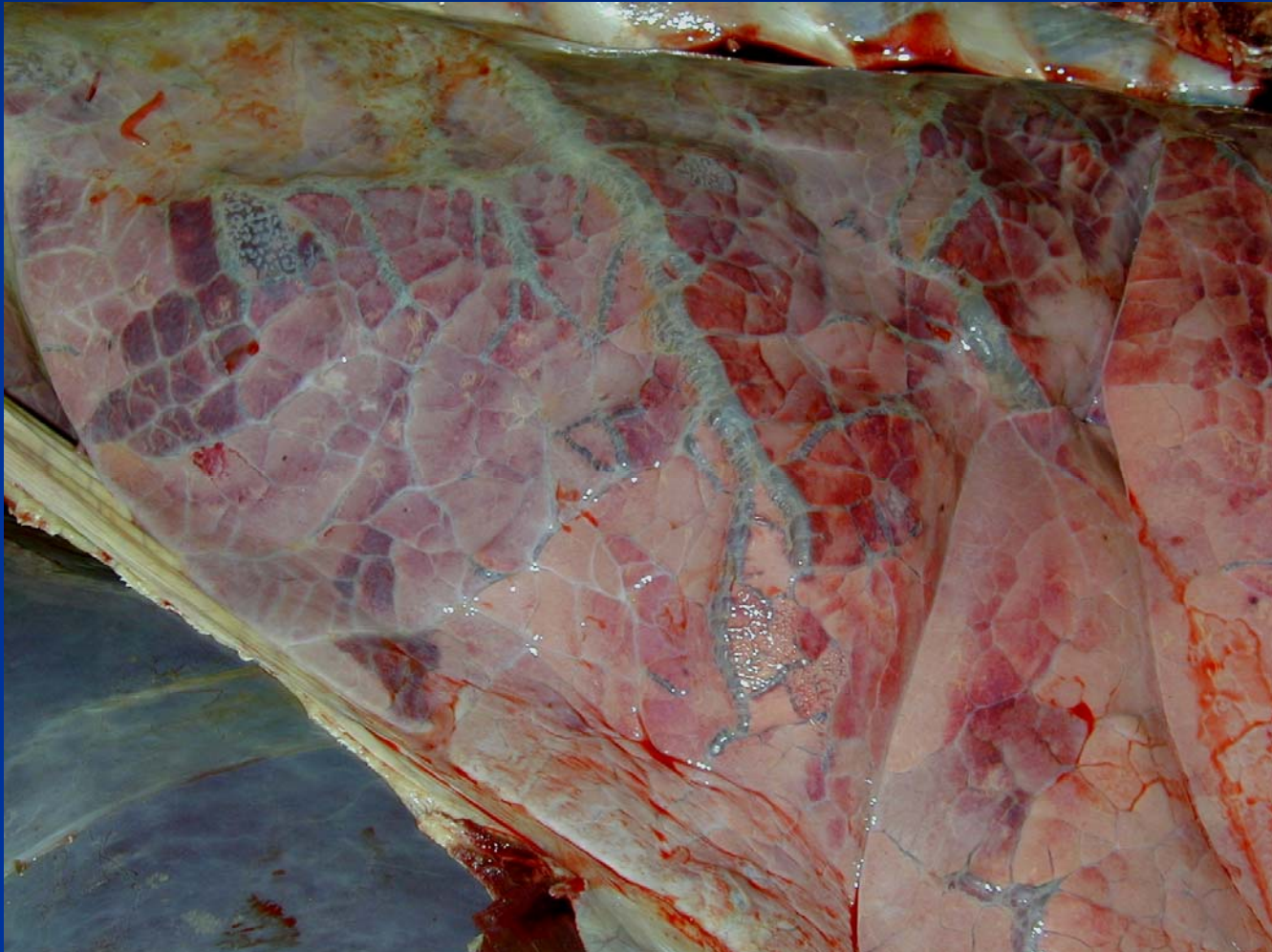
Alveolar Emphysema



Abnormalities of Inflation – Alveolar Emphysema - Horse



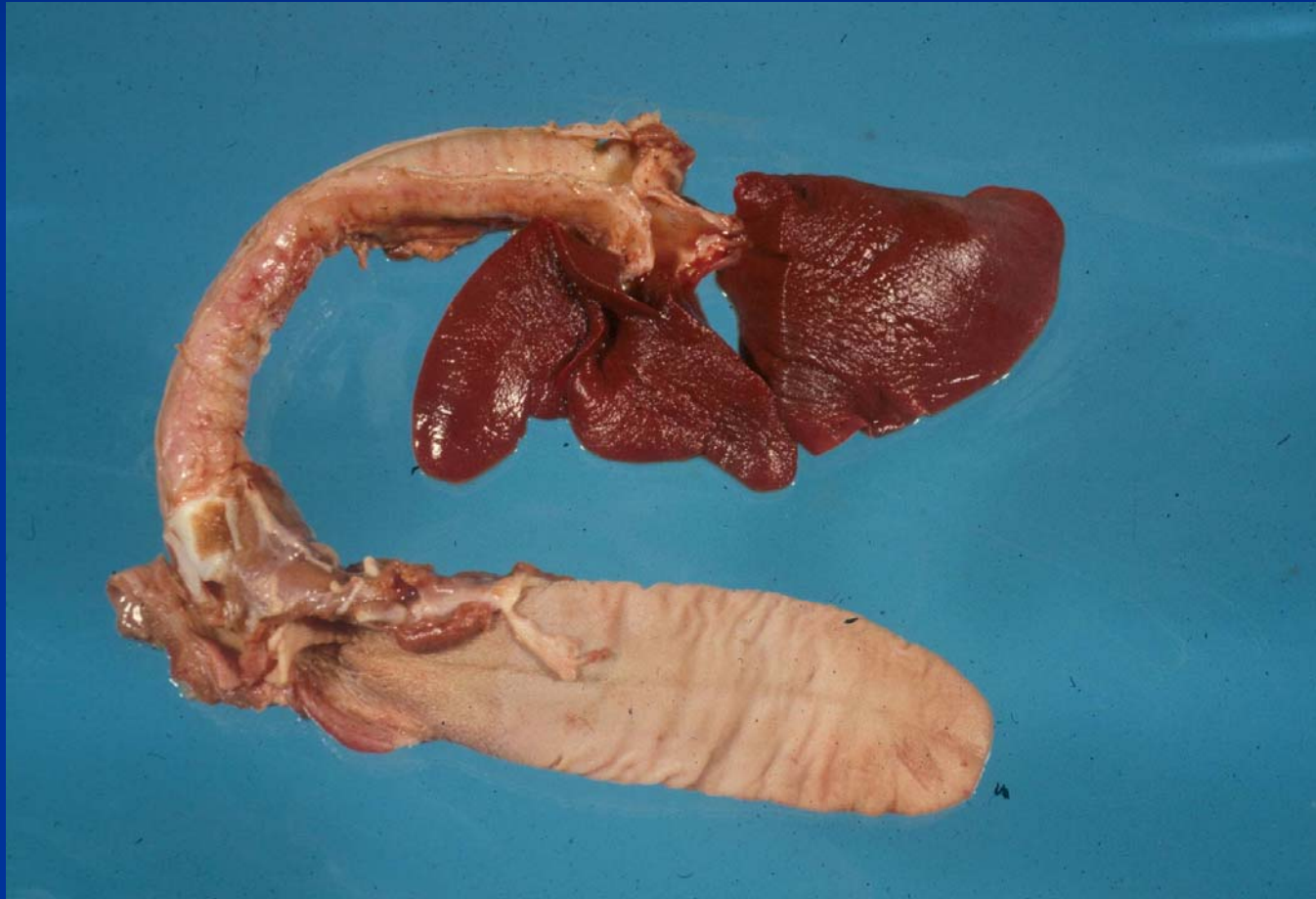
Abnormalities of Inflation – Interstitial Emphysema - Cow



Atelectasis

- Diffuse or multifocal
- Congenital atelectasis
- Acquired atelectasis
 - Compression collapse
 - Obstructive (focal)
 - Congestive or hypostatic atelectasis

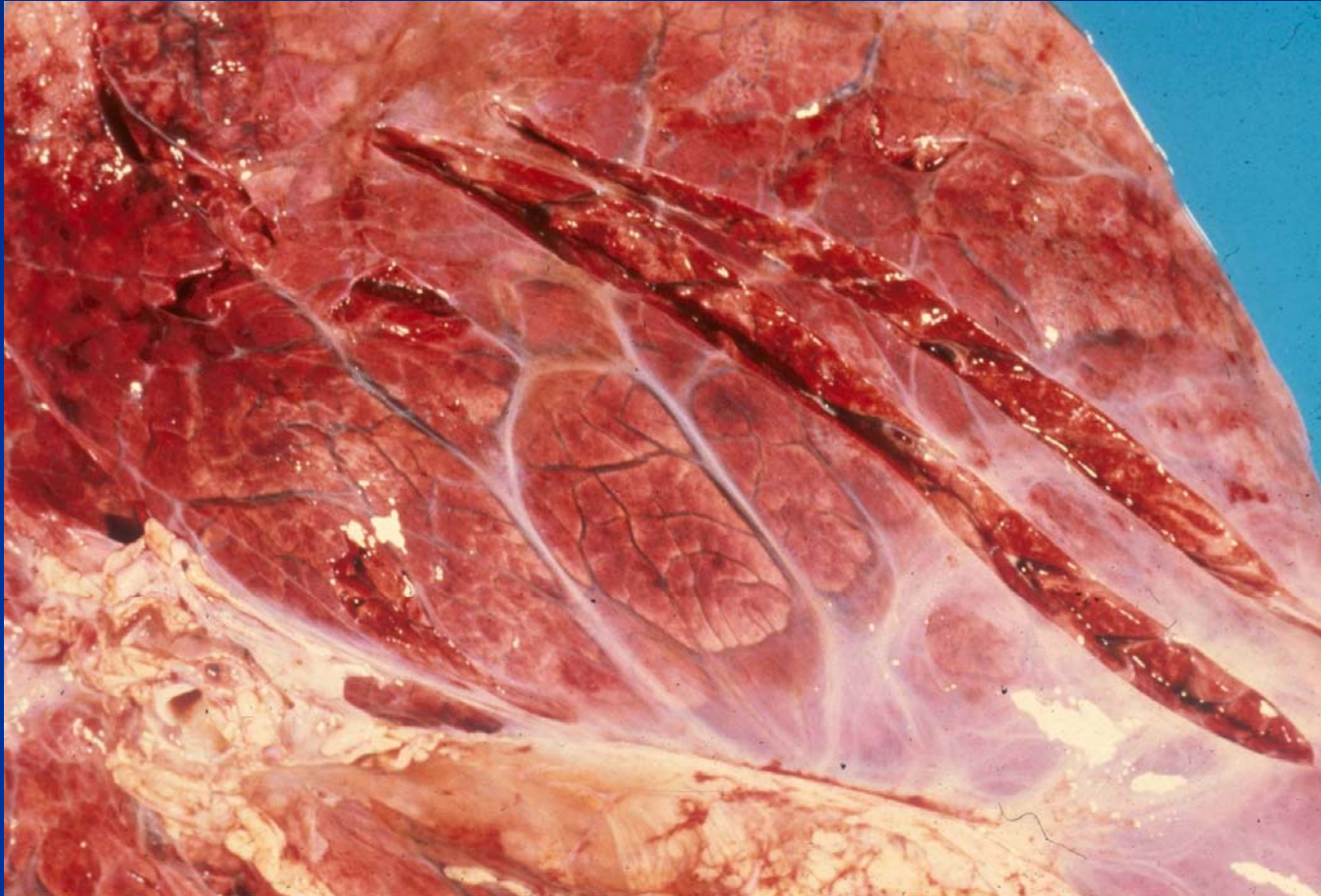
Acquired Atelectasis - Dog



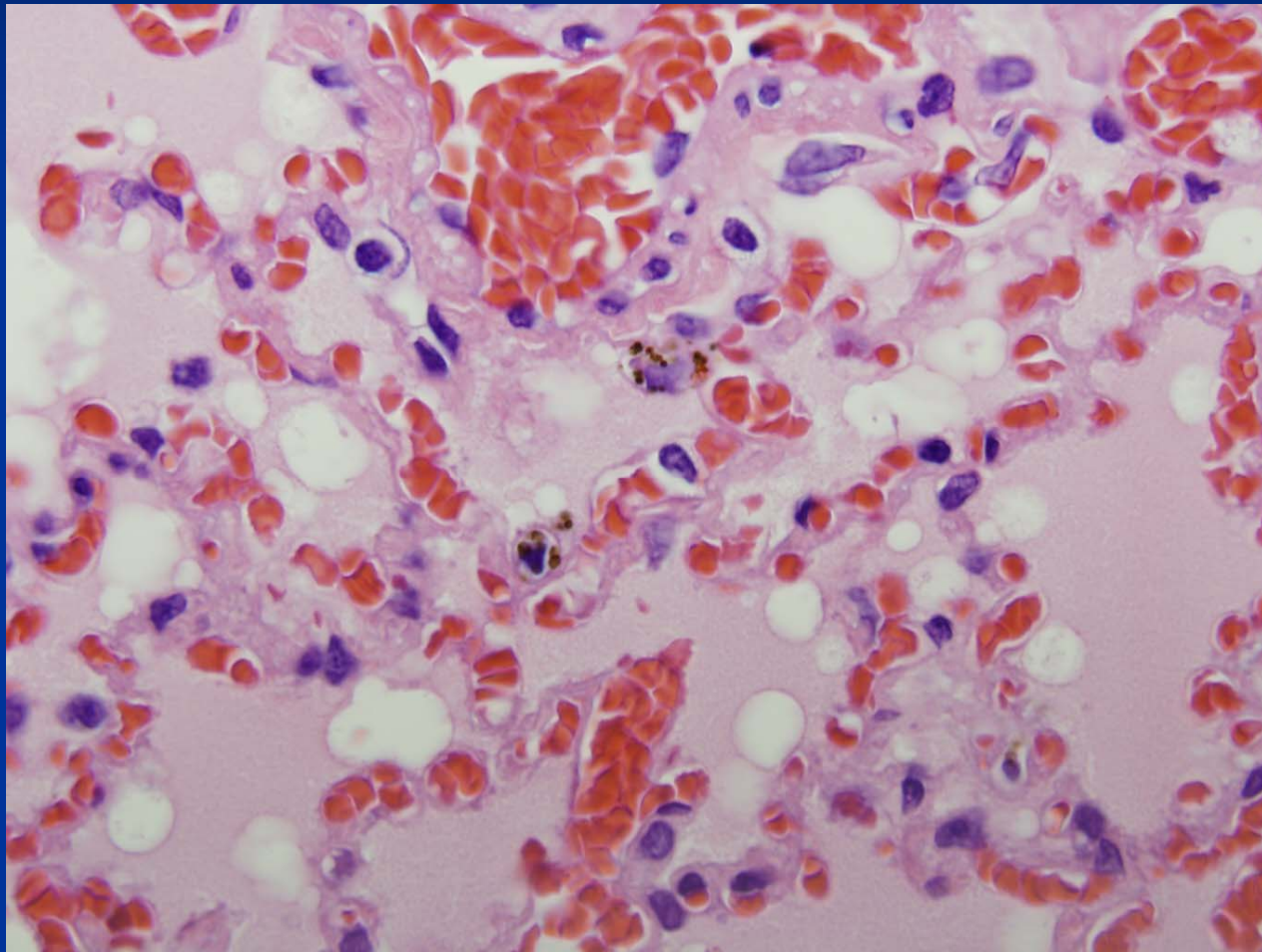
Circulatory Disturbances

- Diffuse pulmonary edema
- Hemorrhage
 - Petechia, ecchymosis
 - EIPH
- Embolism, thrombosis, infarction
- Pulmonary hypertension

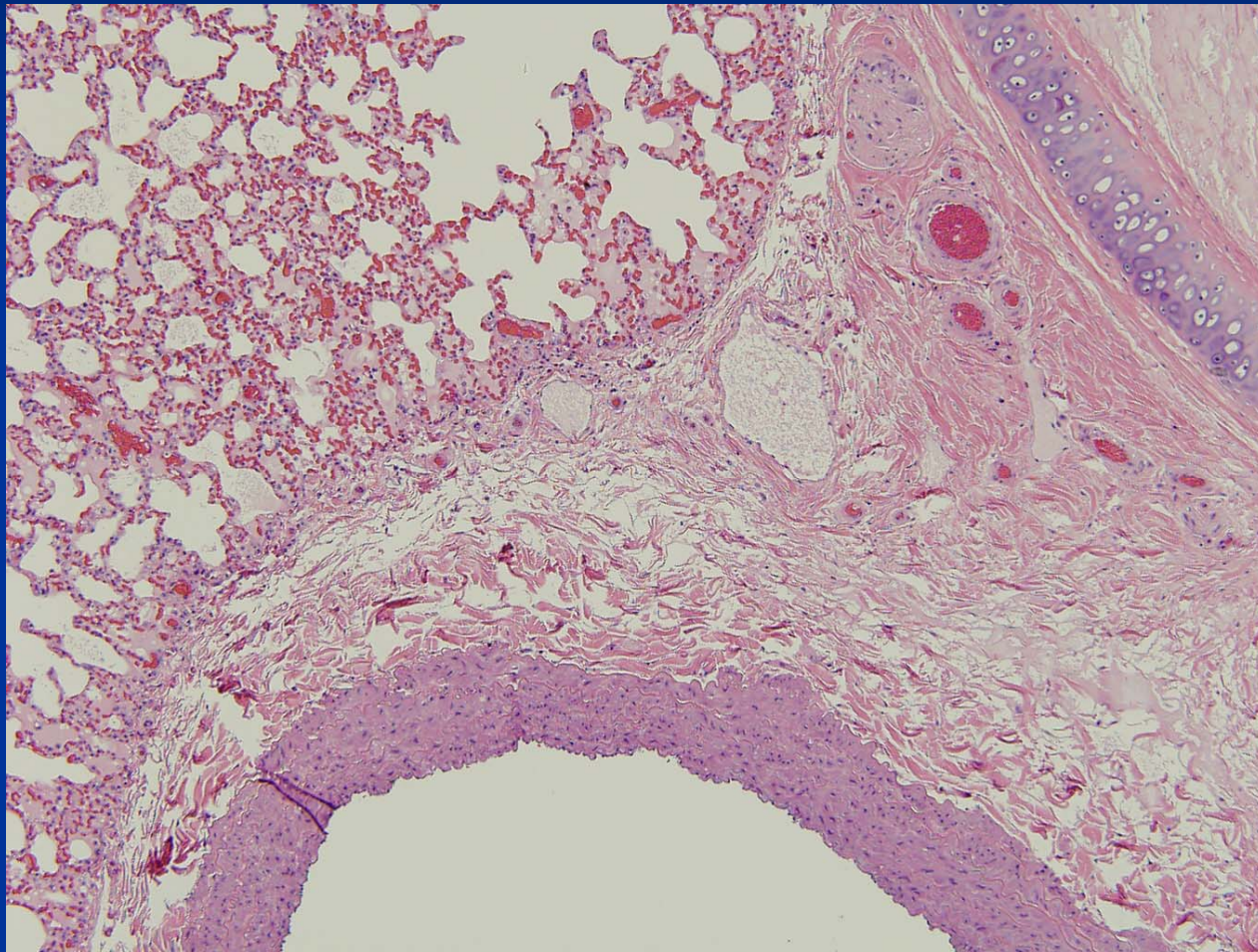
Pulmonary Edema – Cow



Cardiogenic Edema—Dog



Cardiogenic Edema—Dog



Mechanisms of Pulmonary Edema

- Altered hemodynamics
 - Increased capillary hydrostatic pressure
 - Decreased plasma oncotic pressure
- Increased permeability of air-blood barrier (noncardiogenic)
- Lymphatic obstruction
 - Note normal location of lymphatics
- Airway obstruction