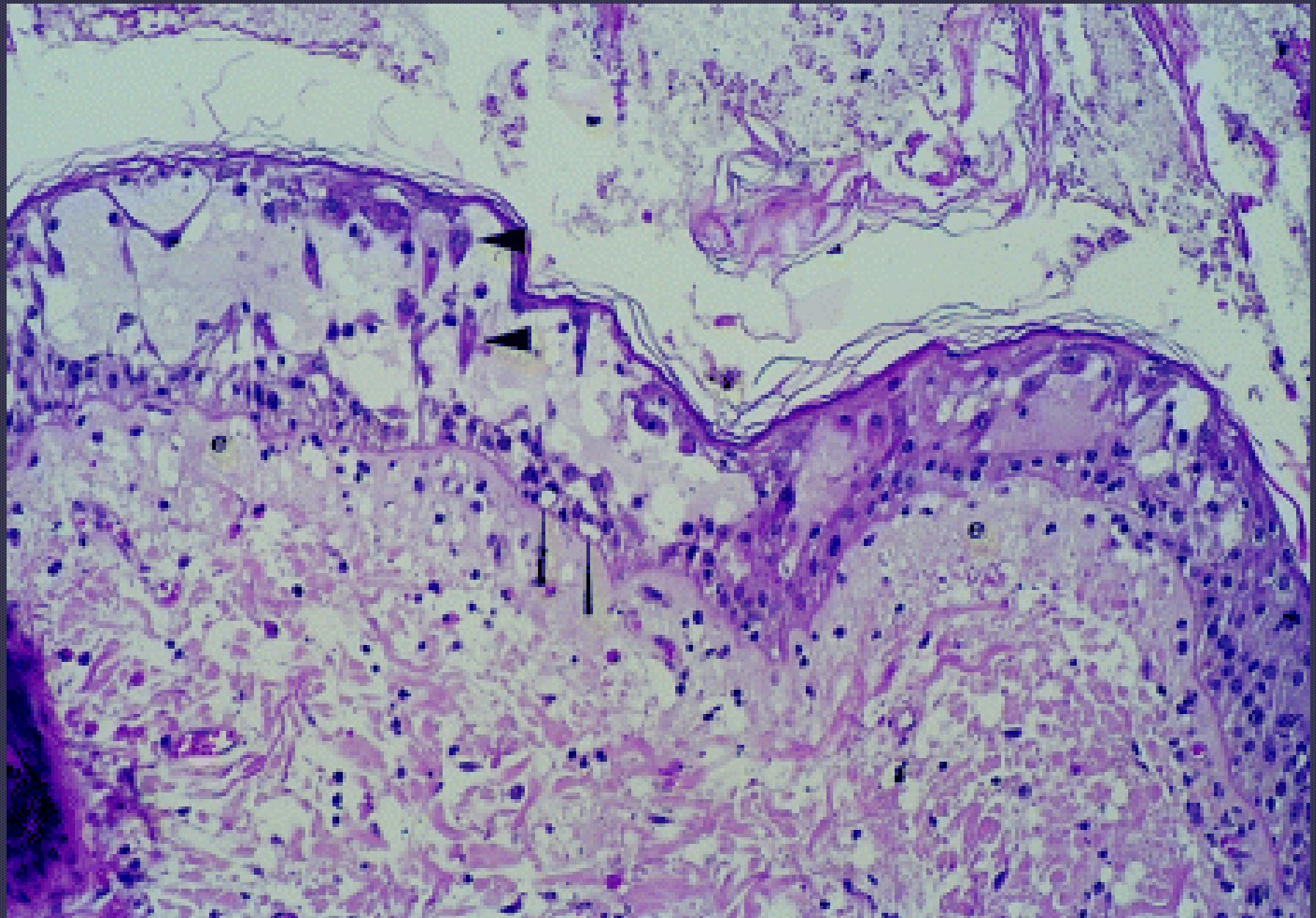
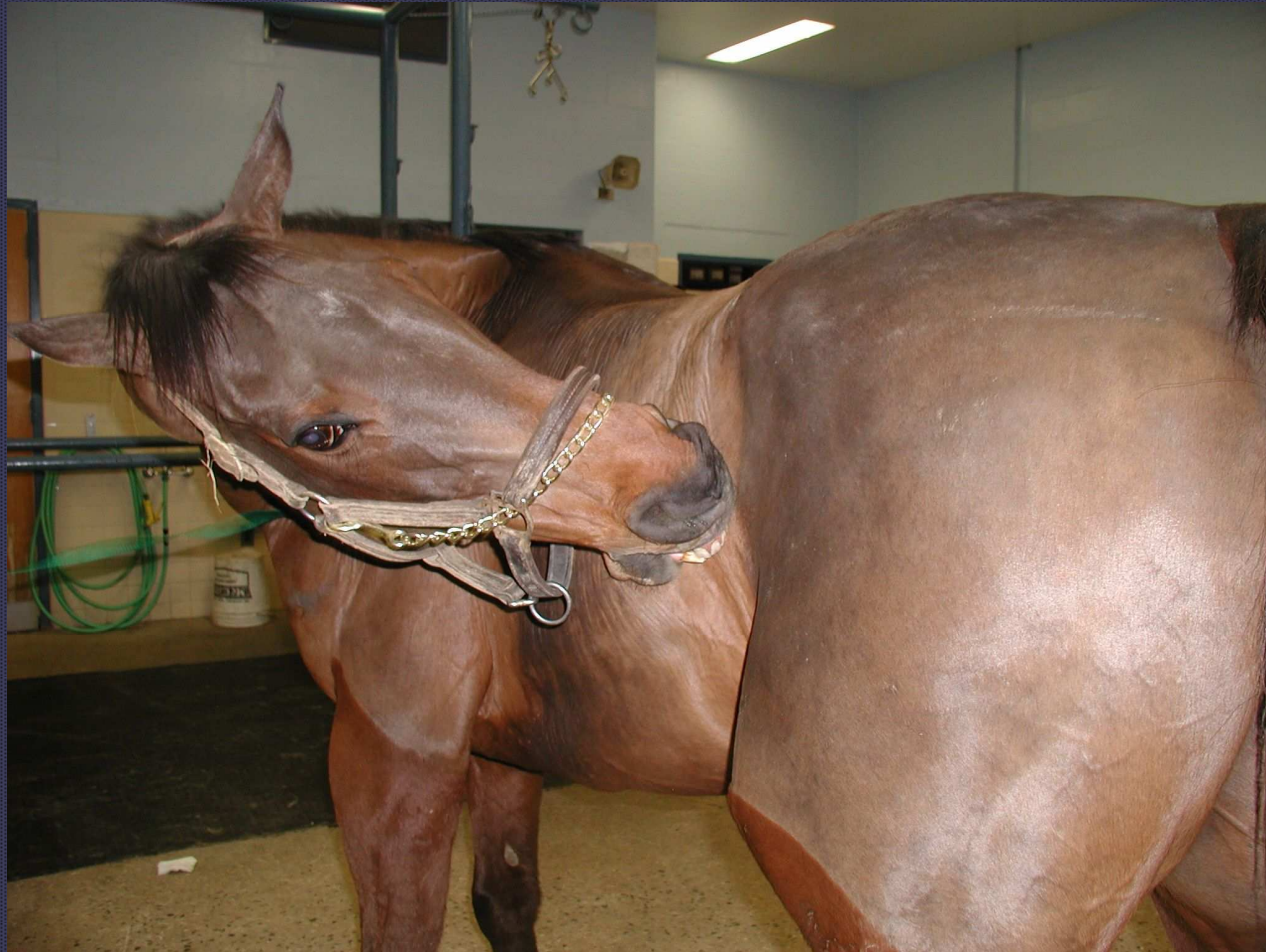
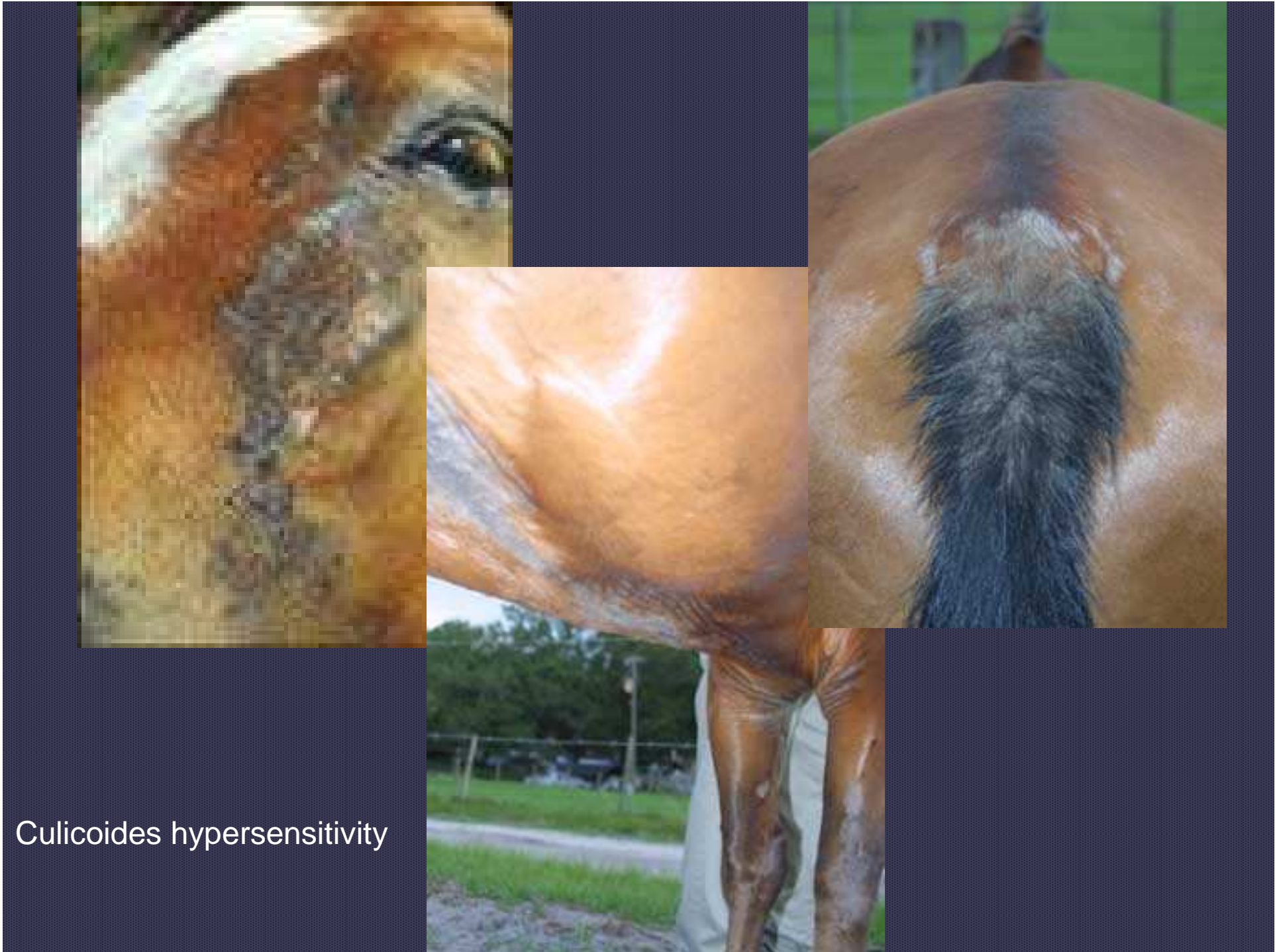# Spongiotic Vesicular Dermatitis

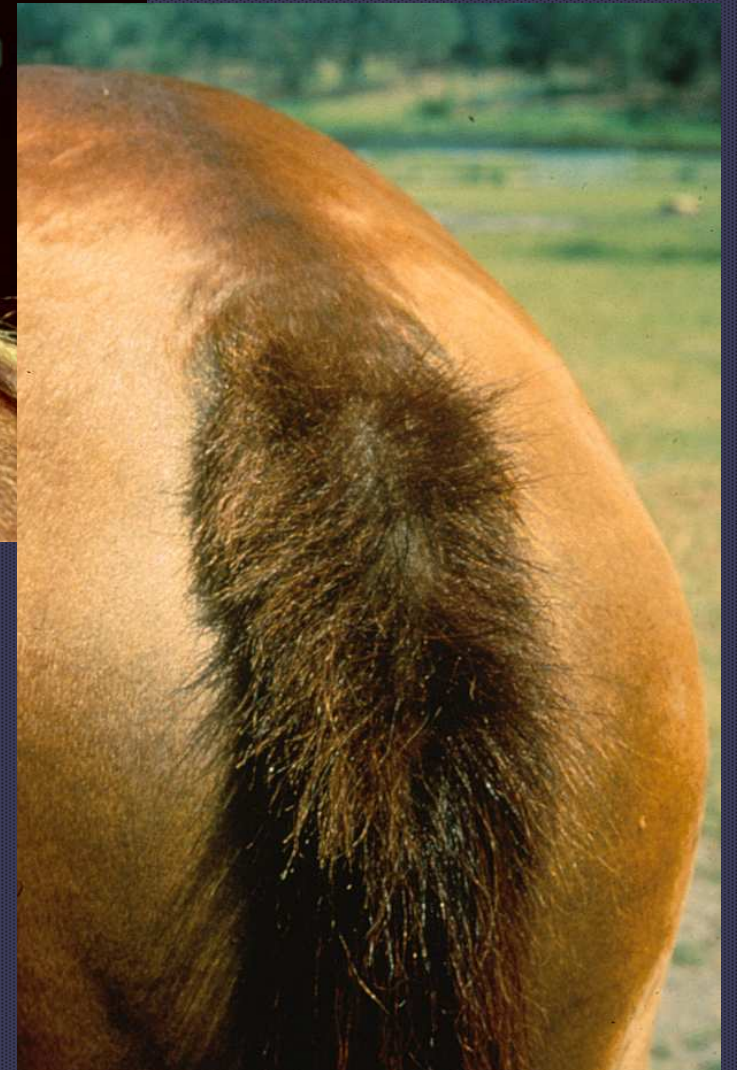
- Cutaneous reaction pattern
- Not specific to cause
- Hypersensitivity reaction
- Severe epidermal edema → acantholysis → do not confuse with autoimmune disorder

# Pruritic horses

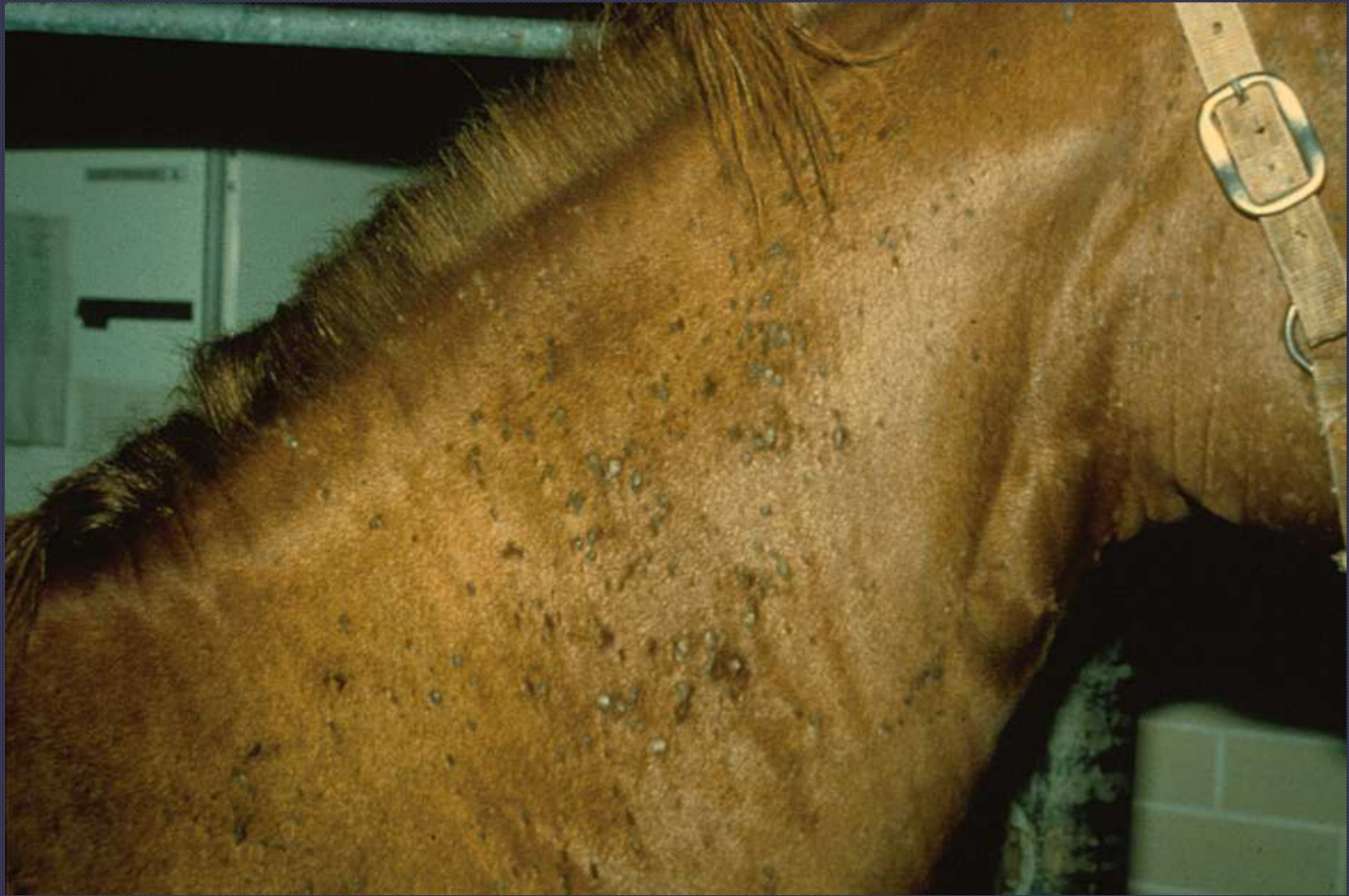



Culicoides hypersensitivity

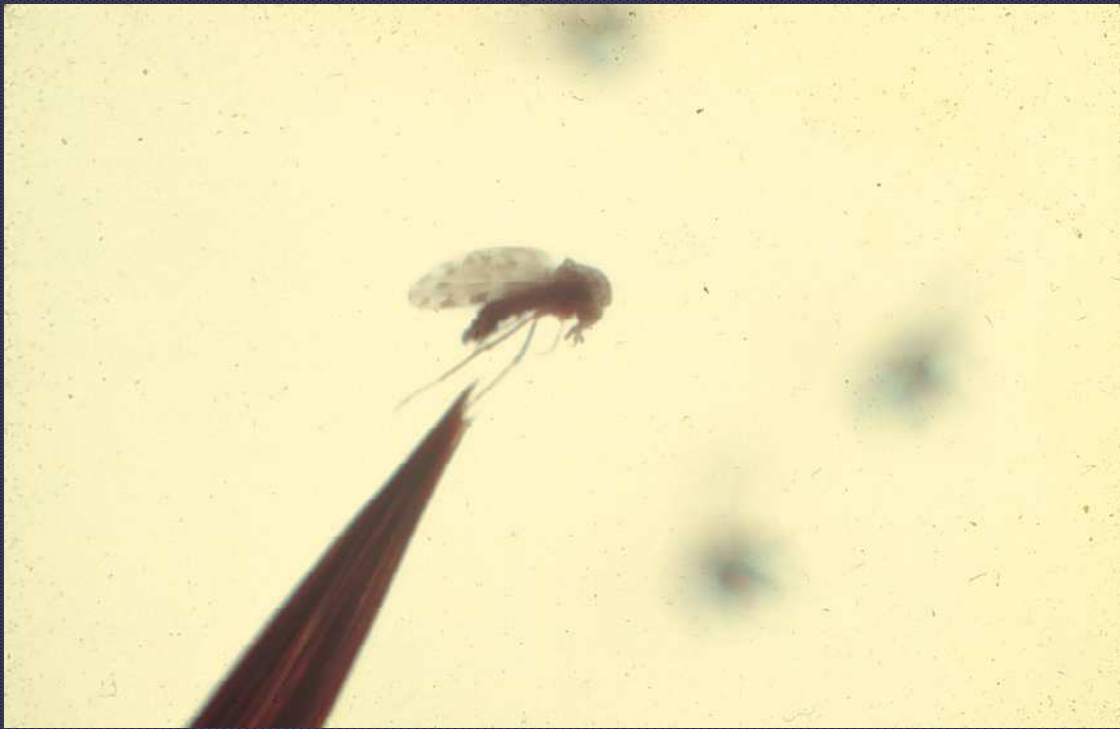

Culicoides hypersensitivity

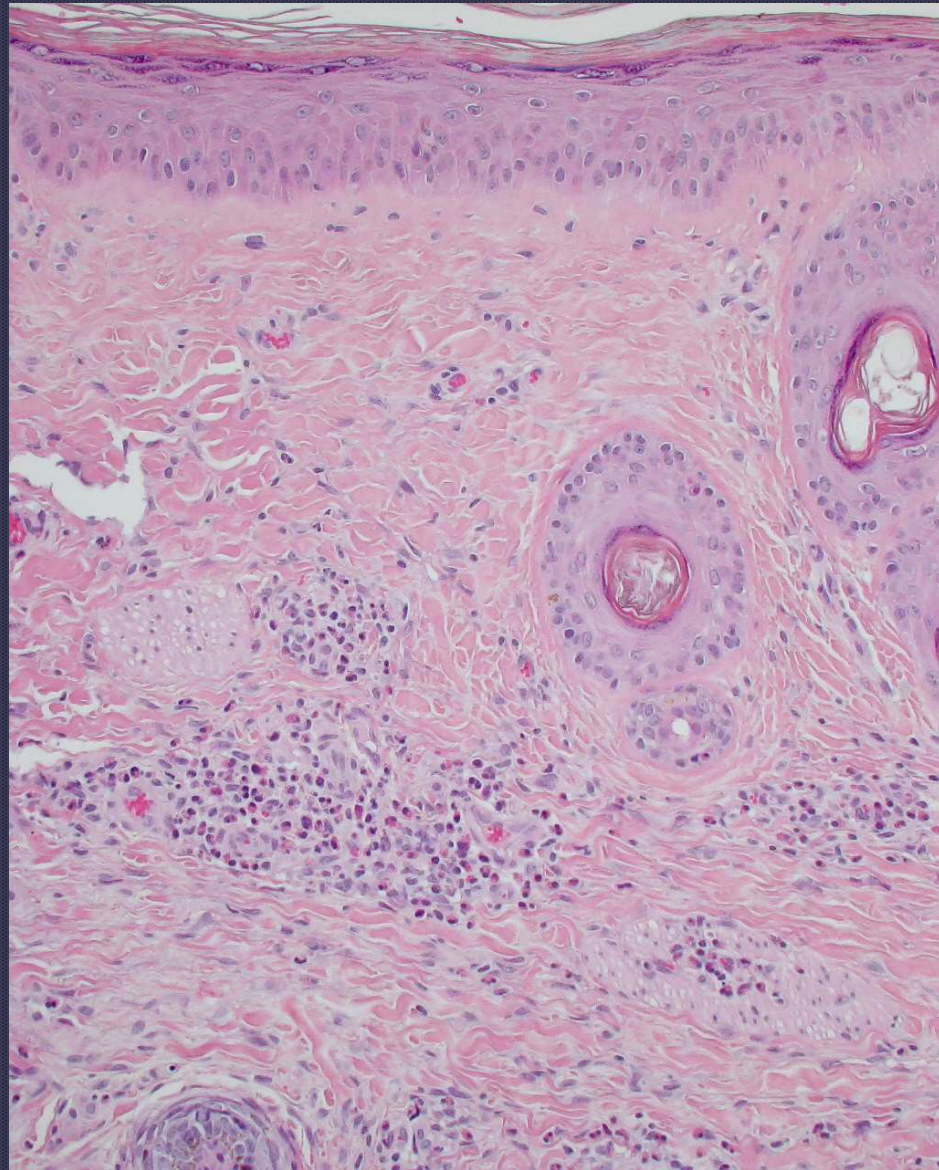




Intradermal skin test







Eosinophilic perivascular dermatitis

# Pemphigus foliaceus

- Most common autoimmune skin disease
- Middle-aged horses (8.5-9 yrs)
- Better prognosis in young horses (< 1yr or younger)
- No age/breed/sex predilection