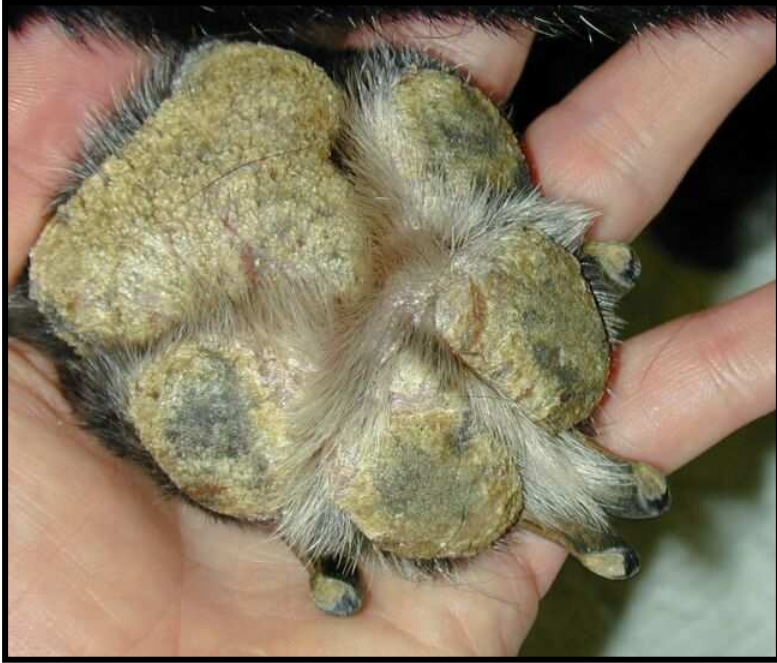
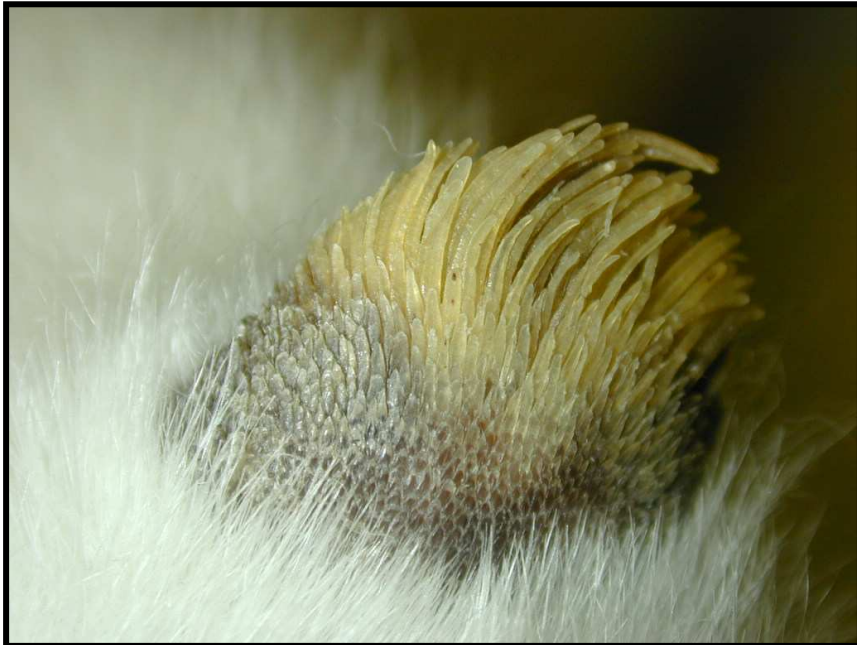
Hyperkeratosis

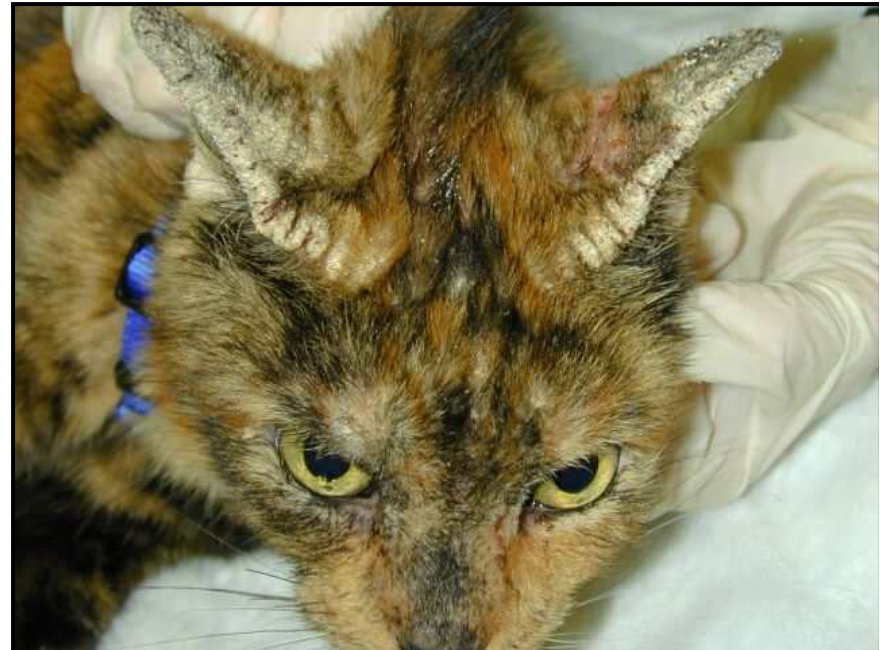
Footpad hyperkeratosis due
hepatocutaneous syndrome in a dog



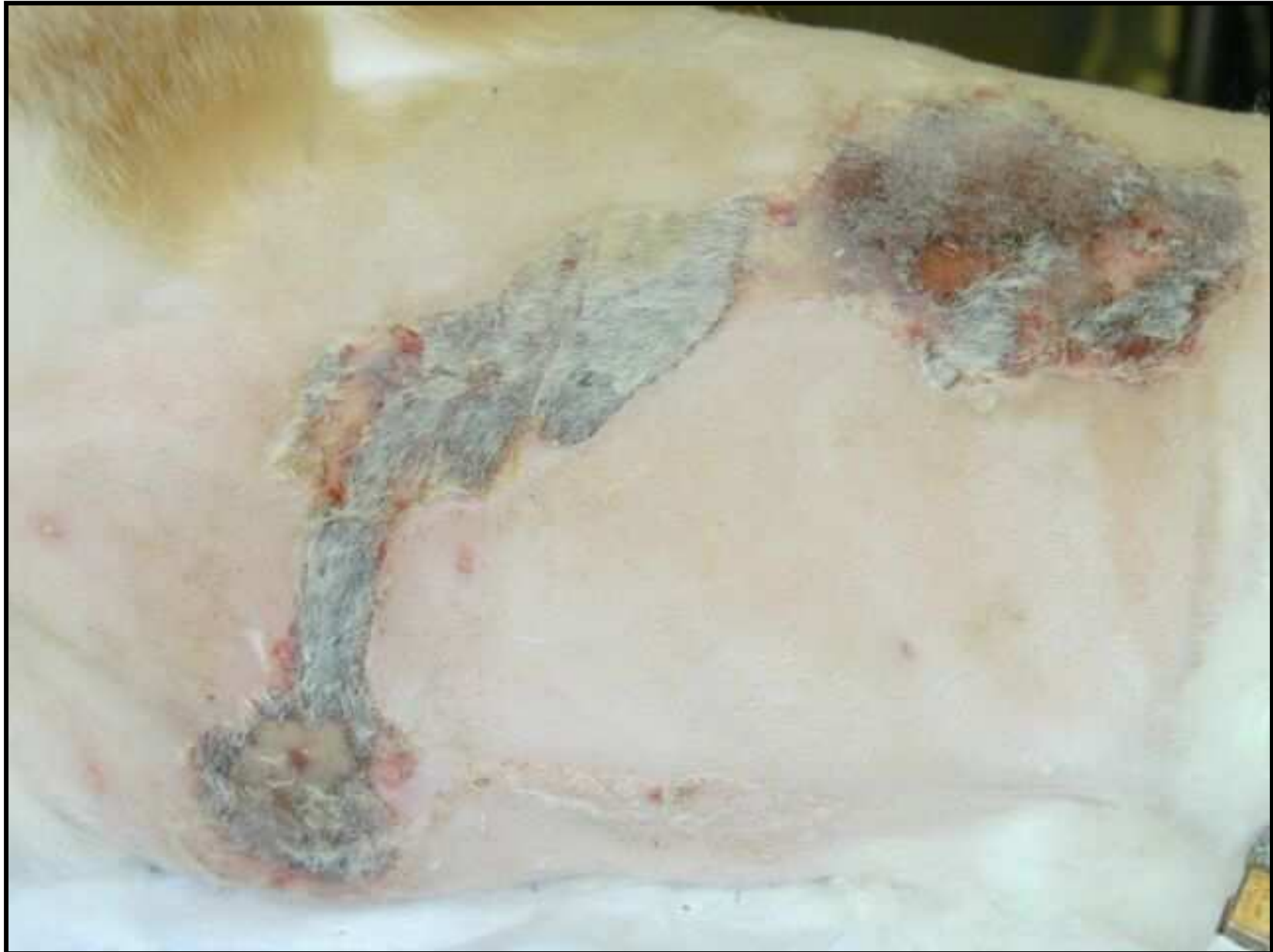Cutaneous horn on the footpad of a cat with
FIV infection



Pinnal margin hyperkeratosis due to feline scabies



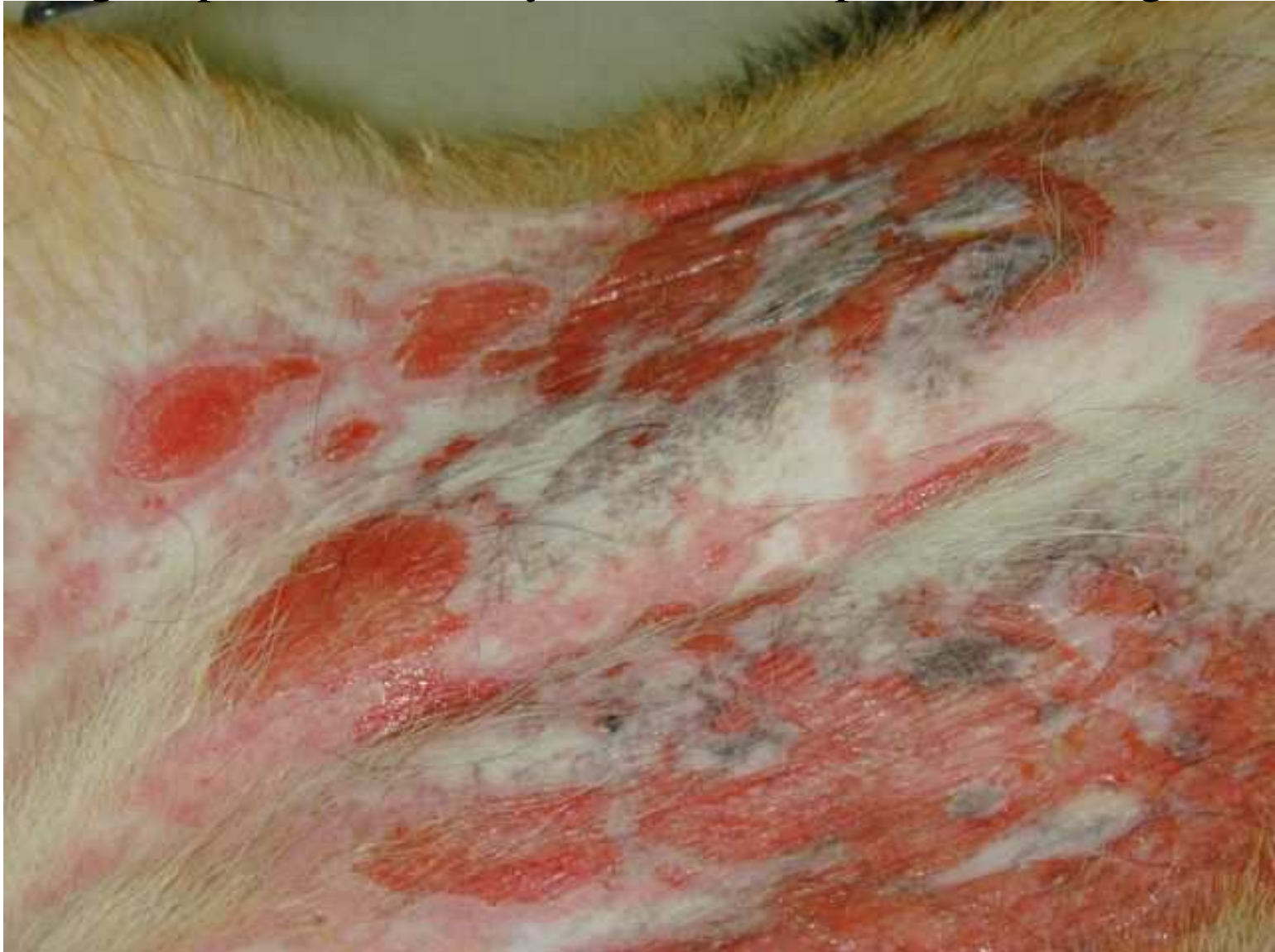Eschar resulting from a thermal burn

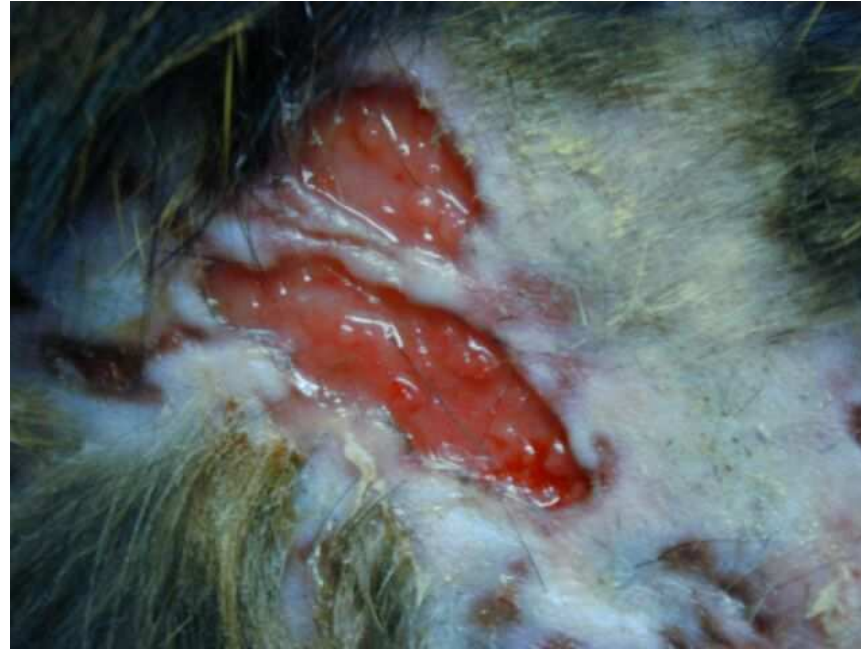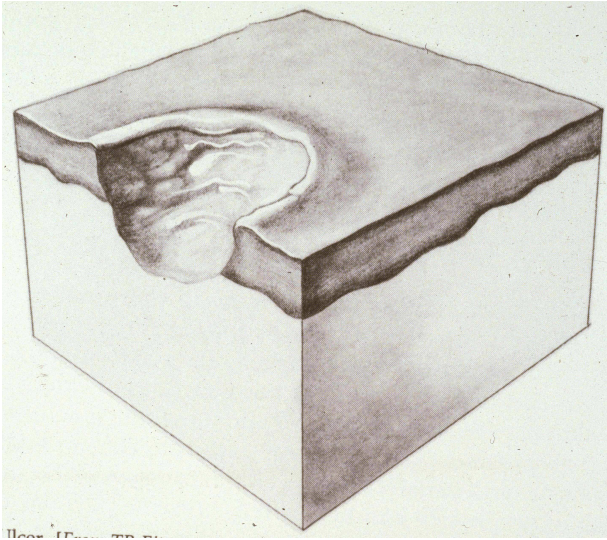


Erosions and ulcers

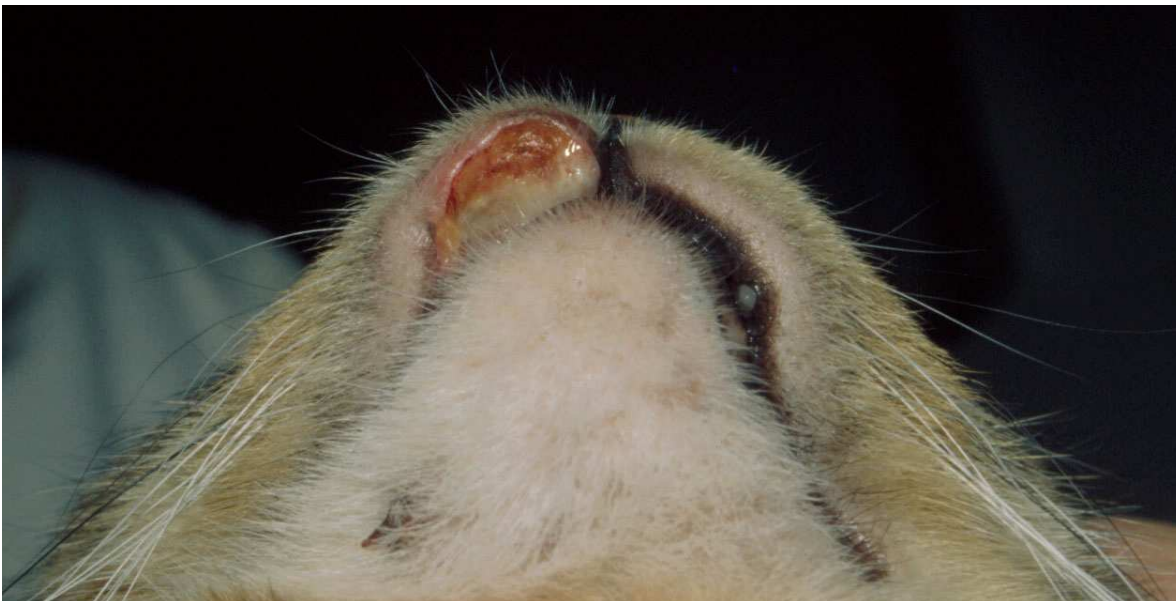
- An erosion is a shallow epidermal defect that does not disrupt the basement membrane (the zone which separates the epidermis from the dermis)
- An ulcer is a deeper defect that penetrates beyond the basement membrane (into the dermis).
- The term “full thickness” ulcer usually refers to one that extends into the subcutaneous fat.

Erosions due to Stevens-Johnson syndrome (cutaneous drug eruption) secondary to a trimethoprim-sulfa drug





Full thickness feline cutaneous ulcers
due to *Nocardia spp.* infection



Feline indolent lip ulcer
(aka “rodent” ulcer) due
to flea bite allergy