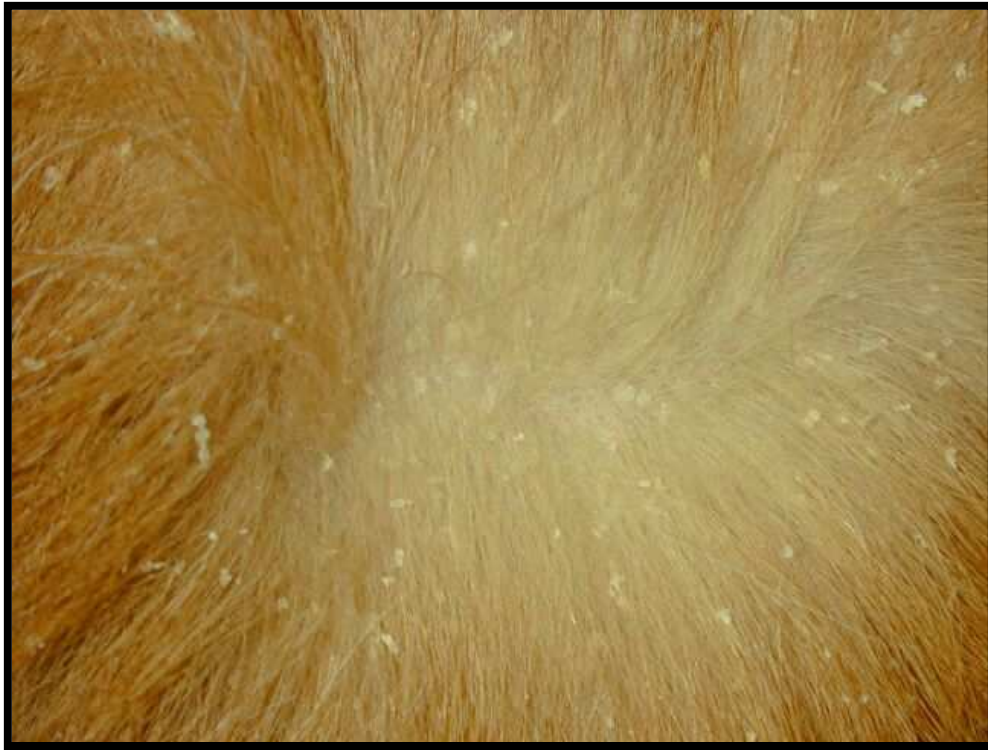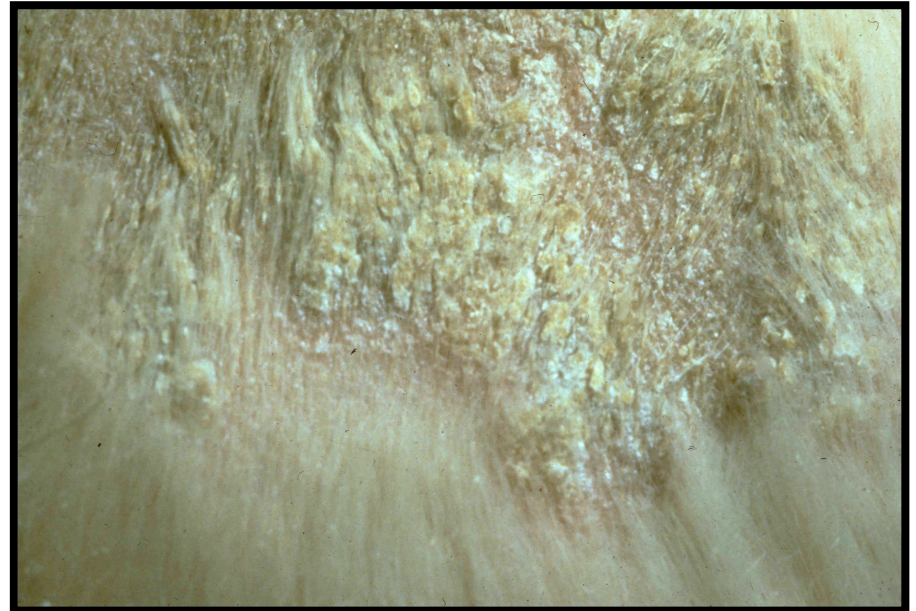

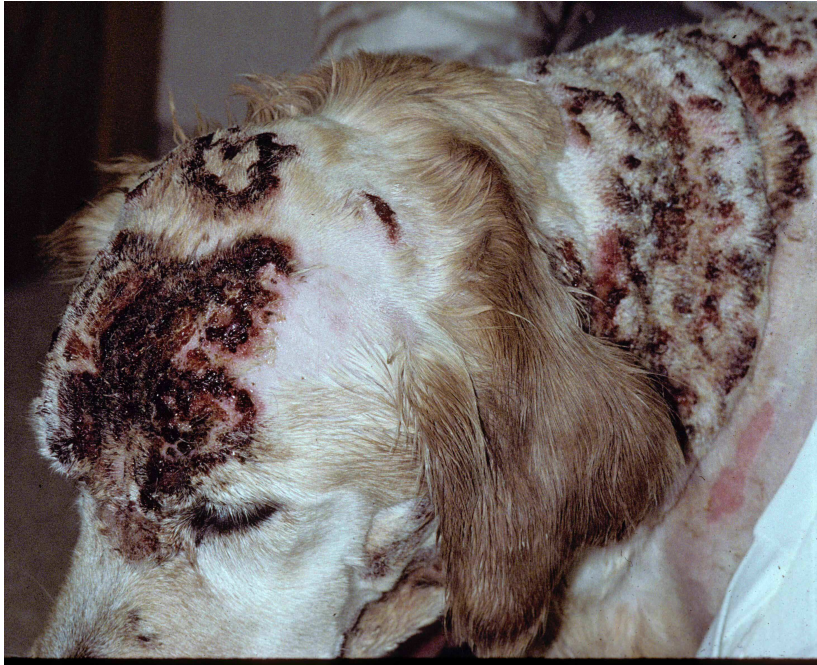


Scale (seborrhea sicca) due to *Cheyletiella* infestation in a dog

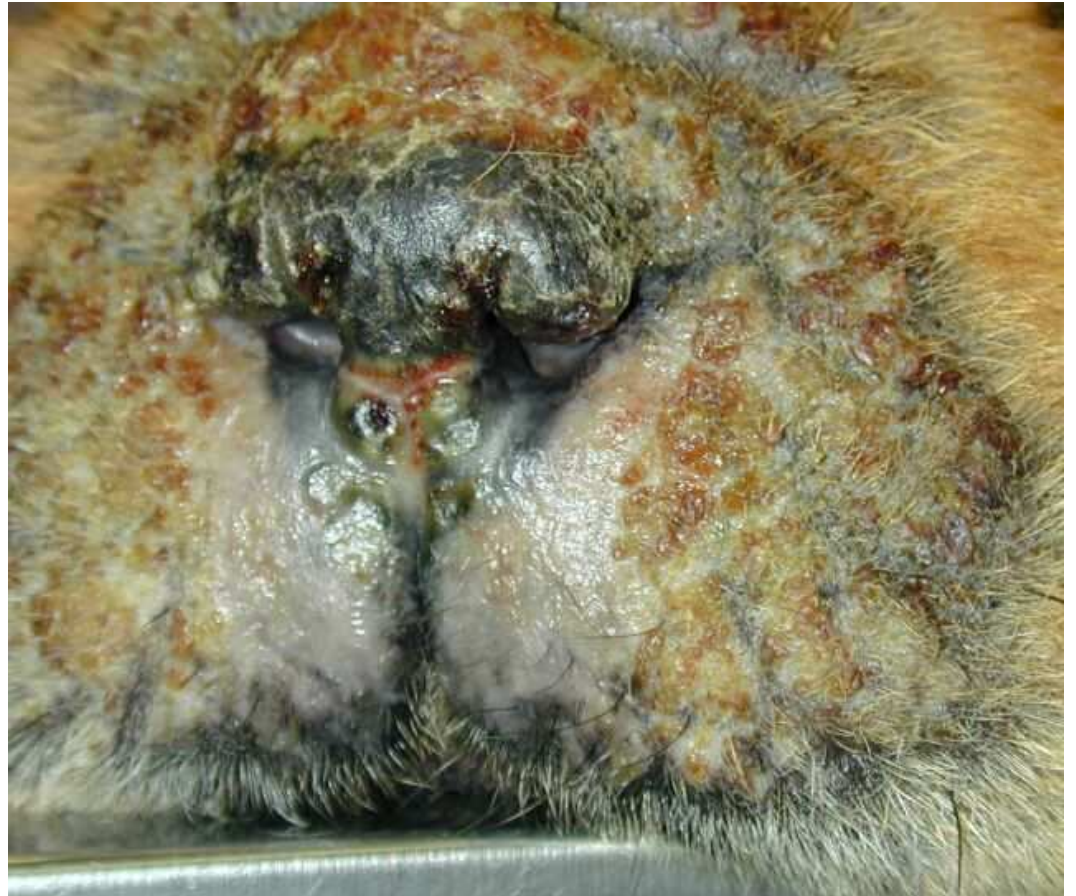Heavy, adherent scale (known as a
“seborrheic plaque”) →






Hemorrhagic crusts in a Golden retriever with cutaneous vasculitis

Suppurative crusts on the muzzle and nasal planum of a chow with pemphigus foliaceus





A lichen from an Elm tree, from which the term “lichenification” is derived. Lichenification is a hyperplastic change resulting from chronic friction or inflammation

Lichenification of the perineal area
(due to chronic self-trauma)
secondary to flea bite allergy

