

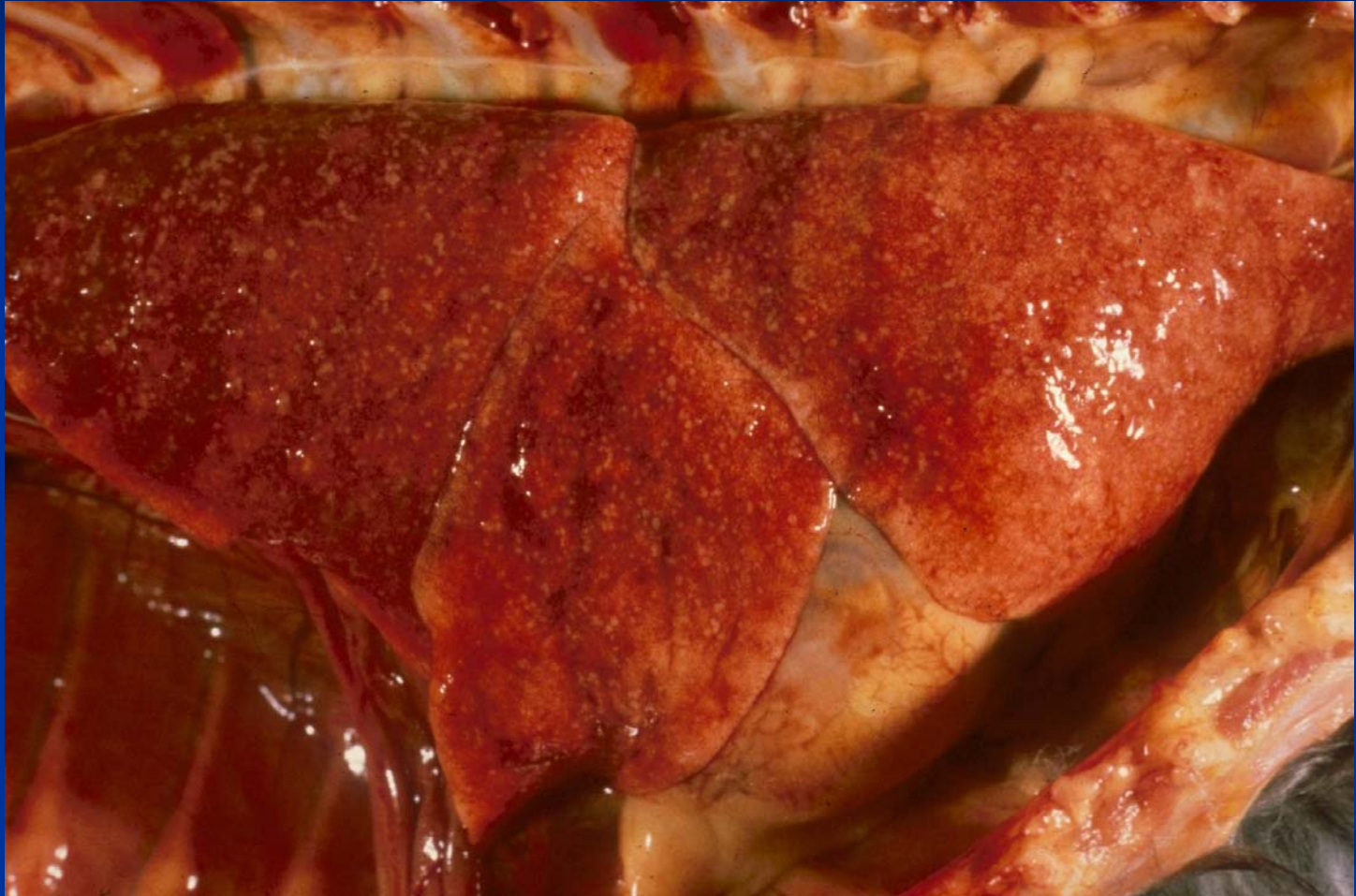Diseases of the Pleura and Thoracic Cavity

- Pneumothorax
 - Lungs are atelectatic
 - Rupture of *Paragonimus* cysts
 - Trauma, may be iatrogenic
- Hydro-, Chylo-, Hemo-thorax
- Pleuritis/Pyothorax
- Neoplasia - mesothelioma

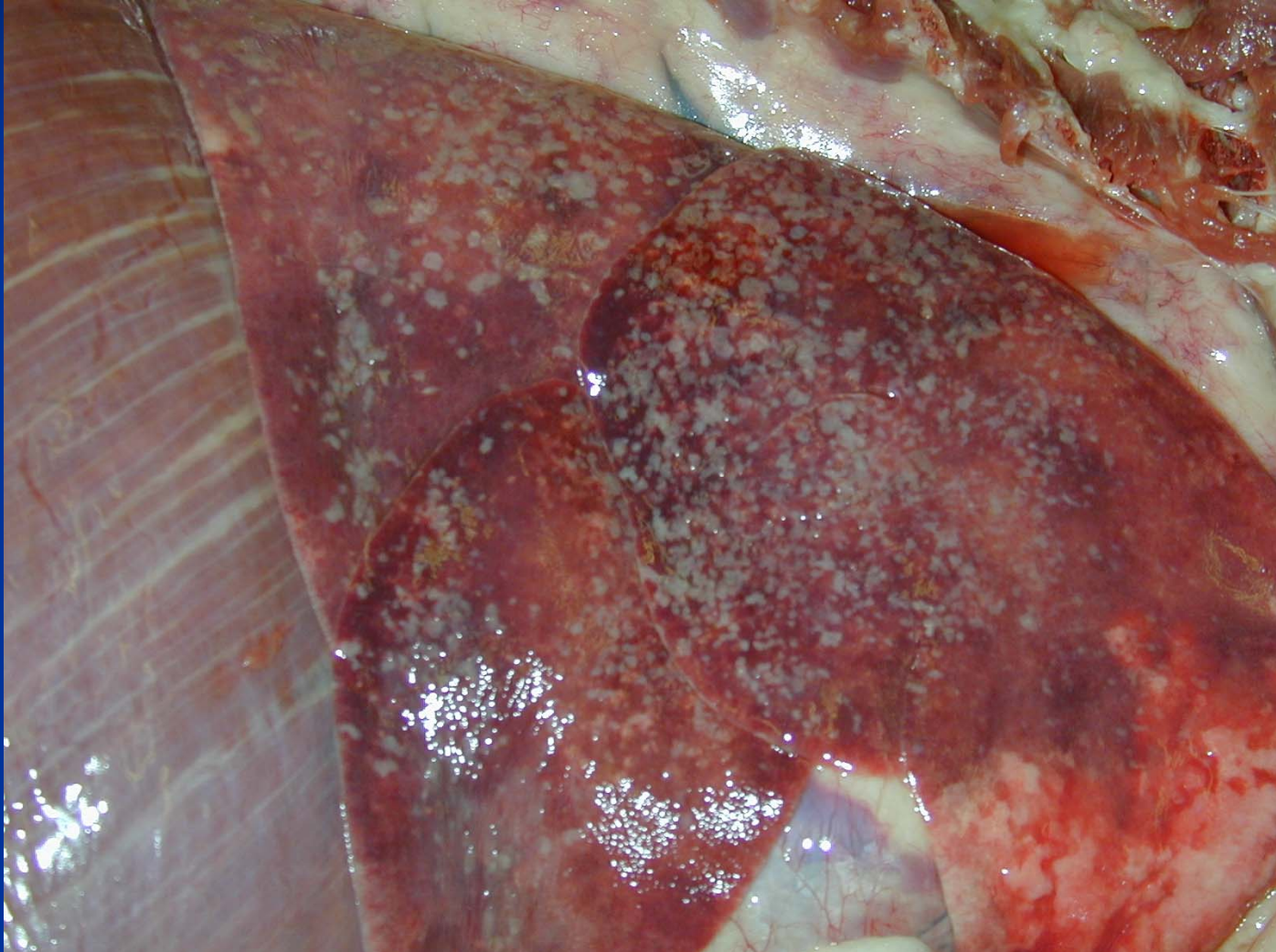Primary Pleuritis

- Viral
 - Feline Infectious Peritonitis - cats
 - Immune complex vasculitis
 - Cats imported into Australia to star in Babe II movie (personal communication)
- Bacterial
 - *Nocardia*, *Actinomyces*, *Bacteriodes* spp.
 - Pygranulomatous pleuritis
 - Blood stained exudate (“tomato soup”) with sulfur granules
- Mycotic – *Aspergillus* sp

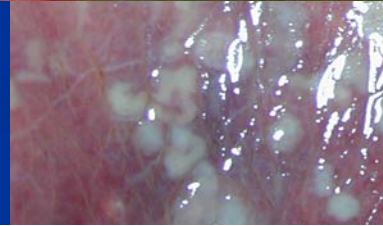
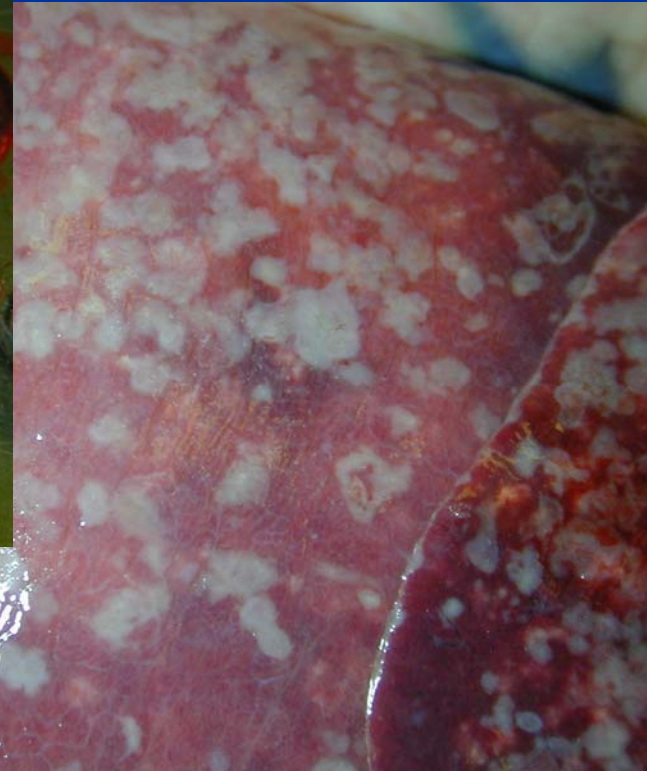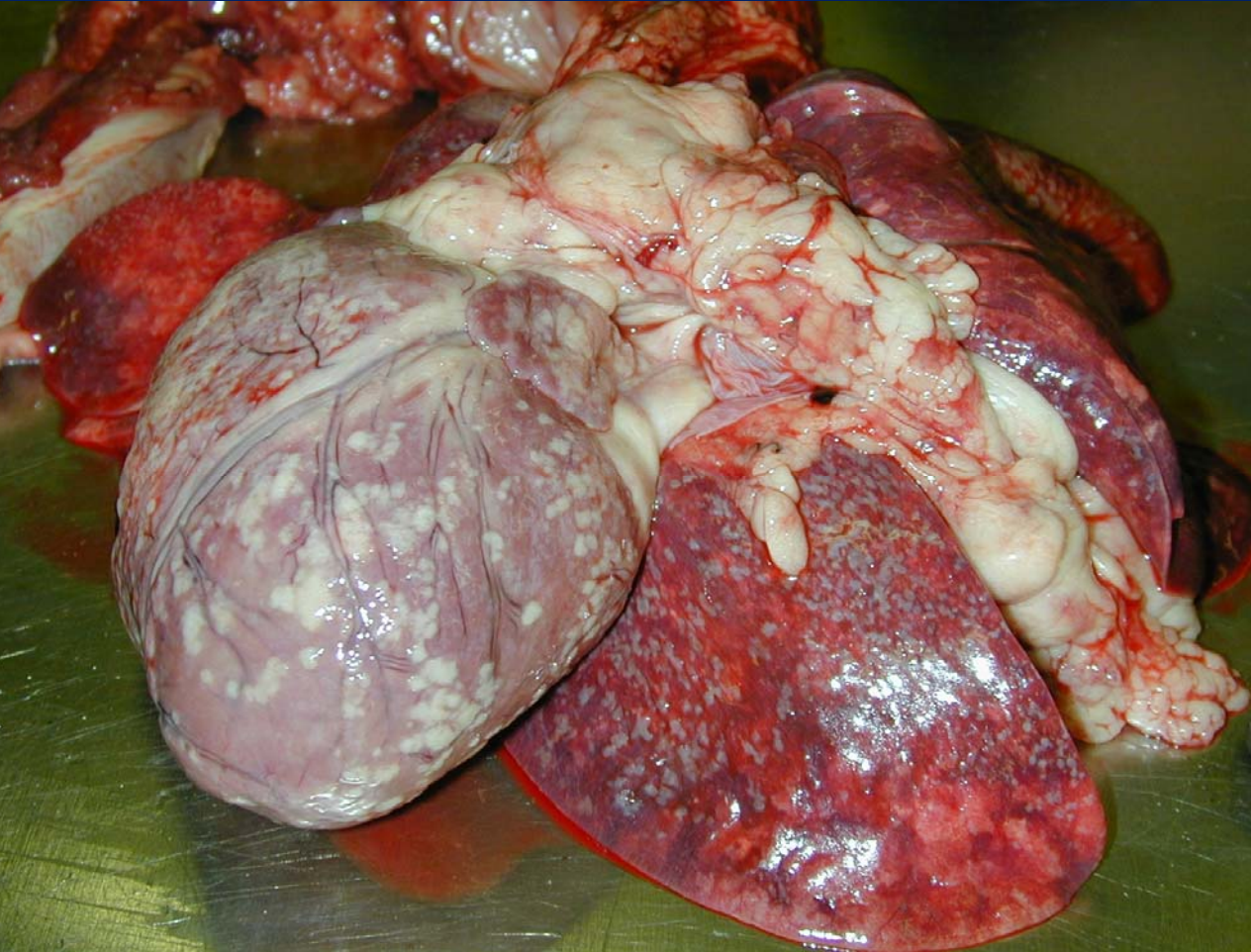Primary Pleuritis - FIP



Aspergillosis - Dog



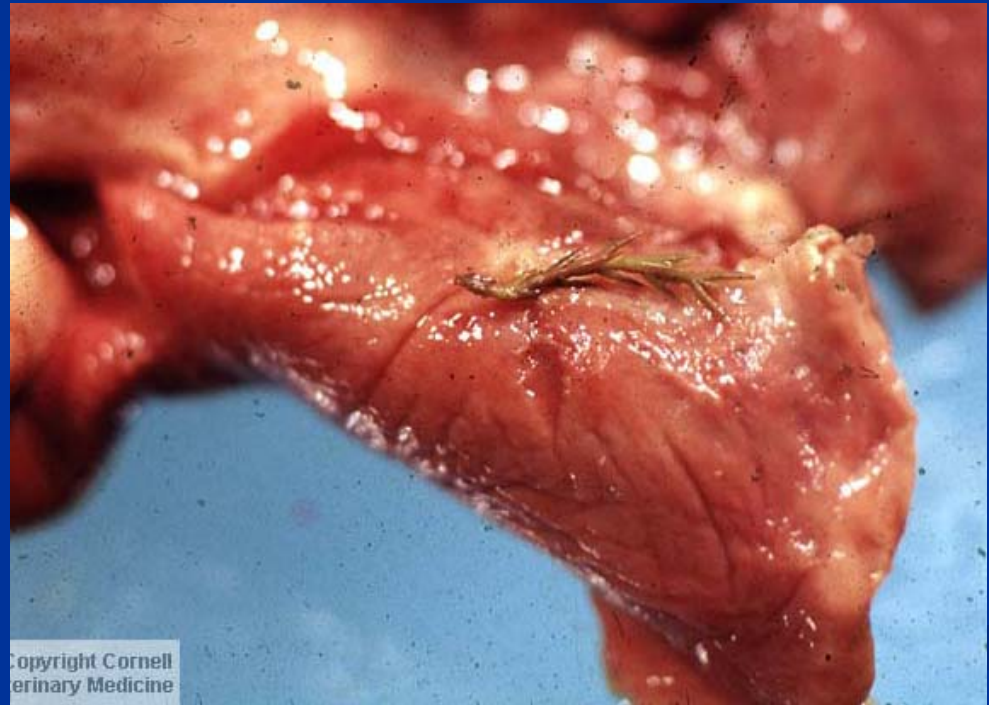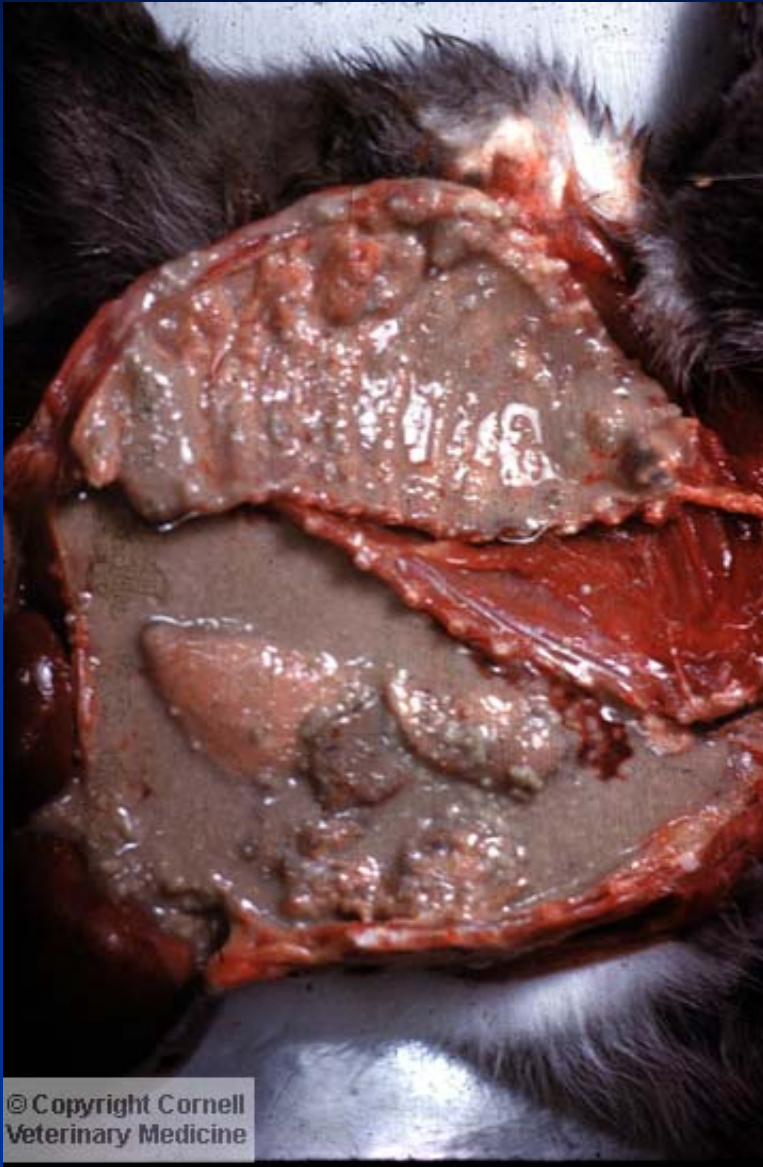
Aspergillosis



Secondary Pleuritis/Pyothorax

- Extension of pneumonia
- Traumatic penetration
 - Awns
 - Bite wounds
- Ruptured lung abscess
- Pyothorax usually has mixture of bacteria
 - *A. pyogenes*, *P. multocida*, *F. necrophorum*

Pyothorax— Traumatic Penetration - Cat



Awn that Migrated in a Cat Causing Pleuritis

