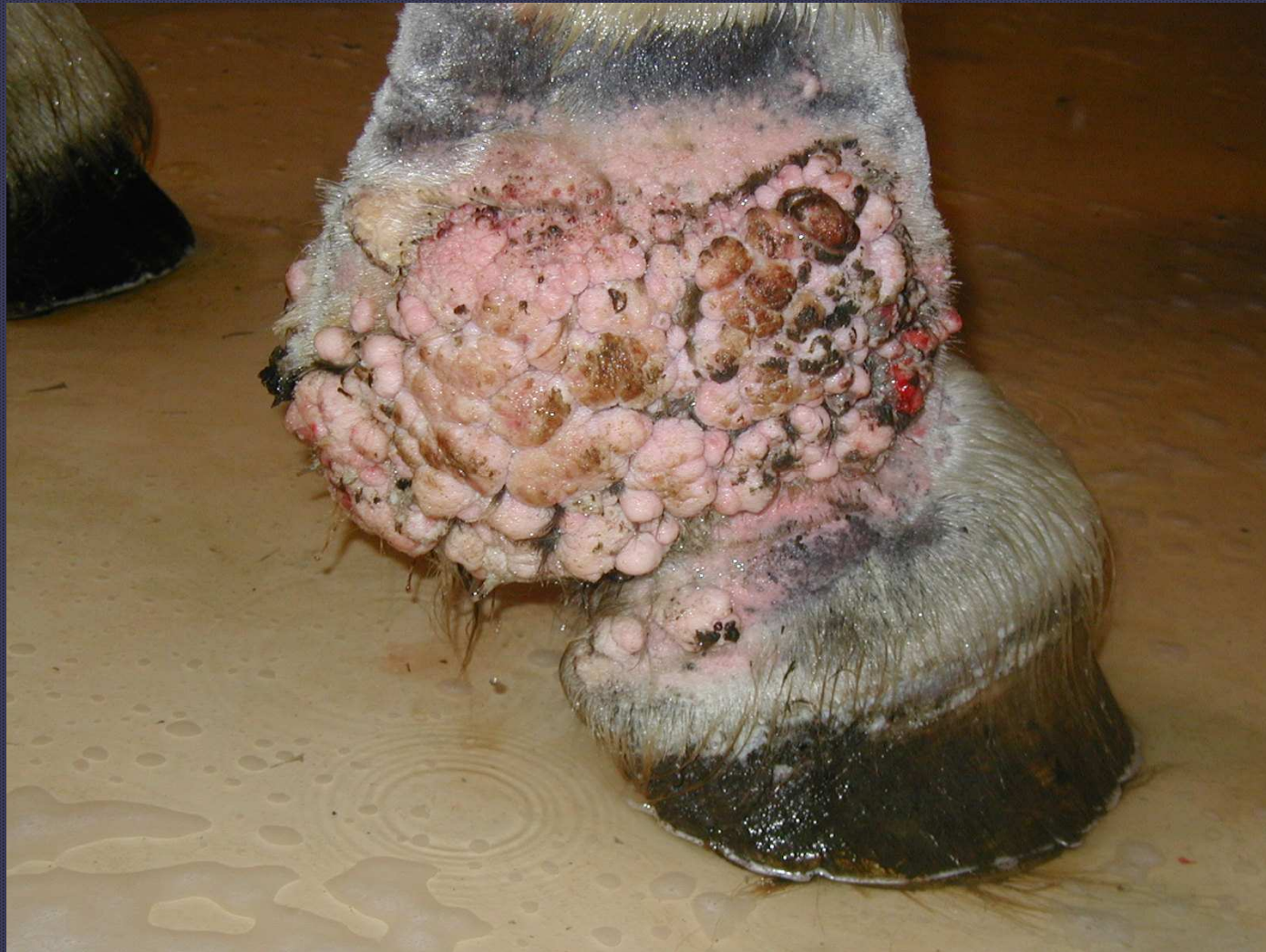
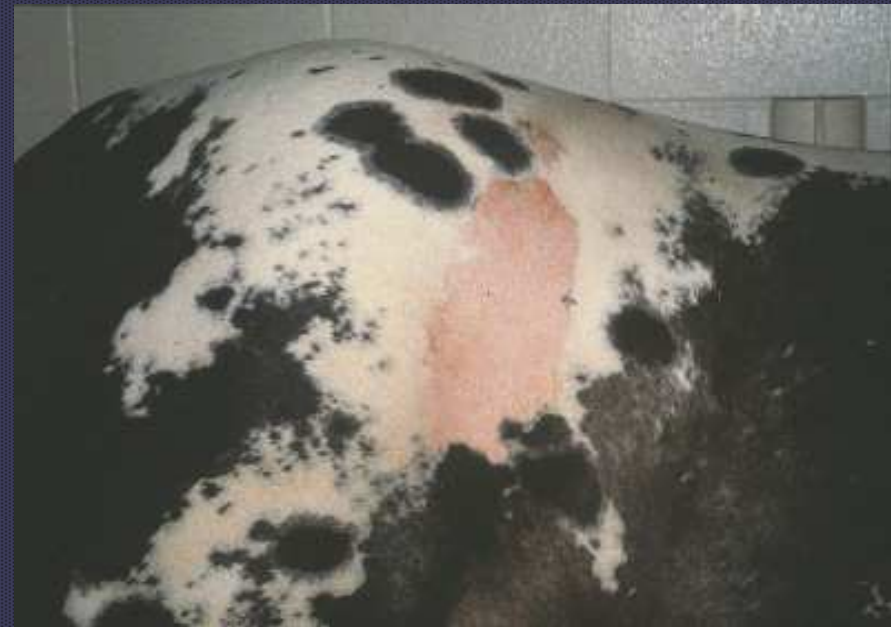
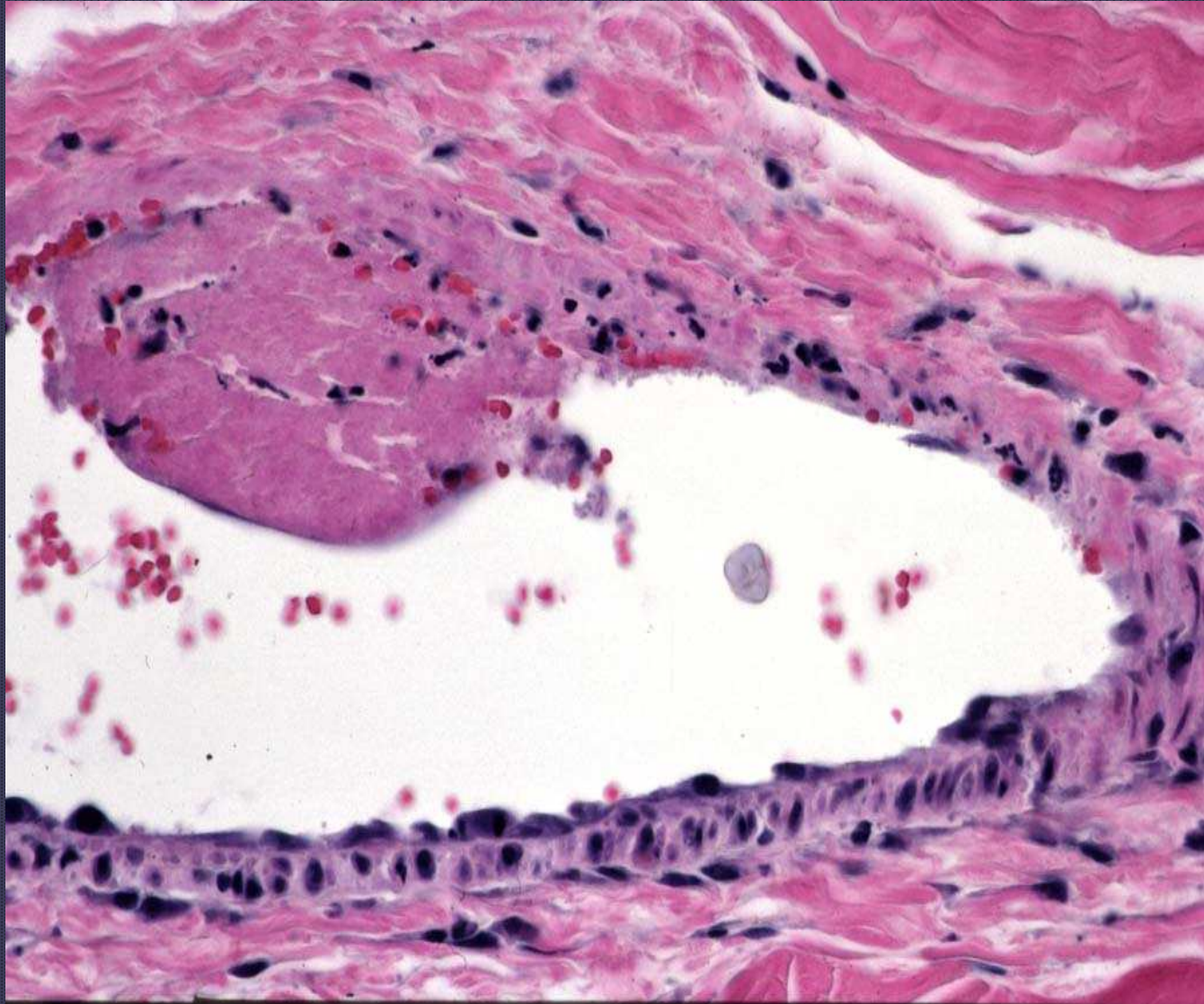


Idiopathic pastern dermatitis in a draft horse


# Photosensitization

- Type I: Secondary to injection of photosensitizing agent
- Type II: Congenital
- Type III: Acquired from liver damage

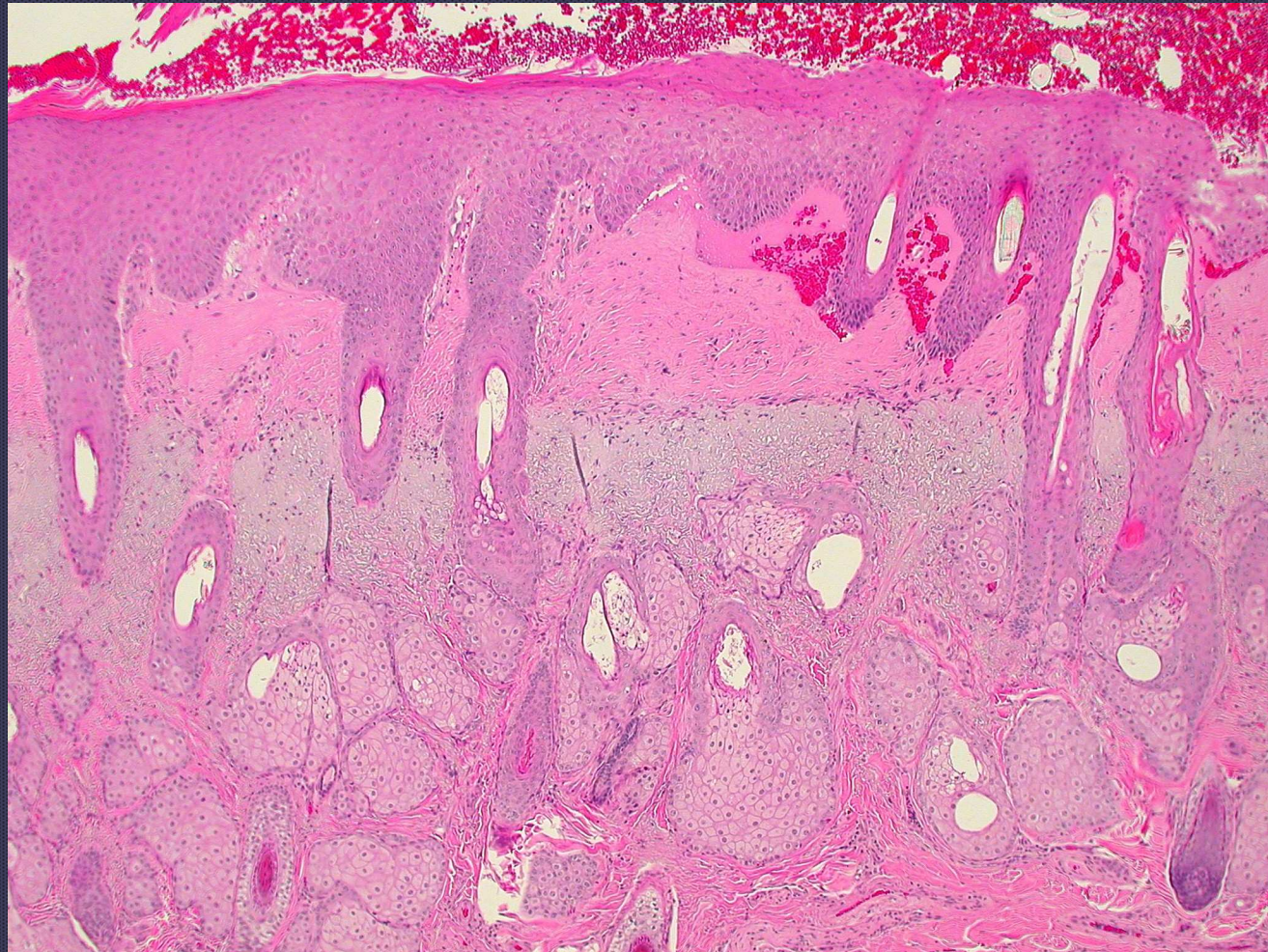




*Vasculitis due to photosensitization*



Photosensitization



Solar elastosis