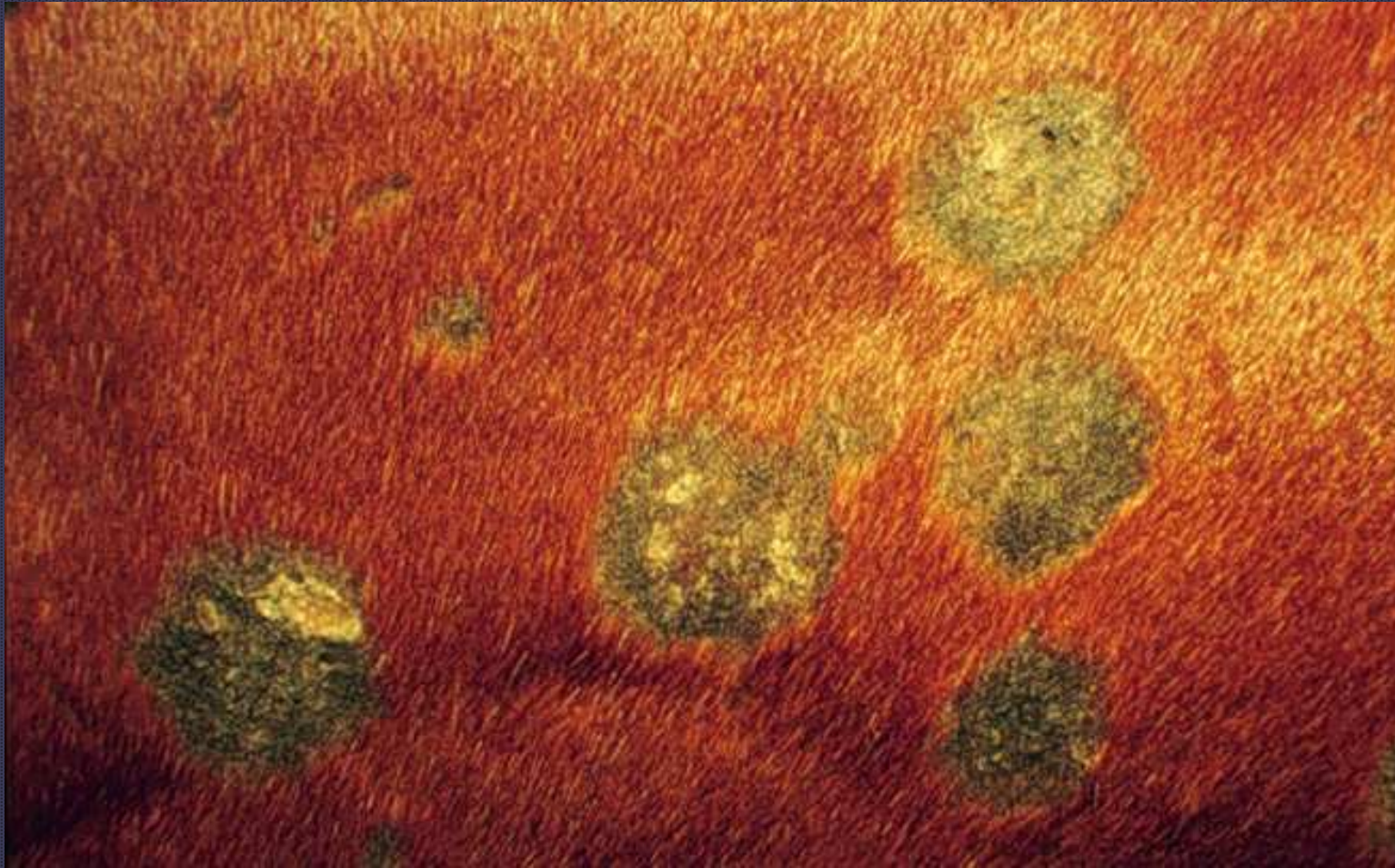
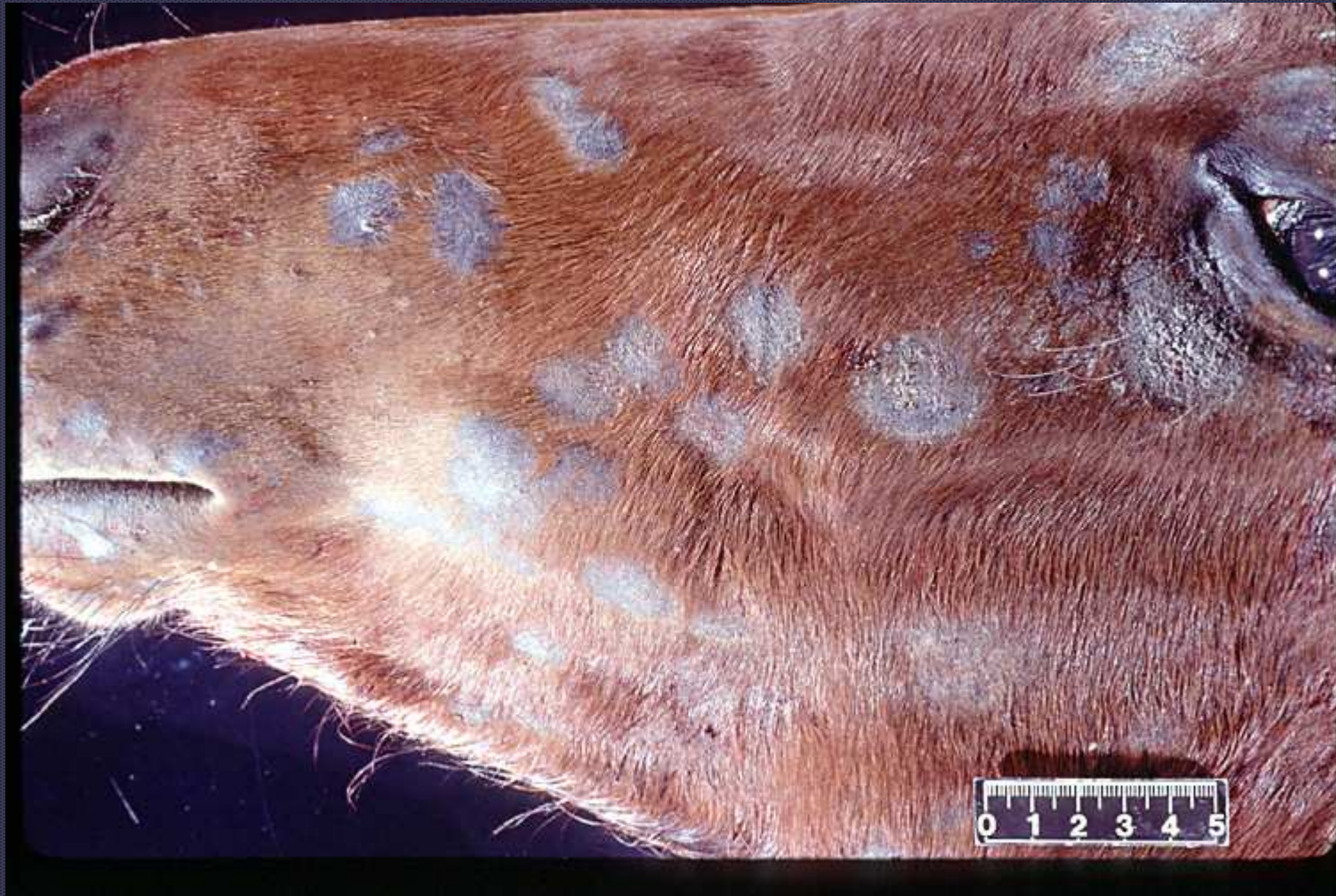

# Mane and Tail Dystrophy

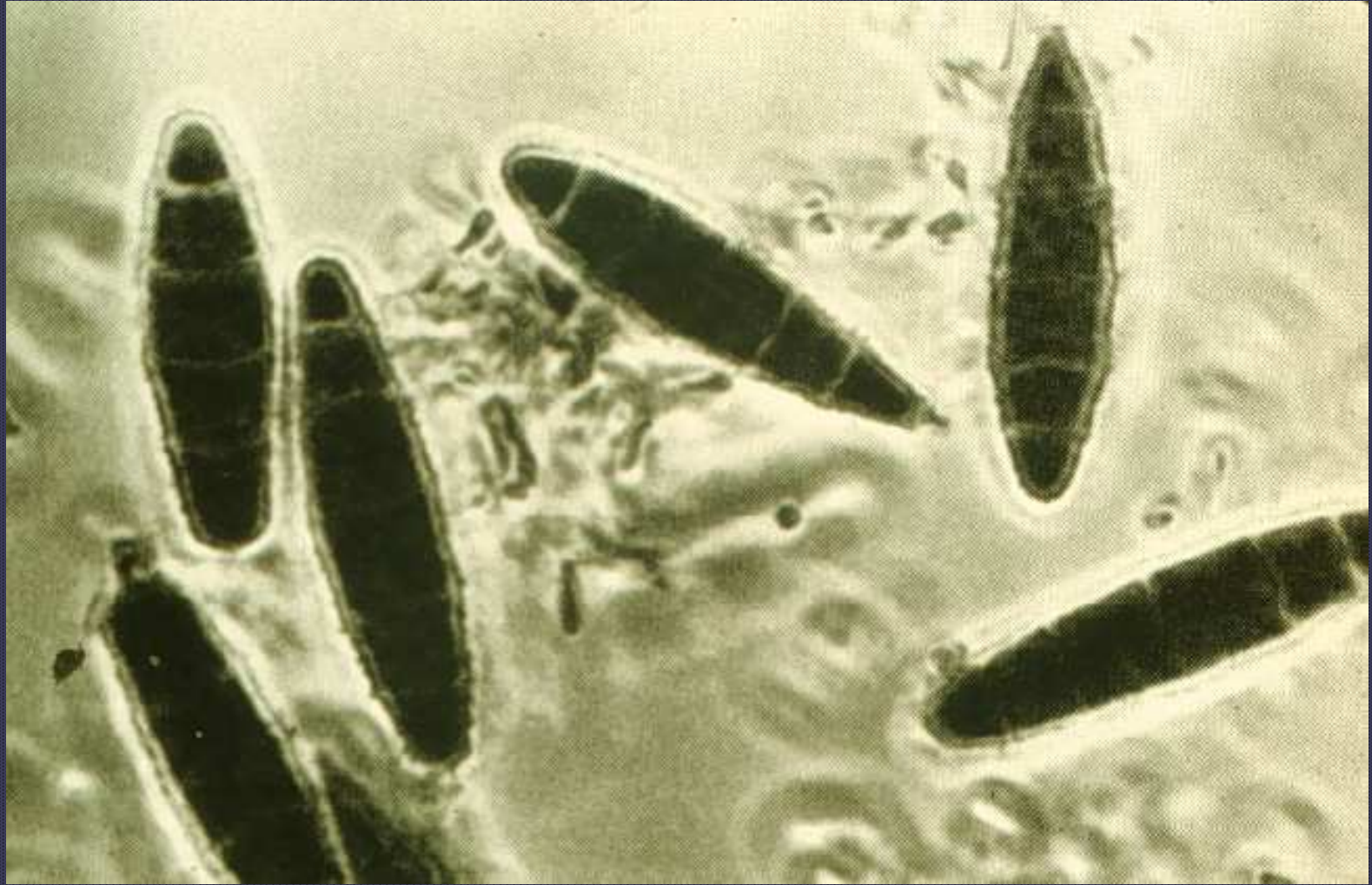
- Recognized at birth or few weeks of age
- Short, brittle hair
- Abnormally shaped follicles with dystrophic shafts



Dermatophytosis



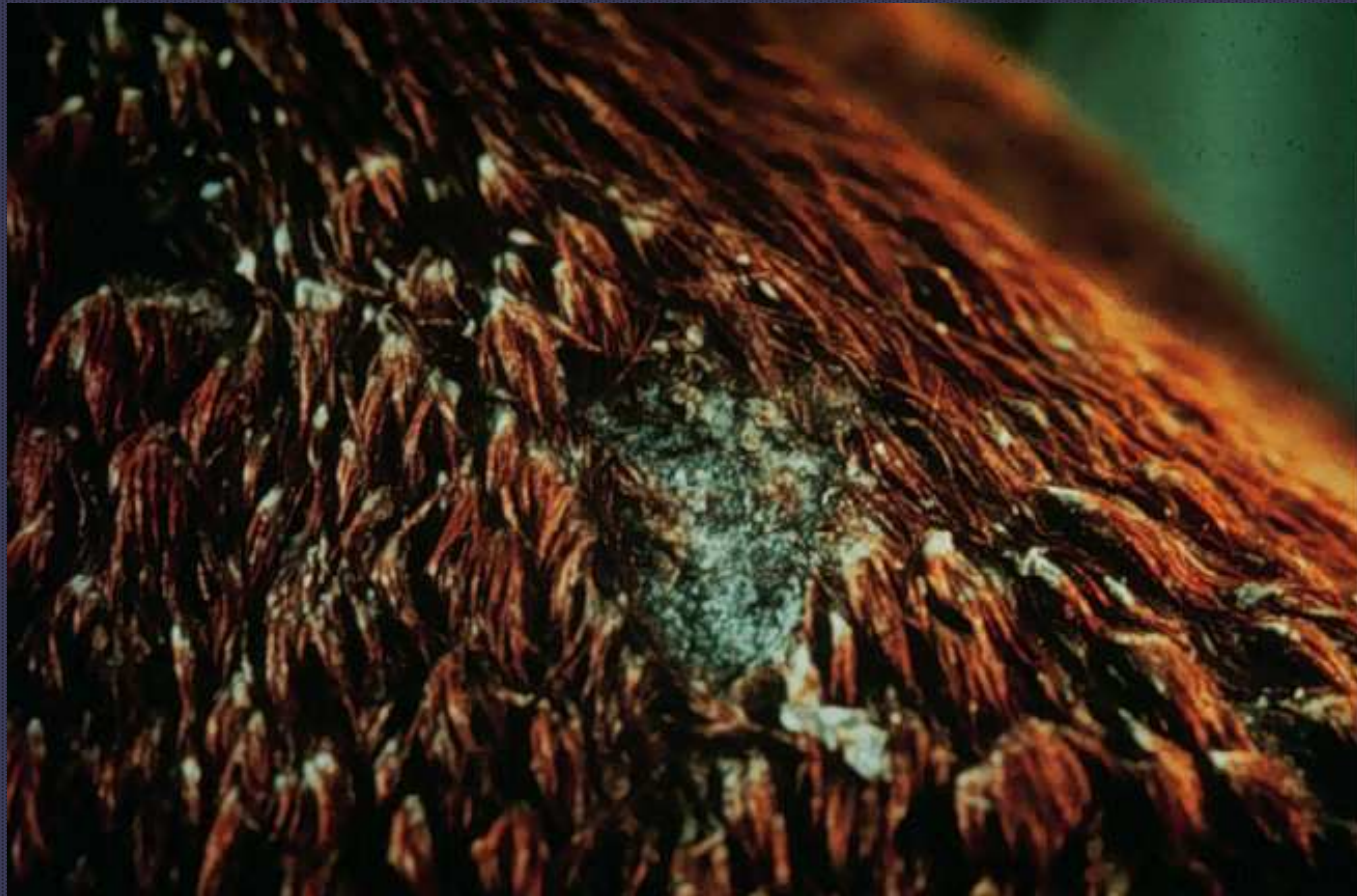Dermatophytosis



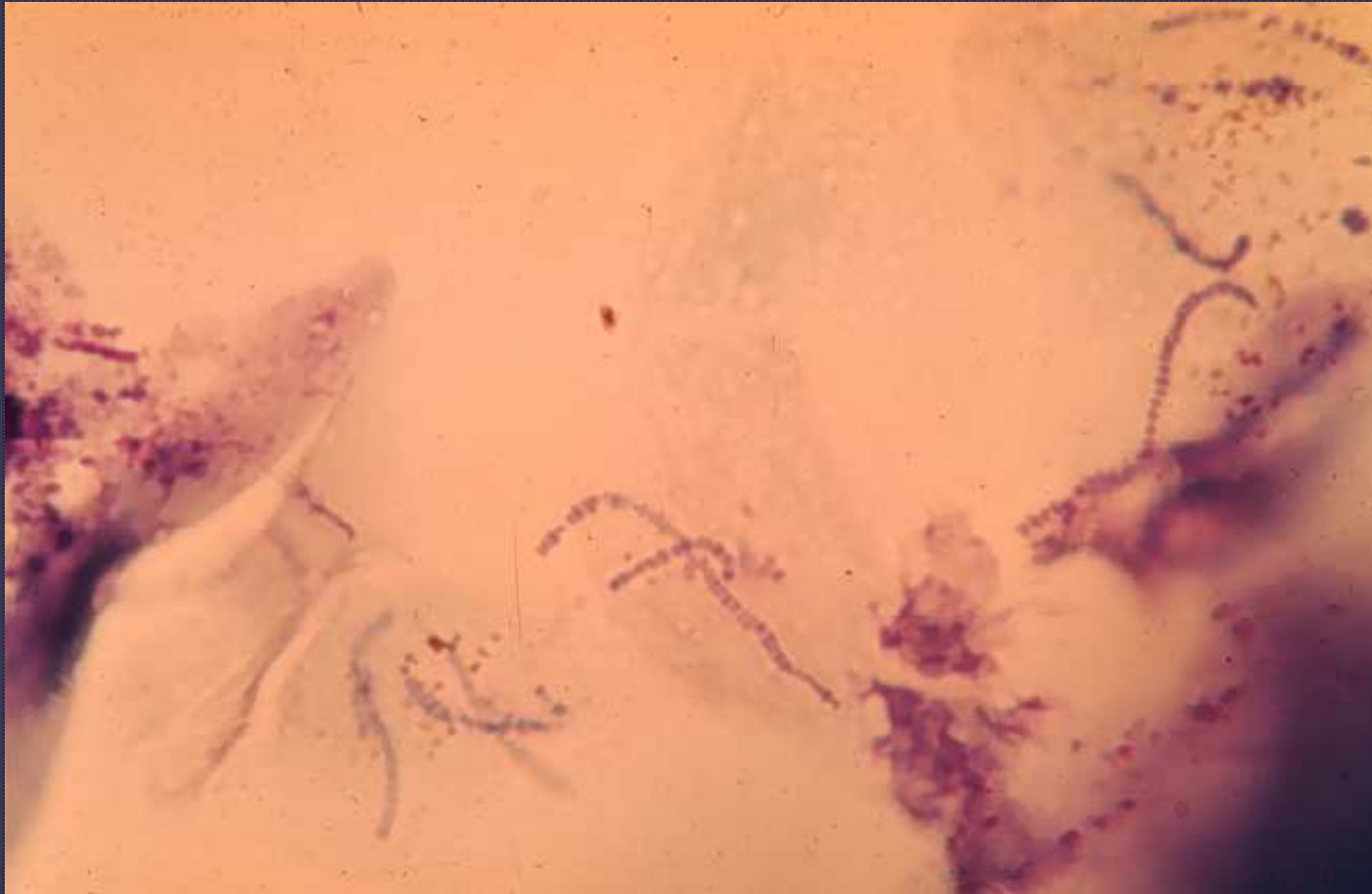
*Trichophyton sp.*



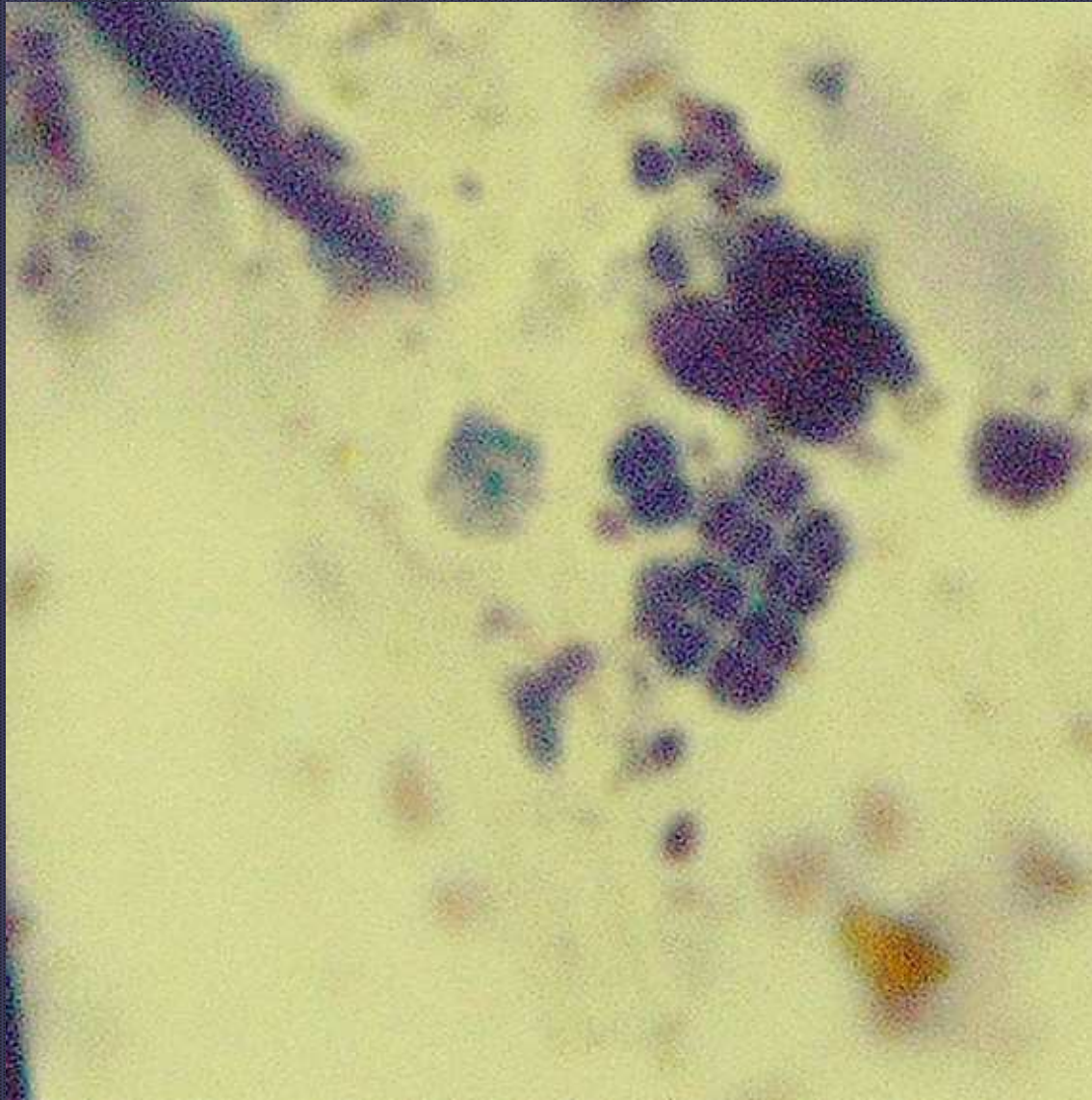
Dermatophilosis



Dermatophilosis

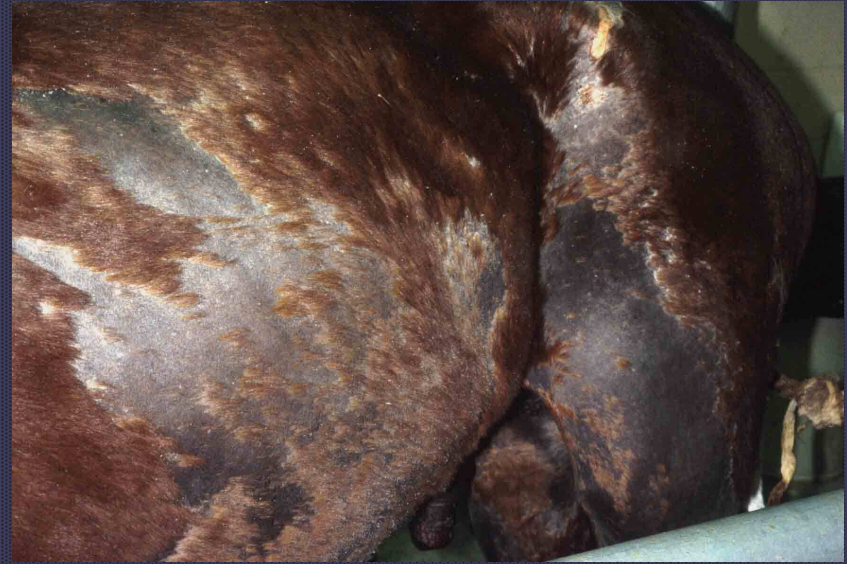

*Dermatophilus congolensis*

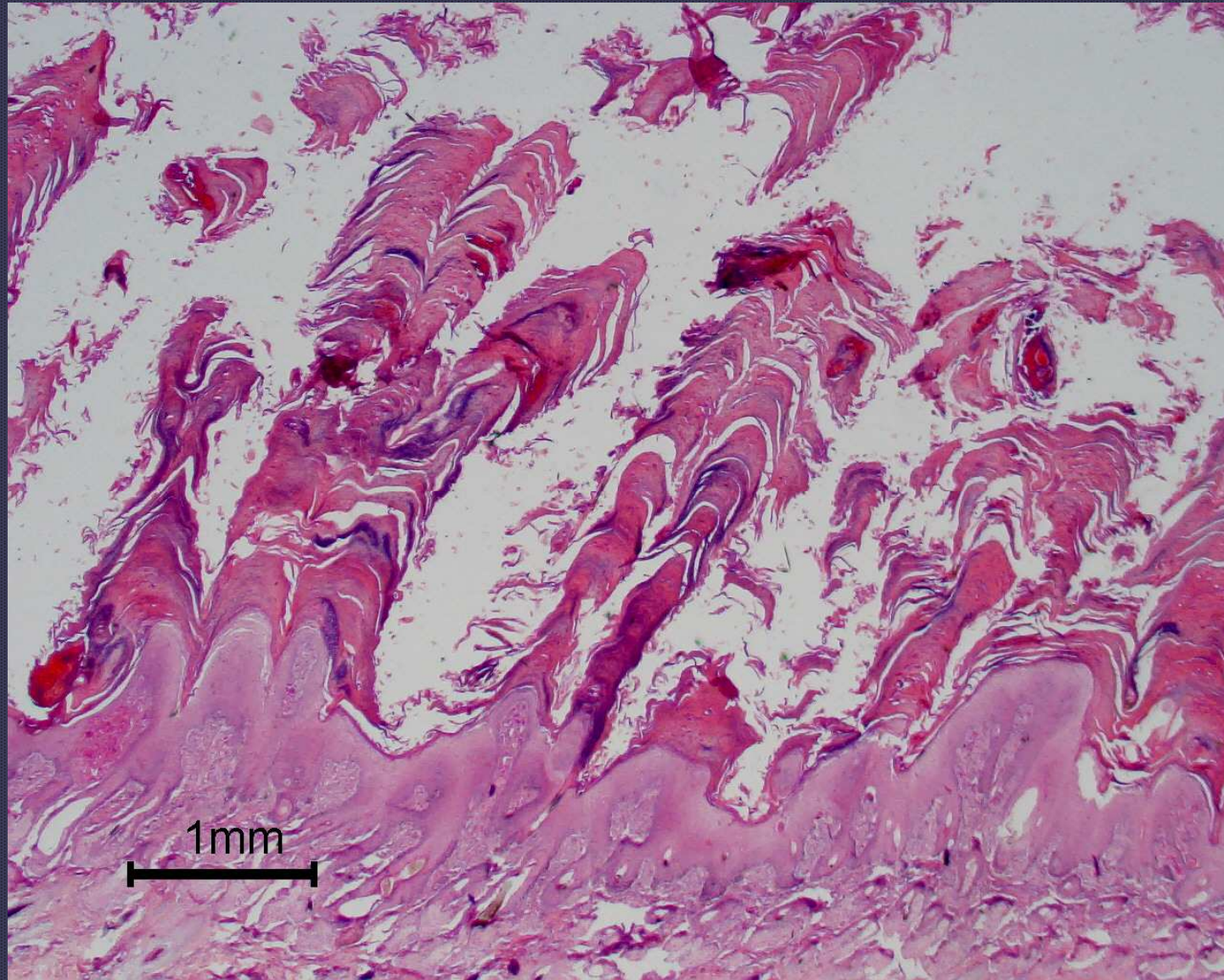


*Dermatophilus congolensis*





Dermatophilosis



Dermatophilosis