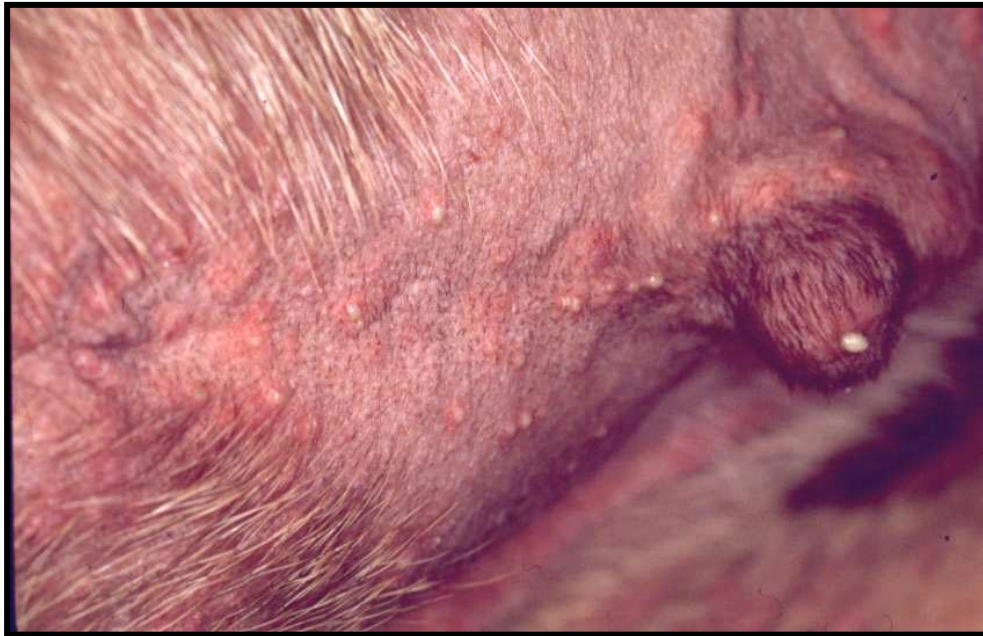


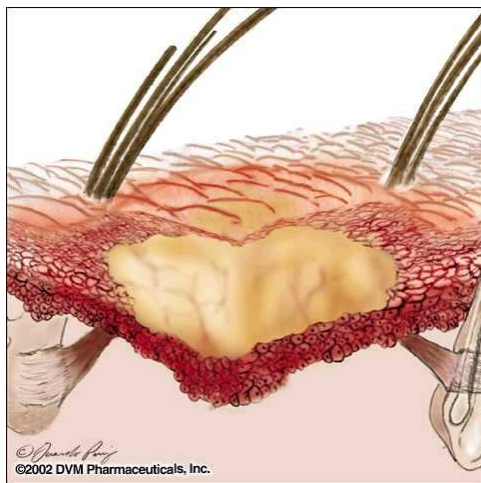


Pin-point sized pustules on groin of a dog with bacterial folliculitis

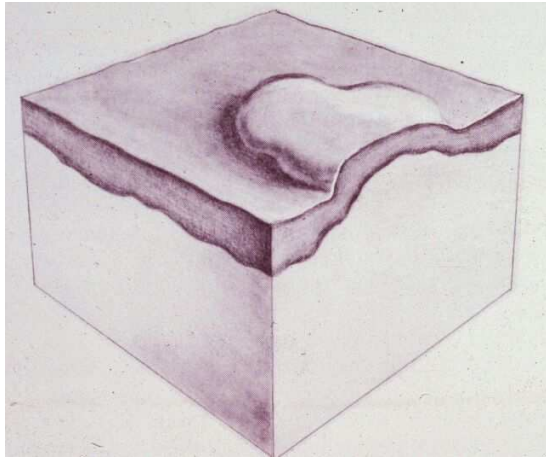


Scores of large (5mm) pustules erupting on the abdomen of a dog with pemphigus foliaceus (below)

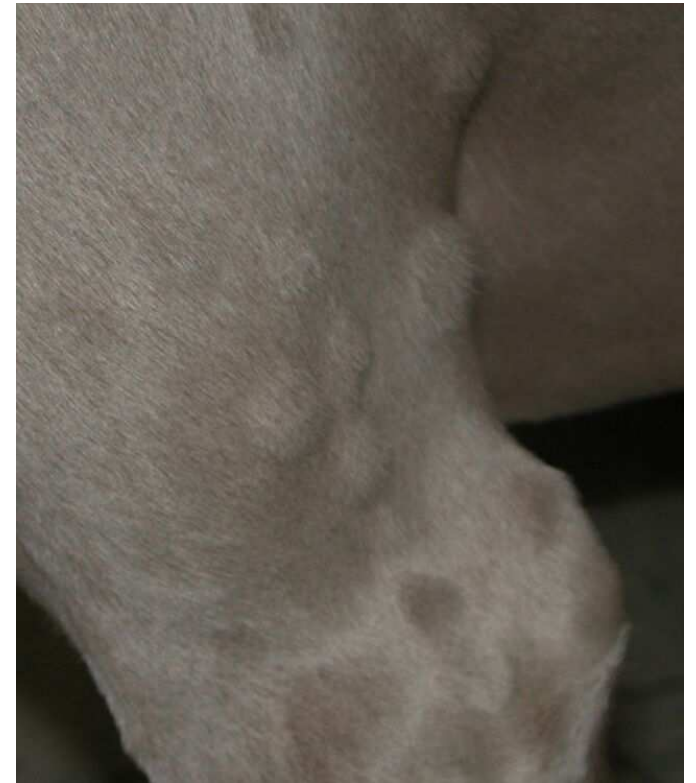Schematic drawing of an intraepidermal pustule



Wheal



Wheals (urticaria) are due either to plasma leakage, or to overt hemorrhage.



↗
Urticaria due to insect hypersensitivity in a Weimeraner

←
Urticaria due to *Culicoides* spp. hypersensitivity in a horse