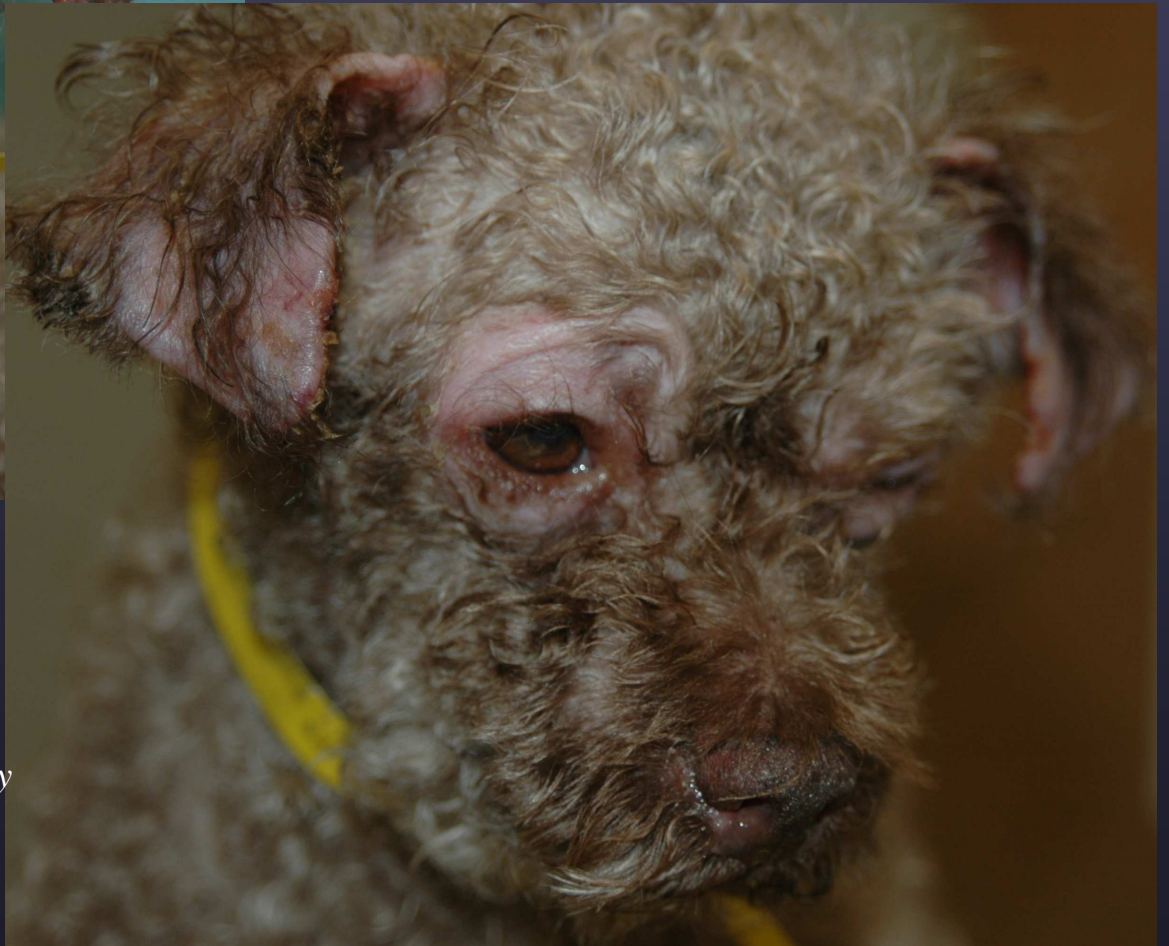
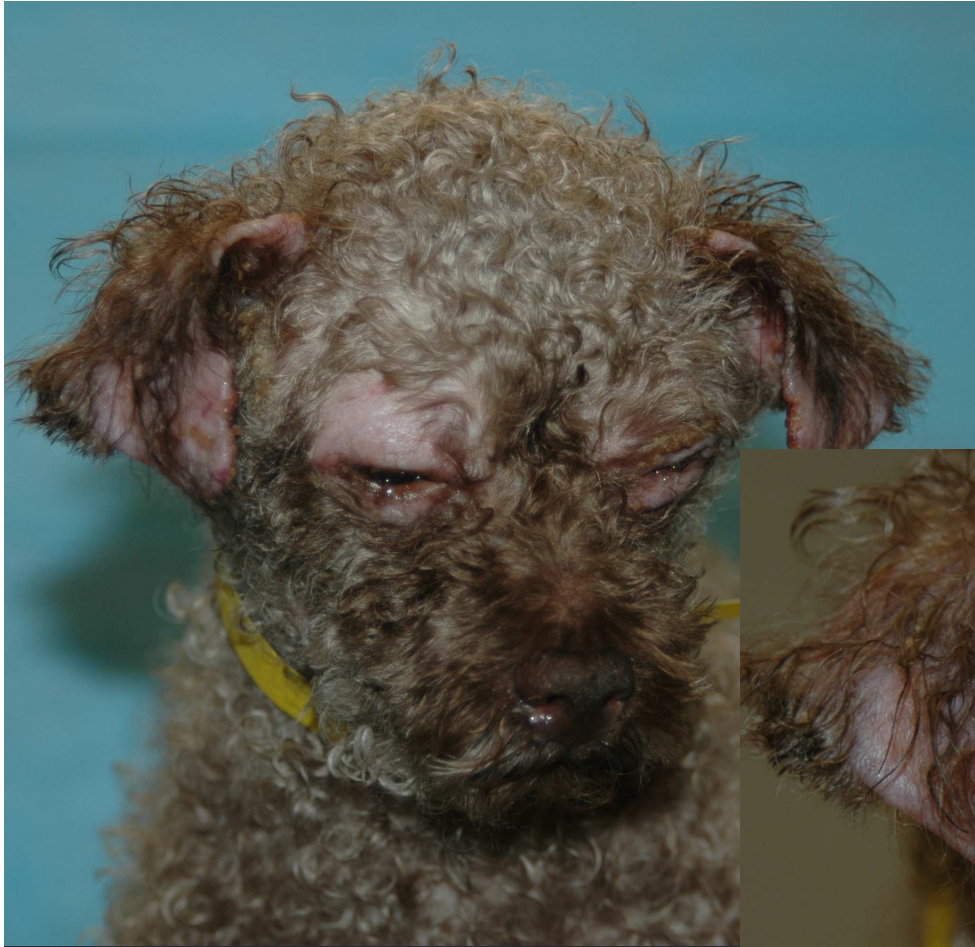
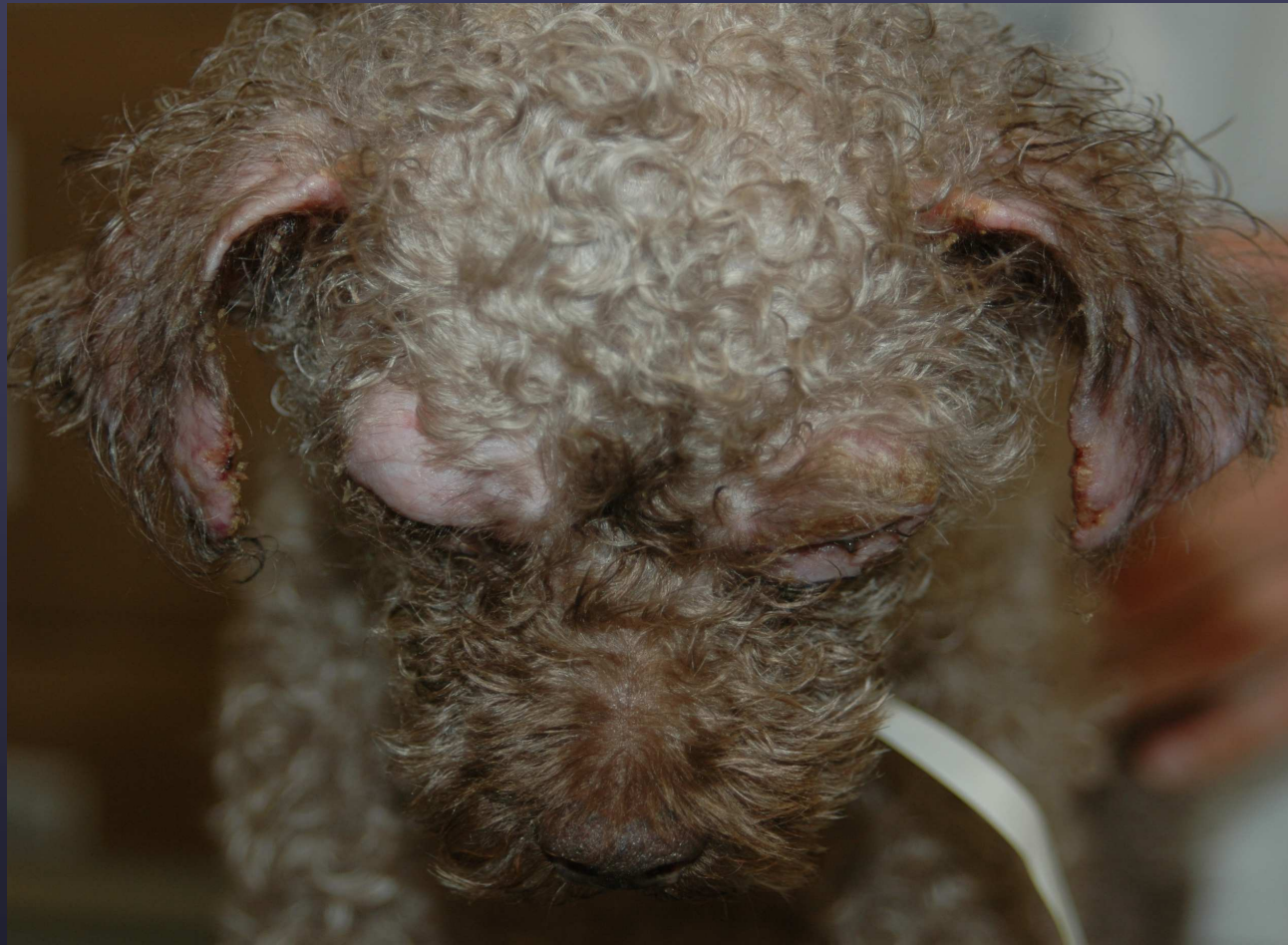
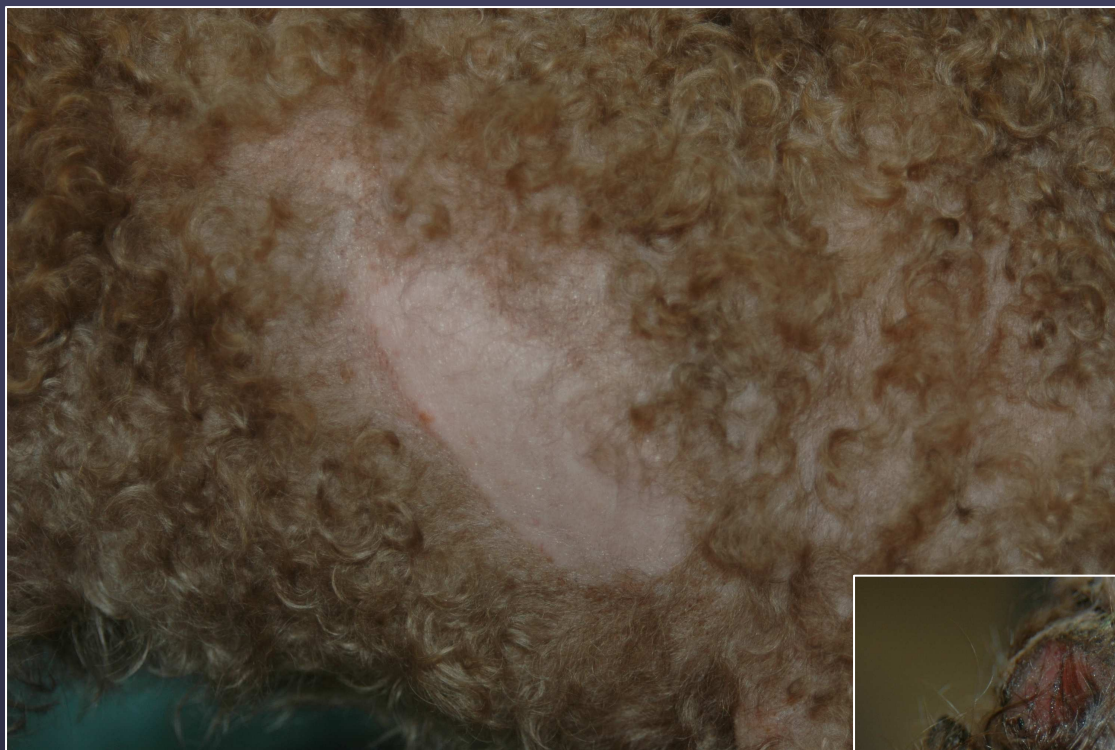
*Dog with generalized ischemic dermatopathy
associated with rabies vaccine rxn*

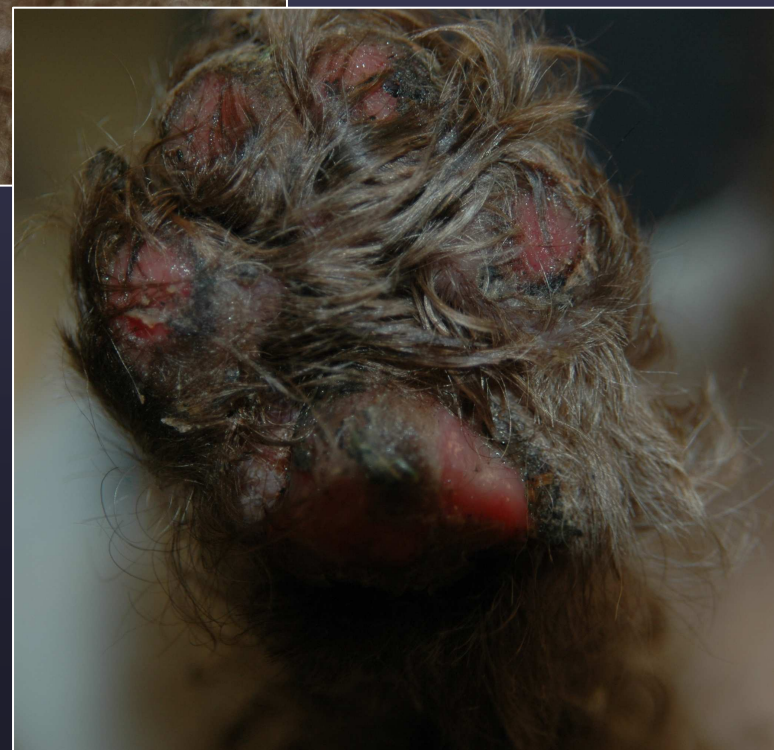


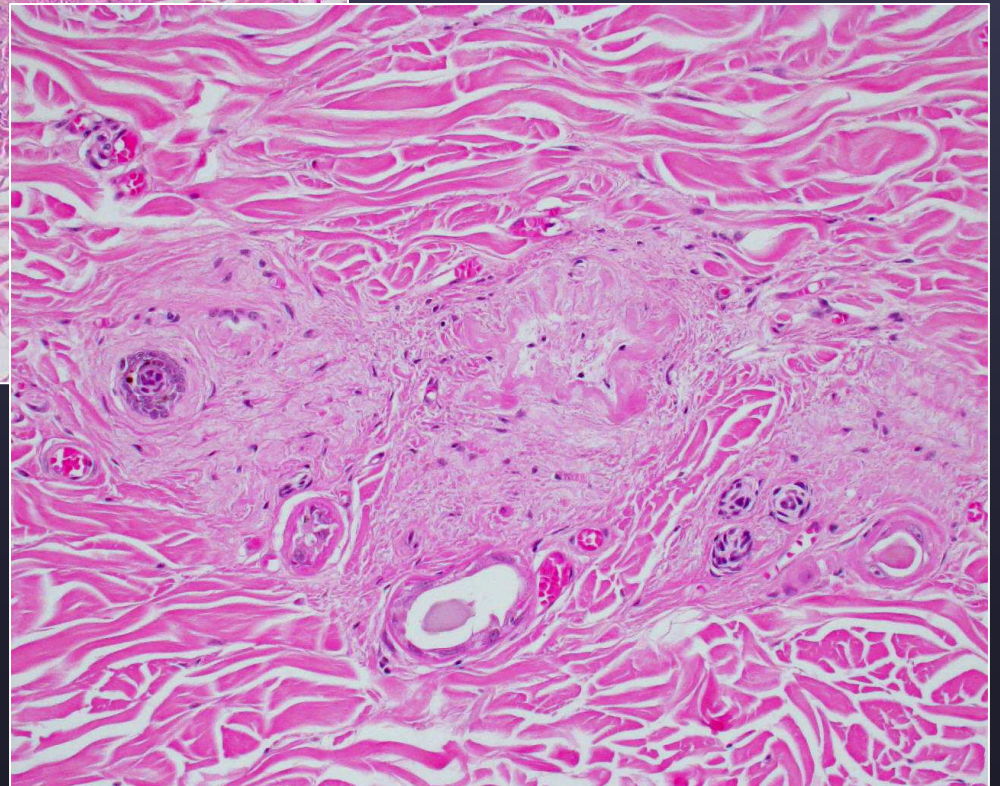
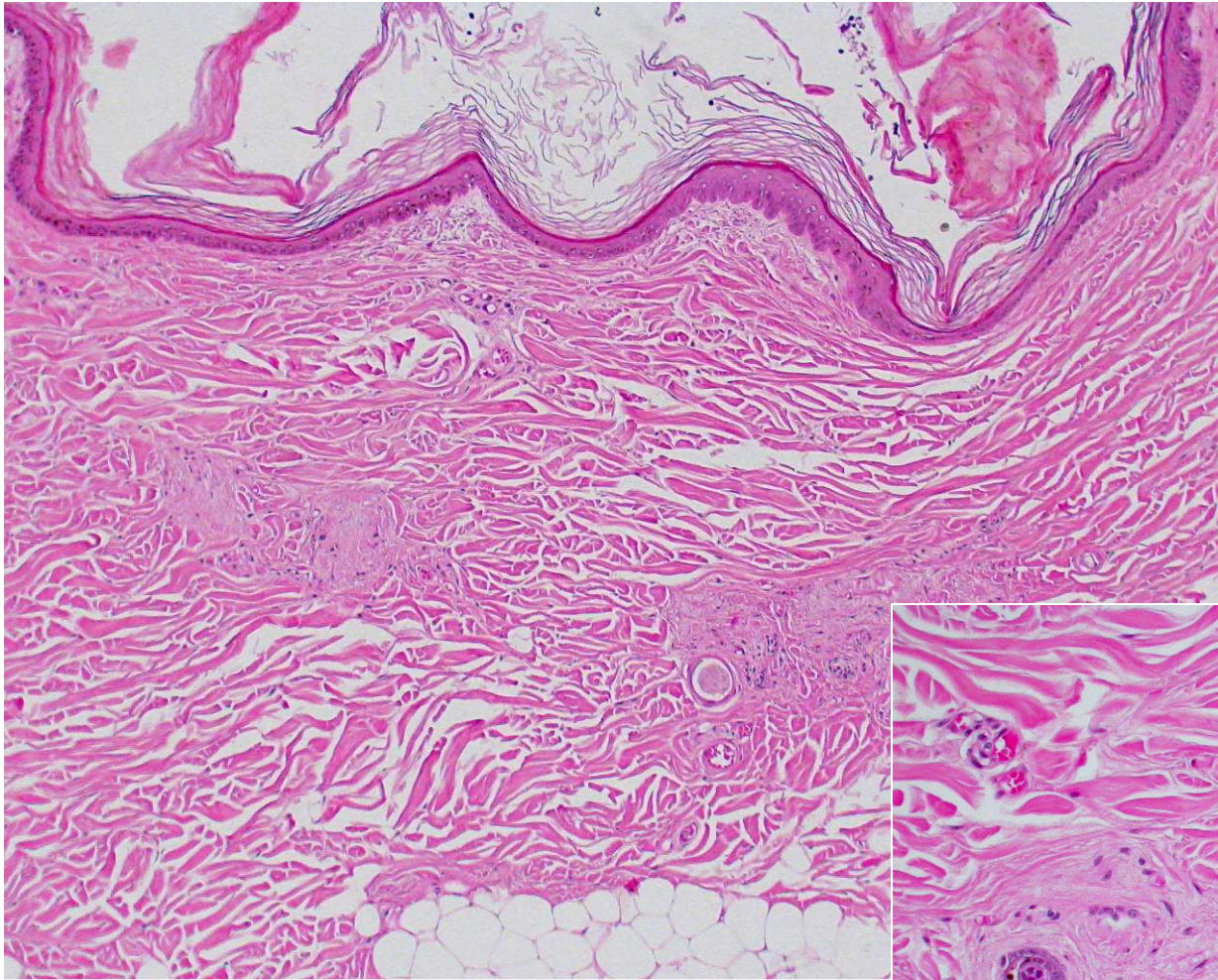
Ischemic dermatopathy



Alopecia at vaccine site

Ischemic dermatopathy

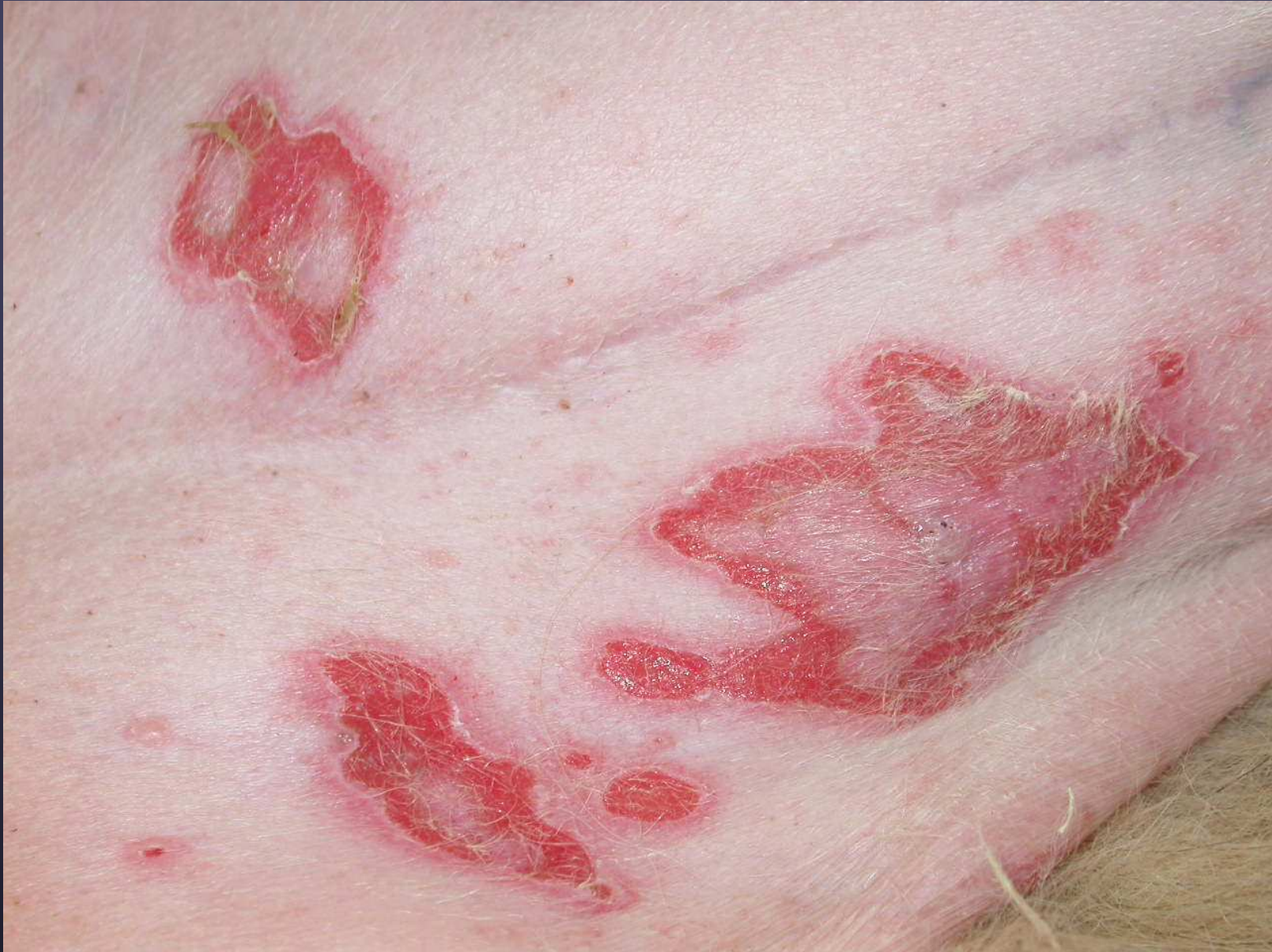



Profound follicular atrophy

Idiopathic Ulcerative dermatosis of Collies and Shelties (cutaneous vesicular LE)

- Adult-onset
- Transient vesicles with large ulcers on abdomen/inguinal area/axilla
- lesions on mucous membranes/pinna less common
- Hydropic basal cell change with scattered keratinocyte apoptosis and cleft/vesicle formation; also affects outer root sheaths
- may have mild to moderate lichenoid lymphocytic infiltrate



Vesicular lupus (aka ulcerative dermatosis) of Collie and Sheltie