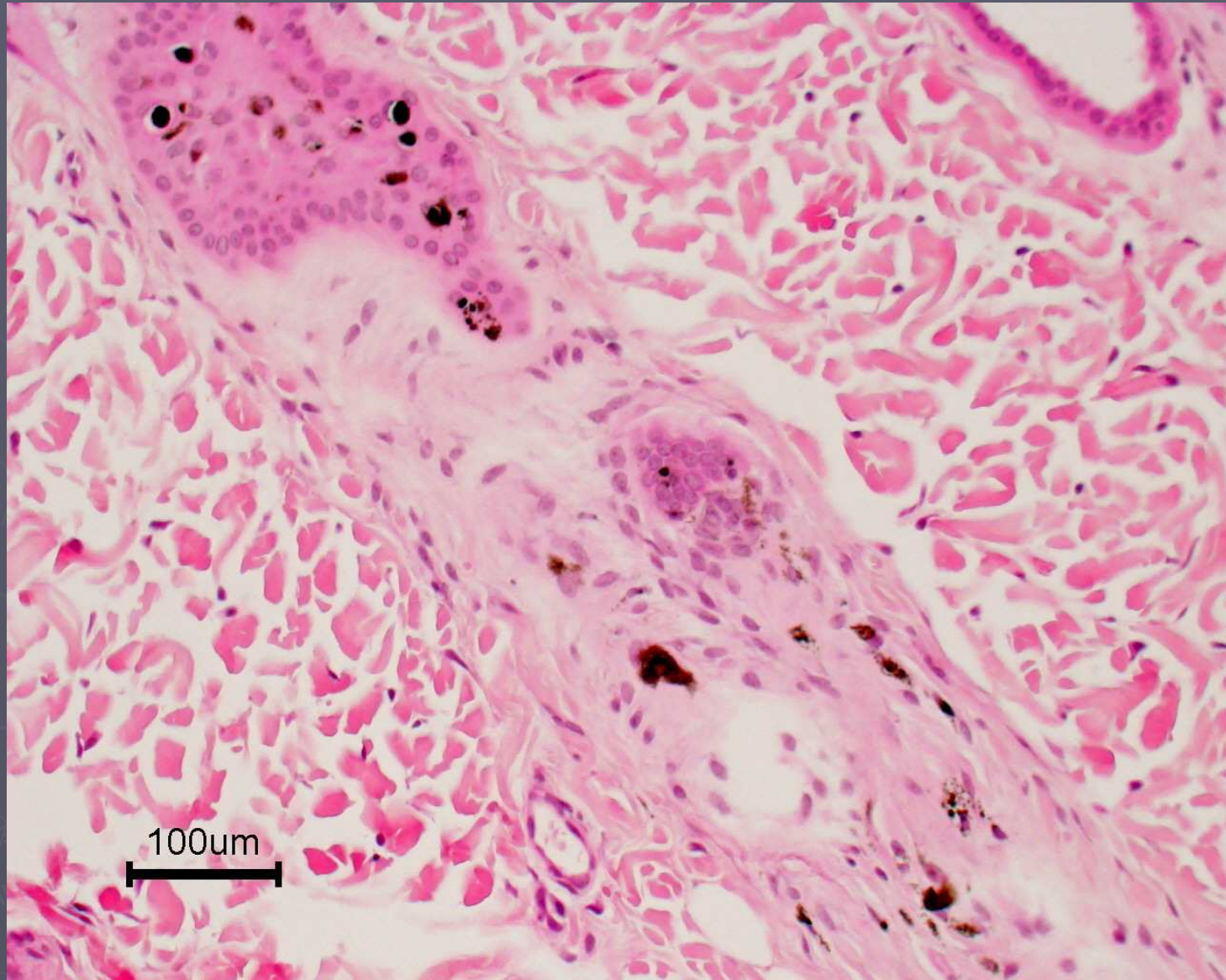
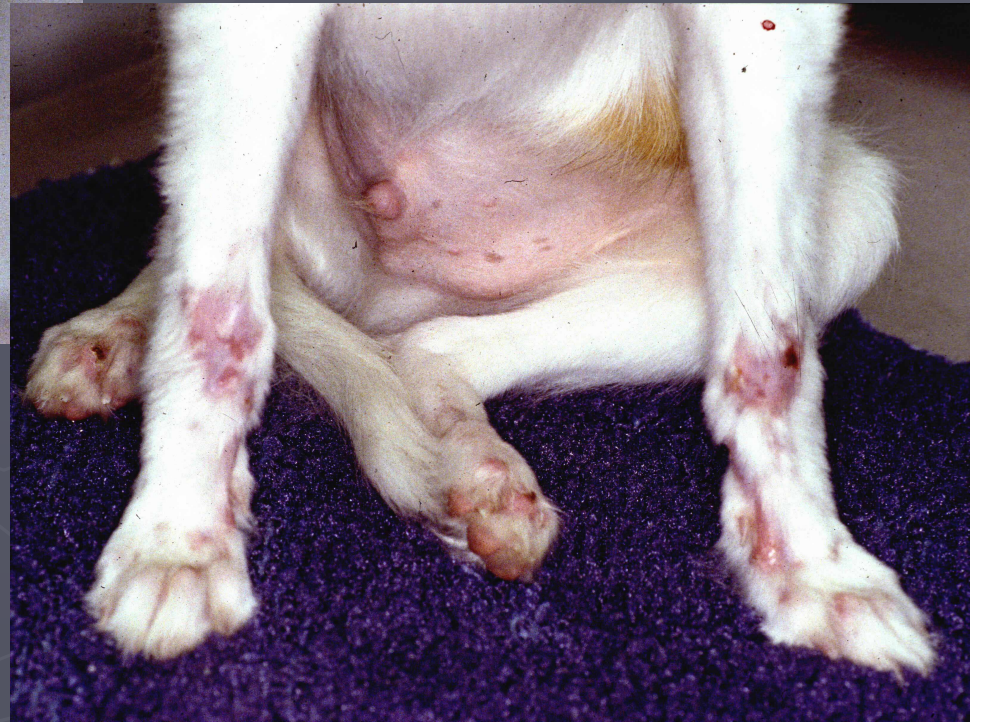
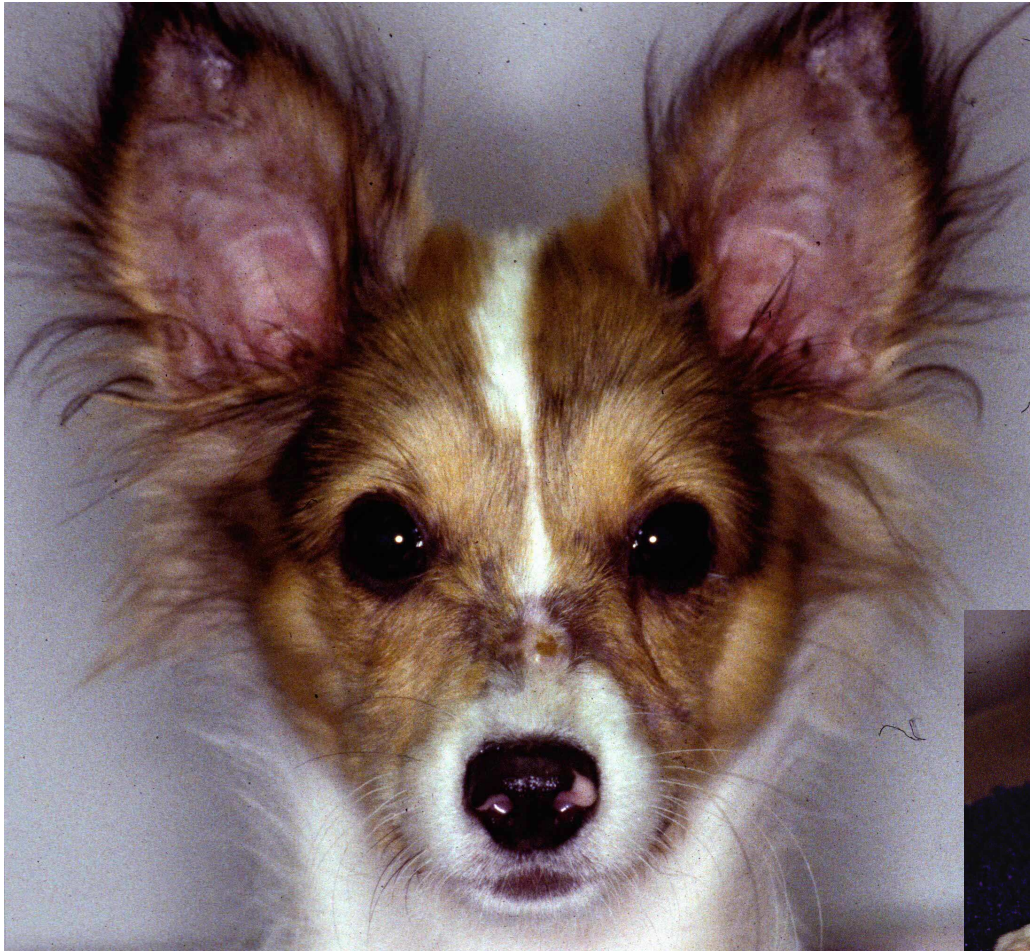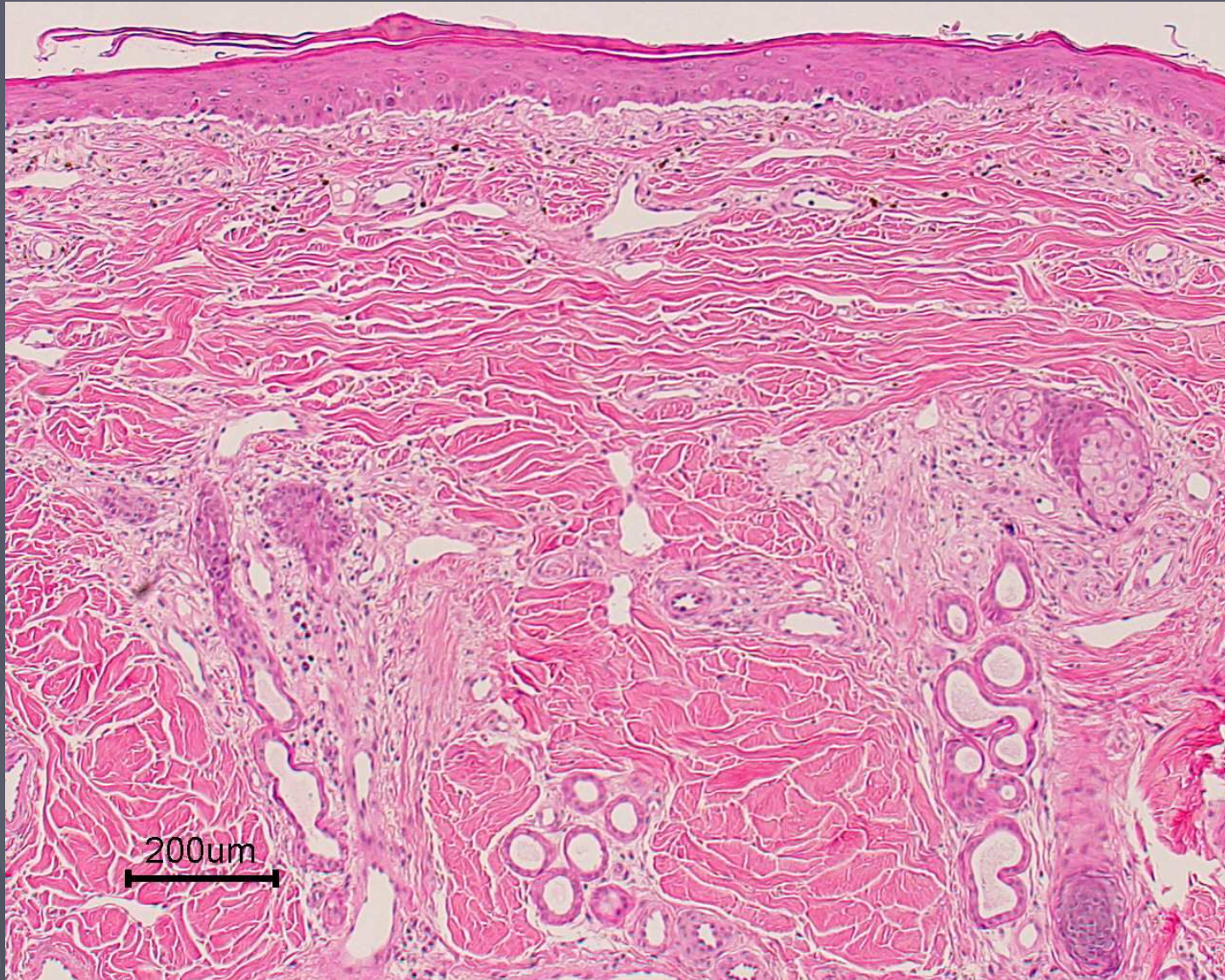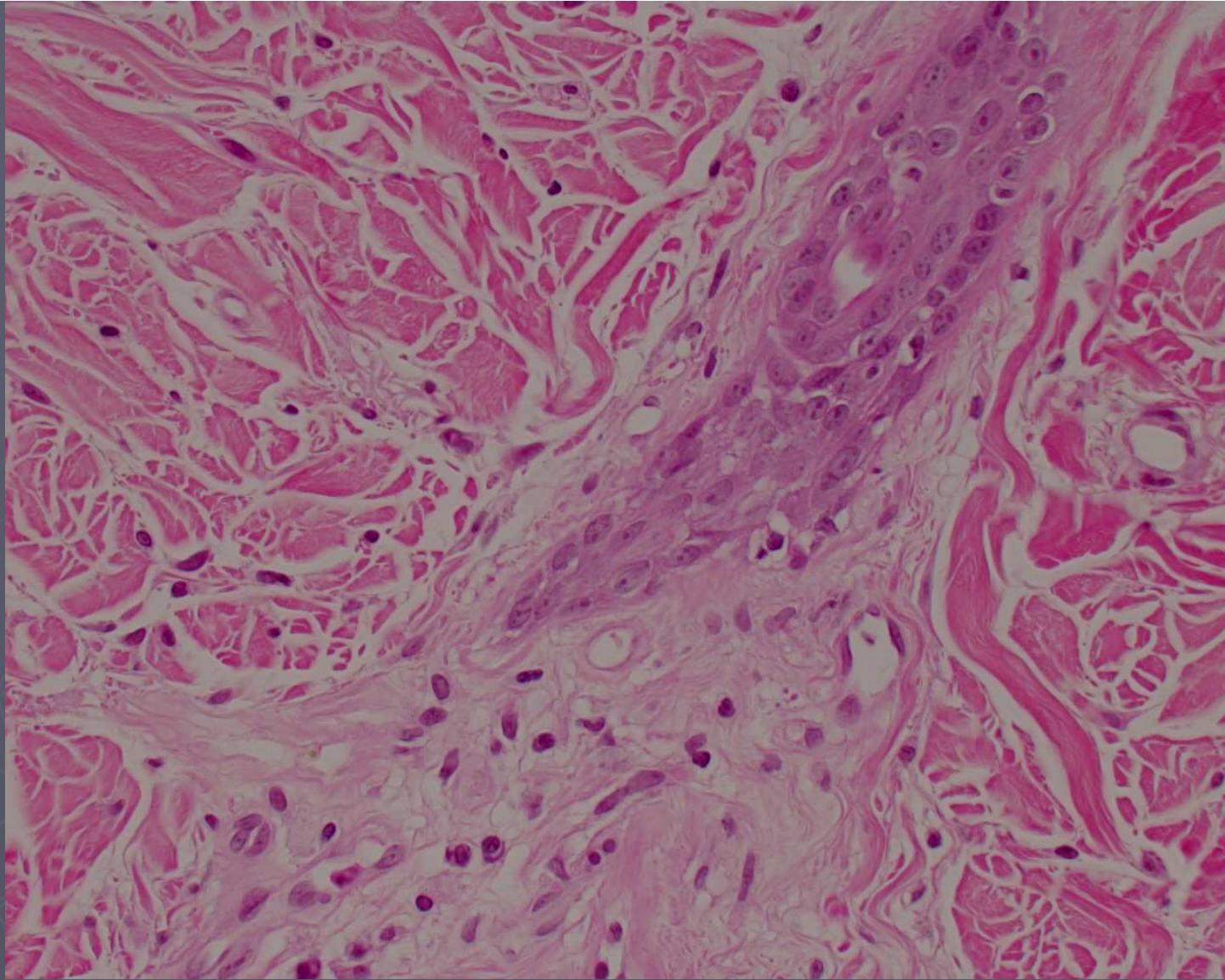
Traction alopecia



Juvenile-onset Dermatomyositis



Dermatomyositis



Canine dermatomyositis
Faded follicle with prominent glassy membrane