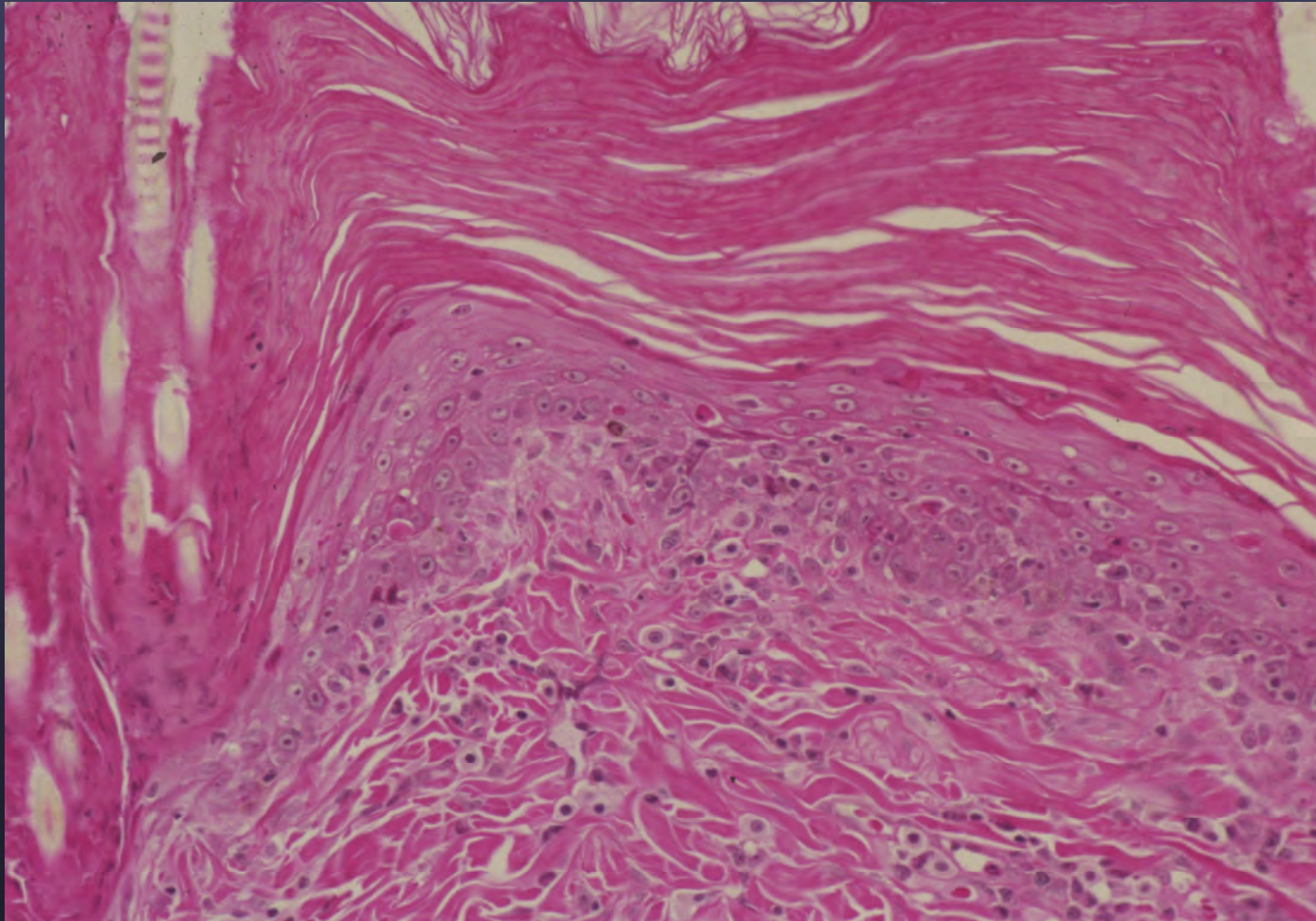
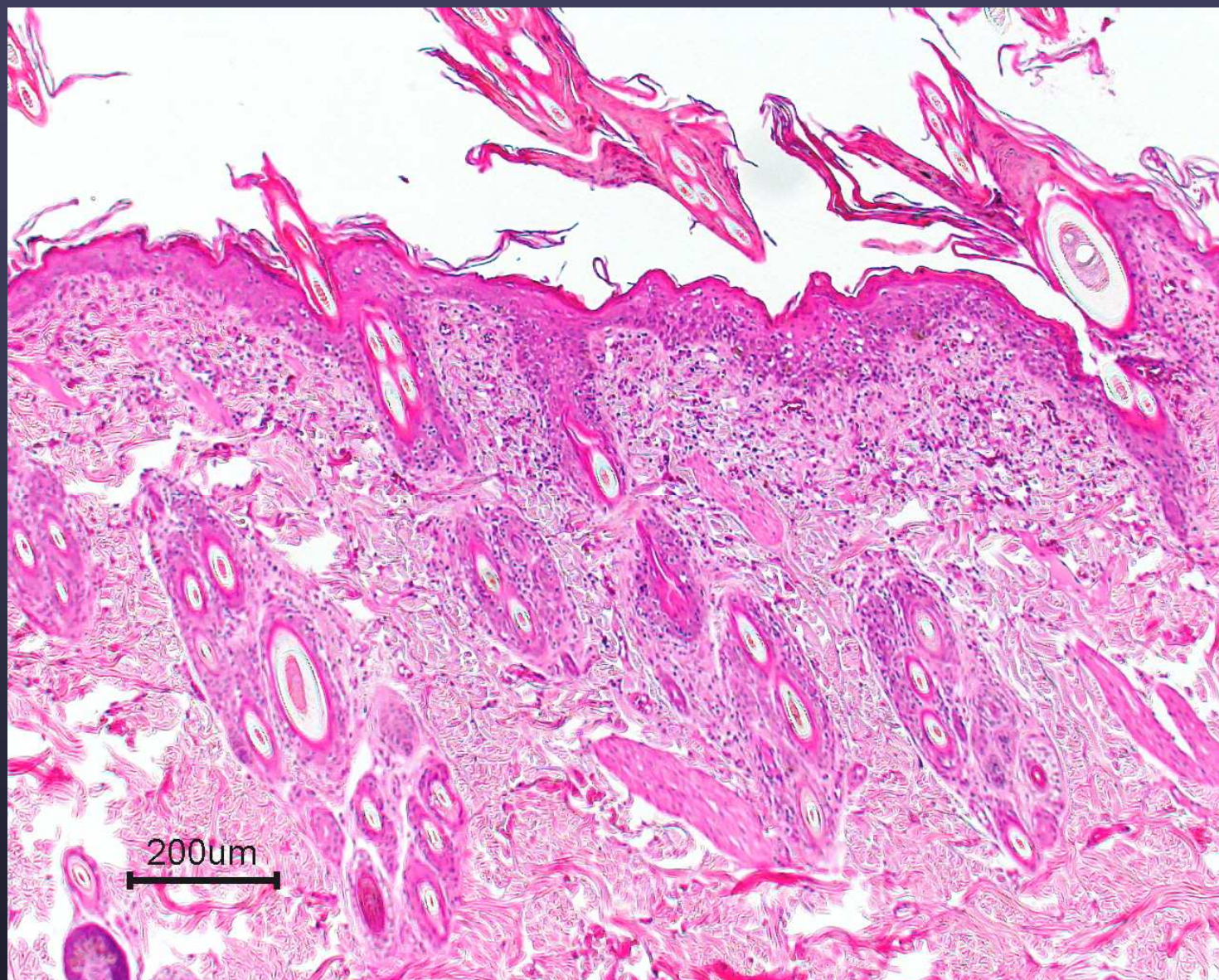


Thymoma-Associated Dermatositis (TAD)

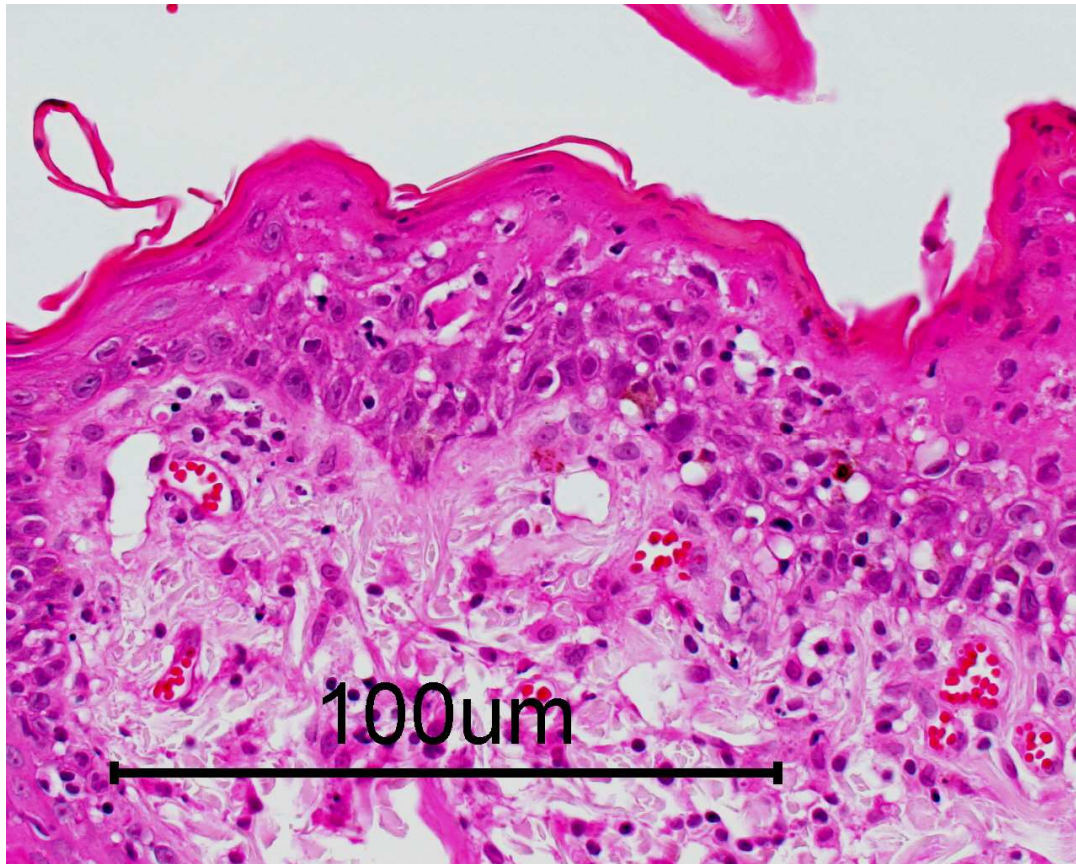




9 yr, FS, Siamese

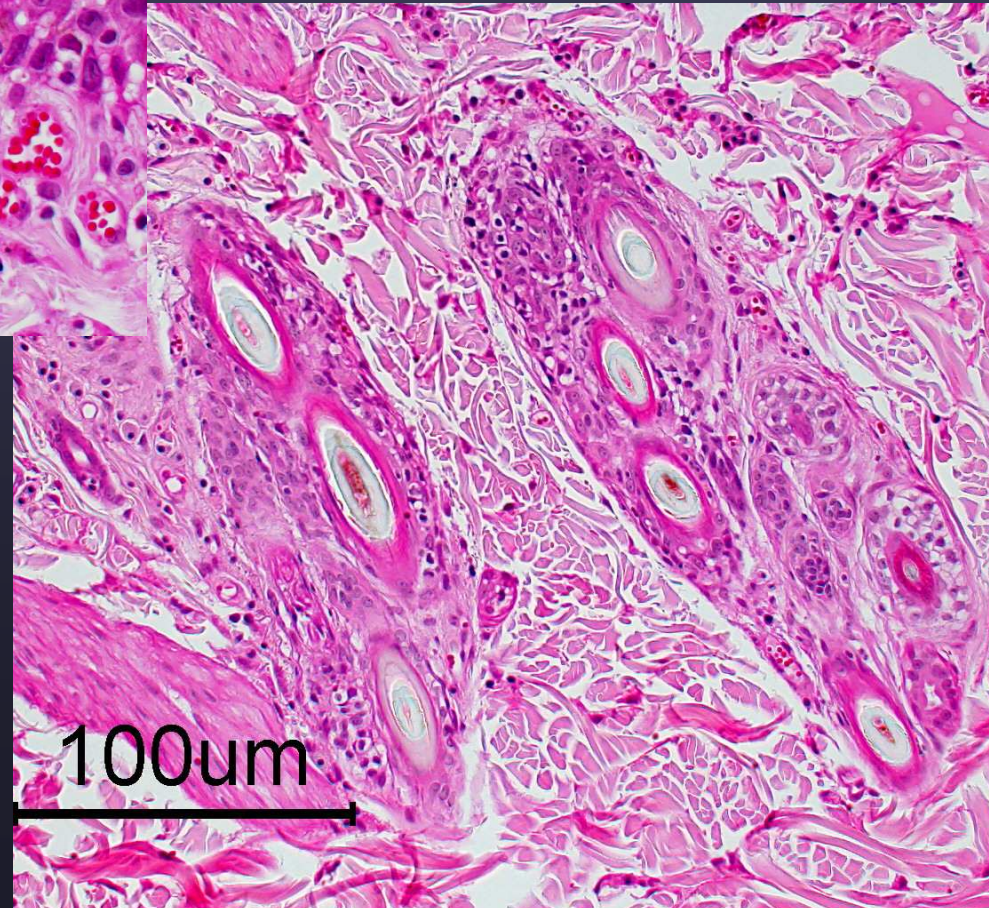
May 2002

TAD- not uncommon to see diffuse sebaceous gland loss

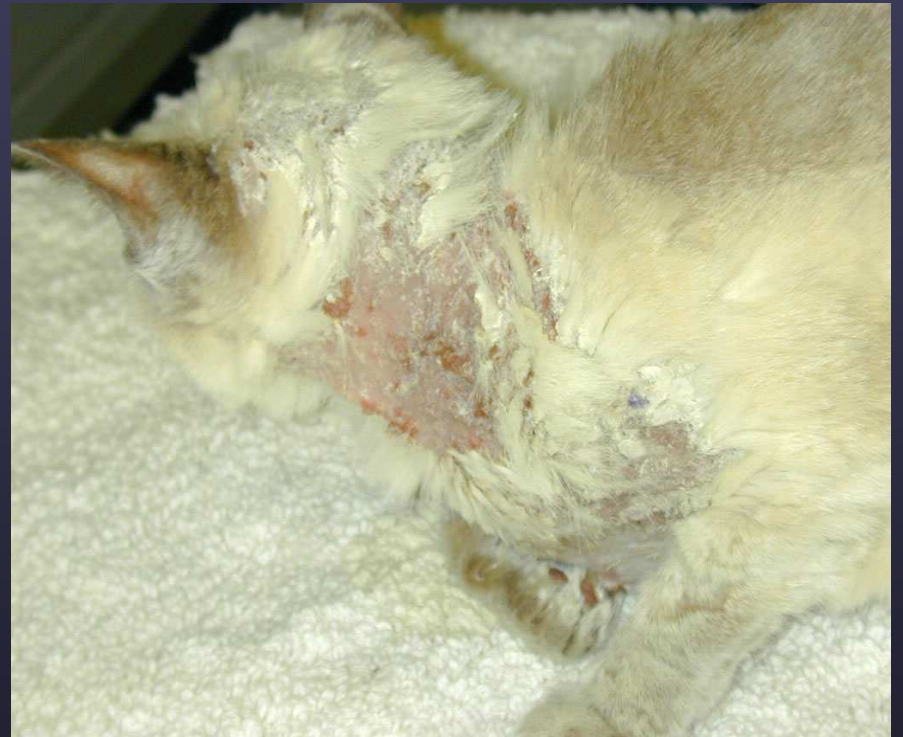
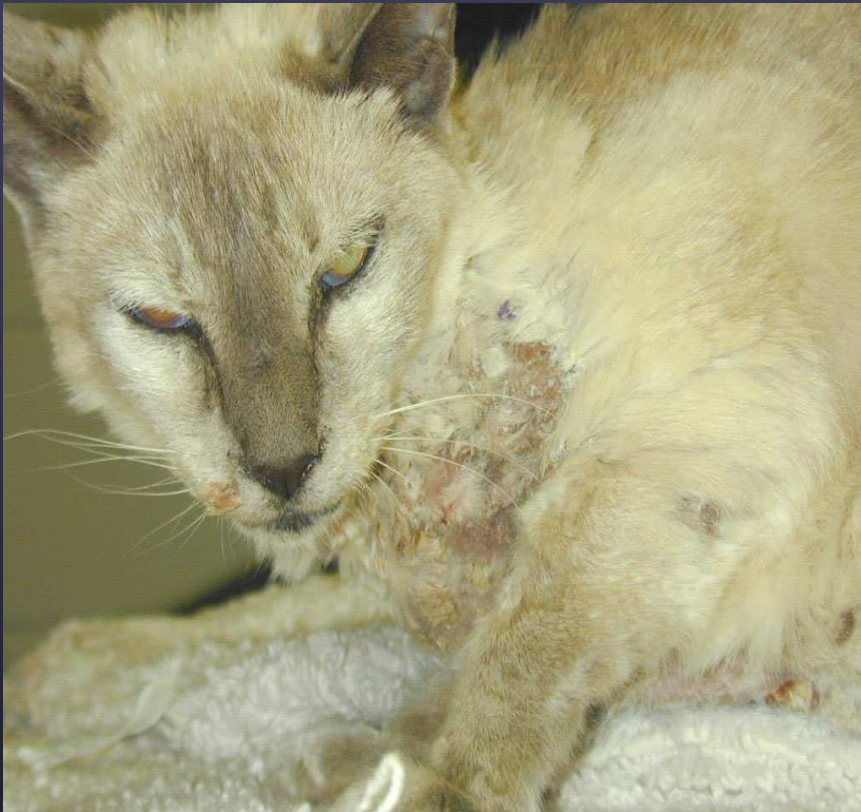
TAD

May 2002

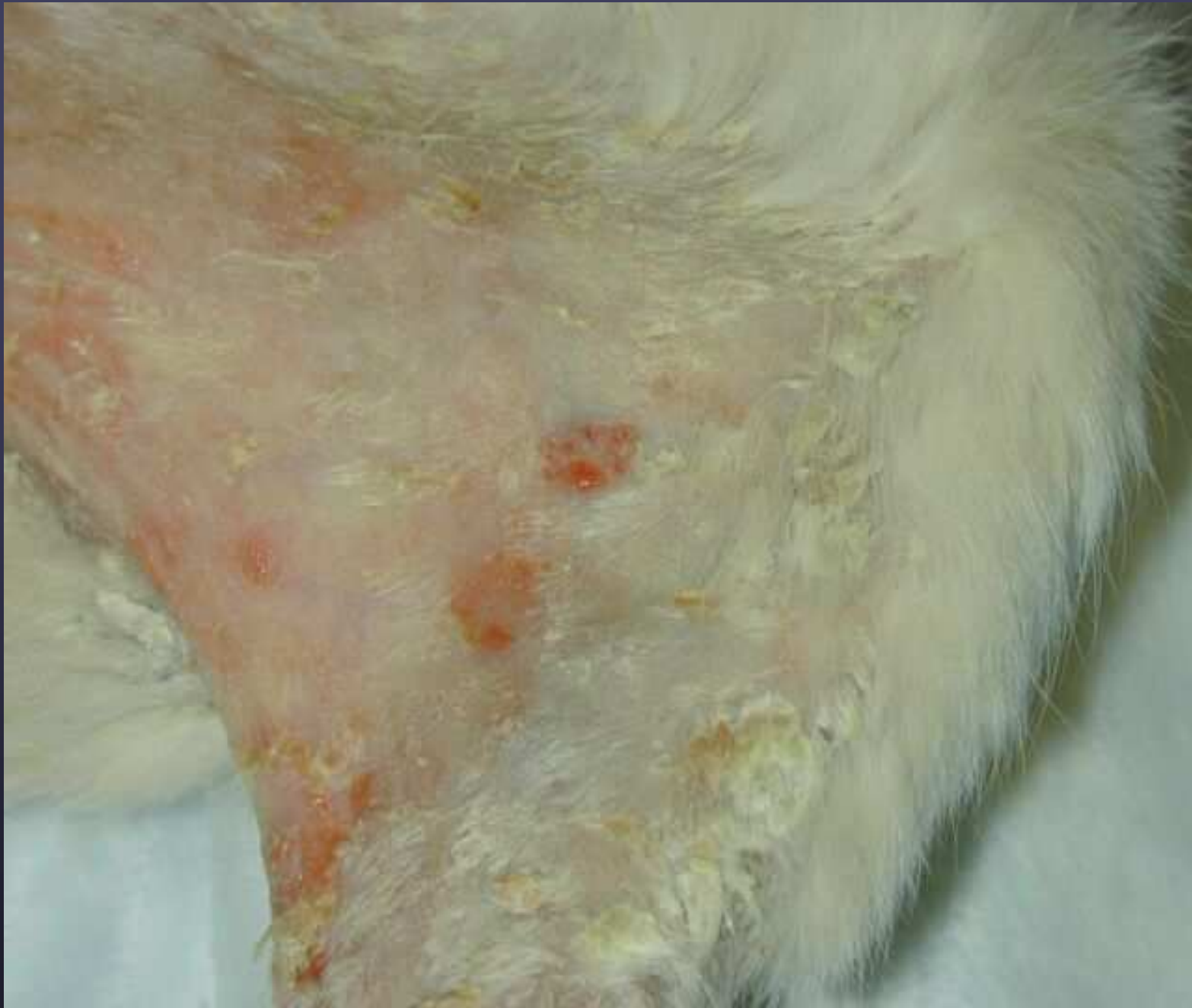

Thymoma-associated Dermatitis

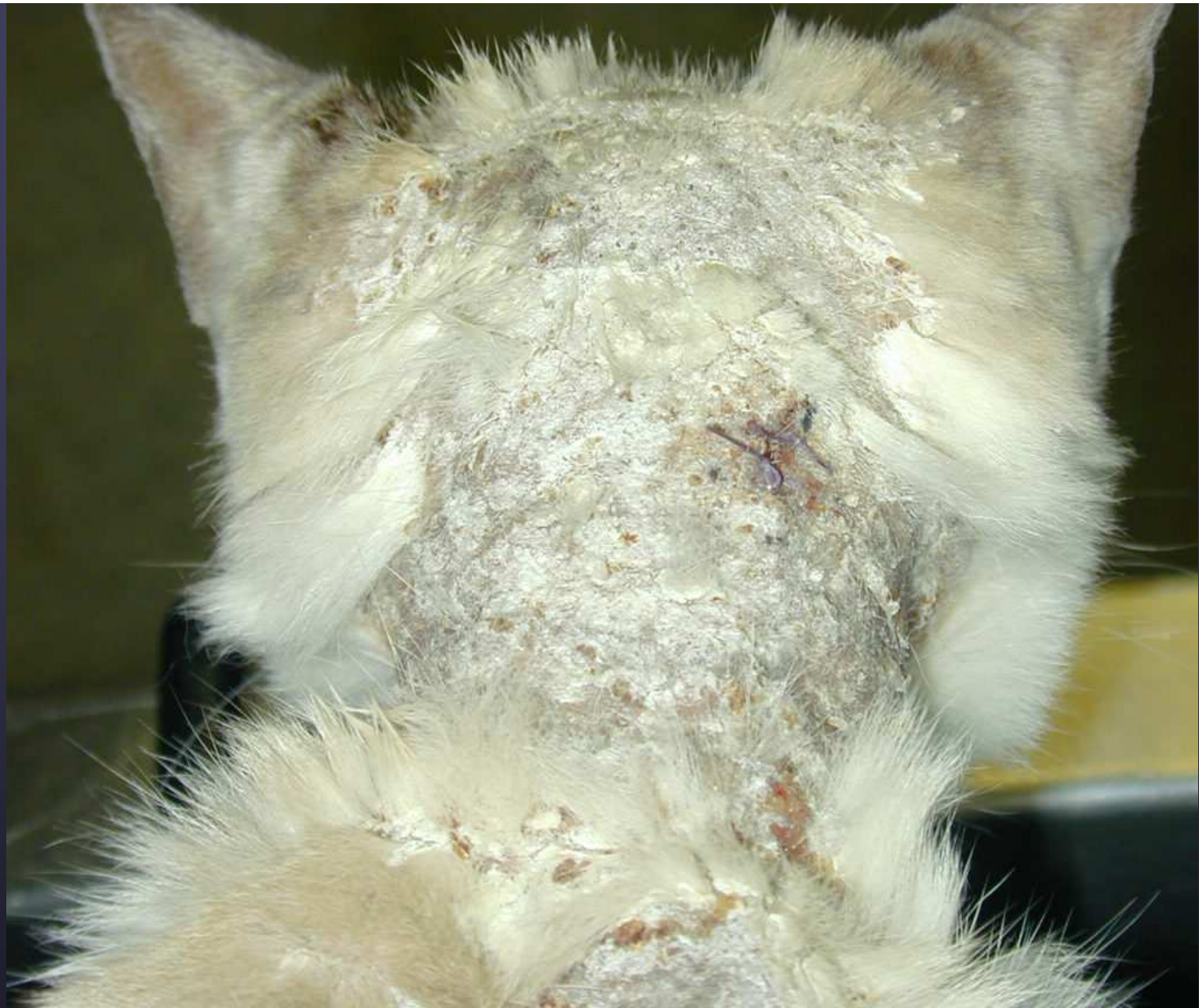

9 yr, FS, Siamese

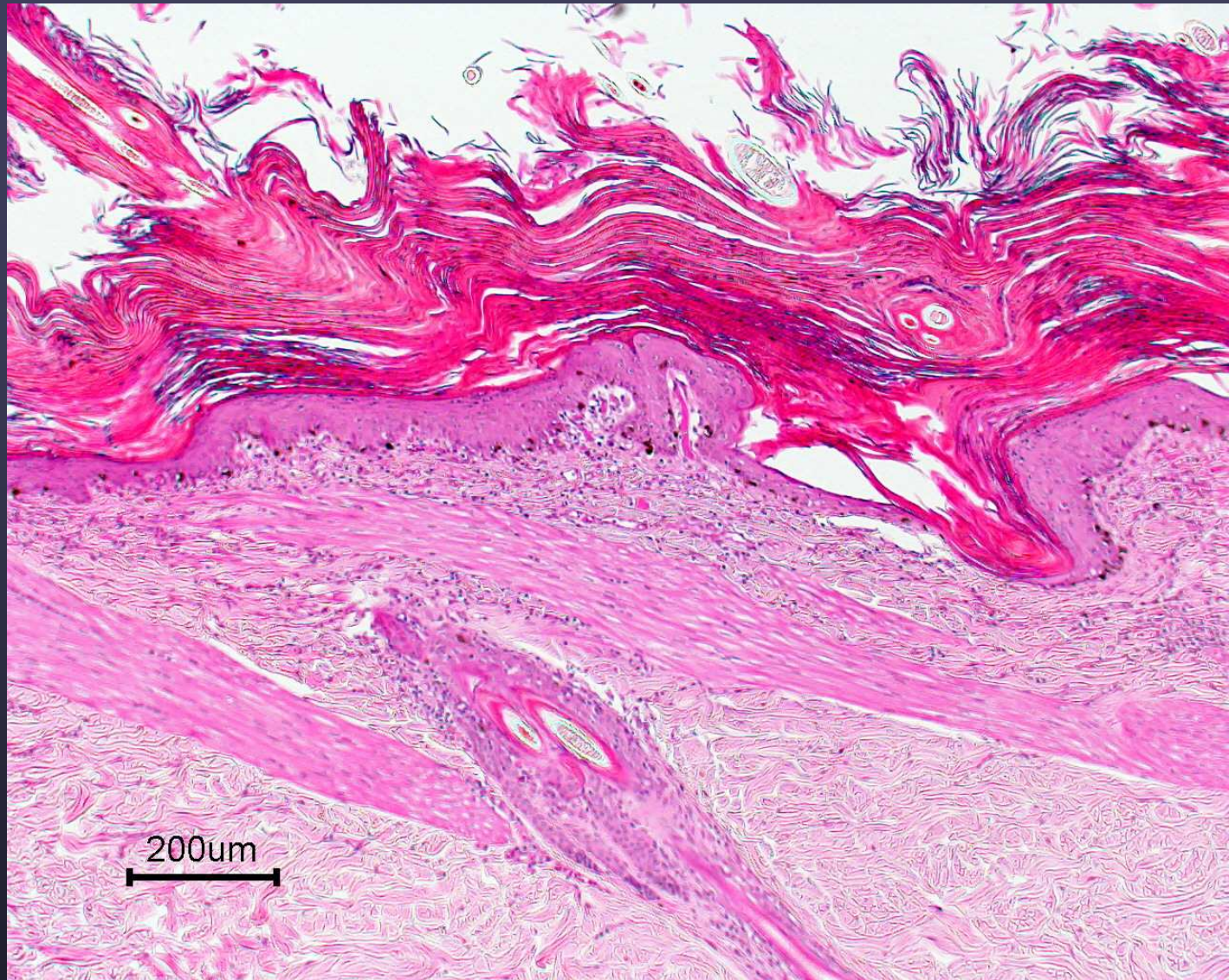
4 wks post-thymectomy



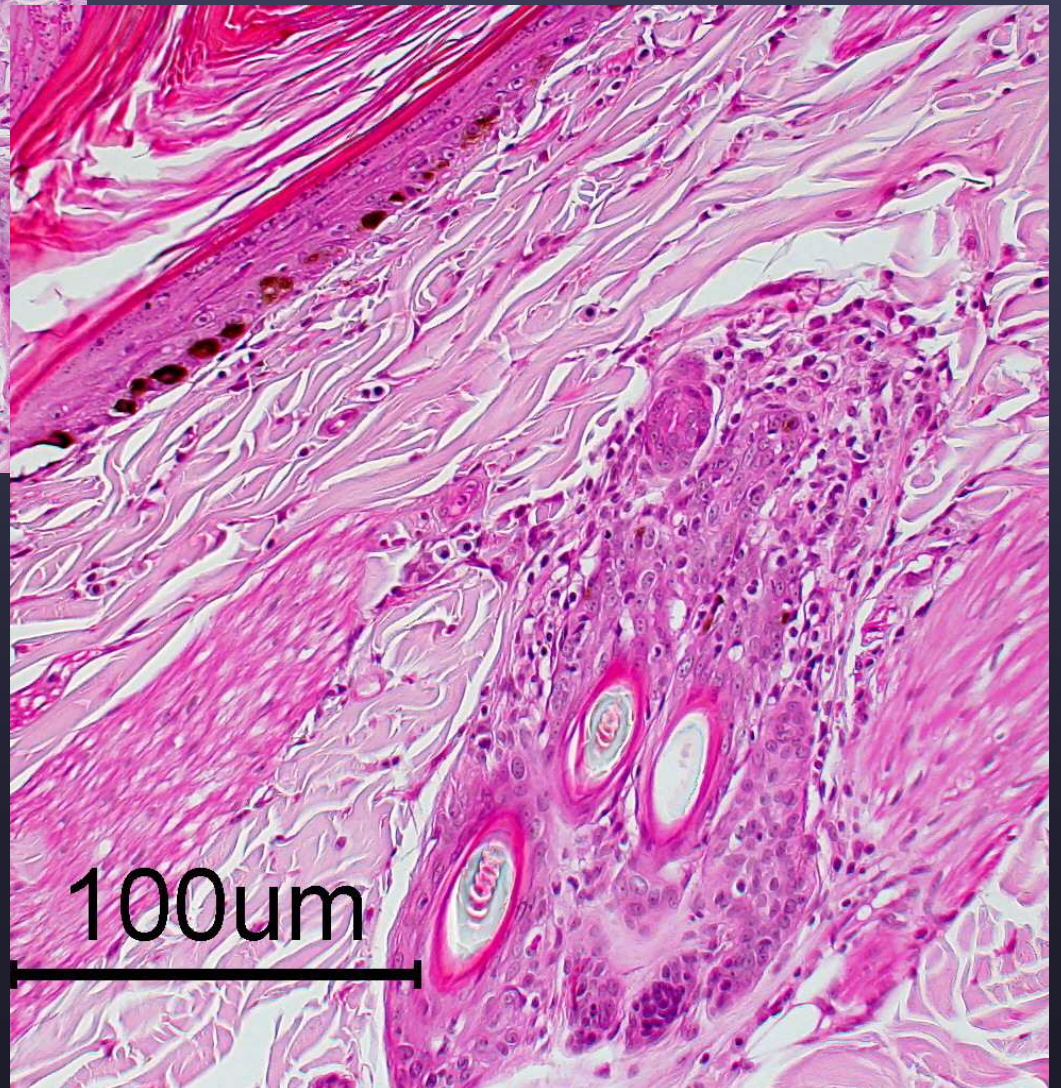
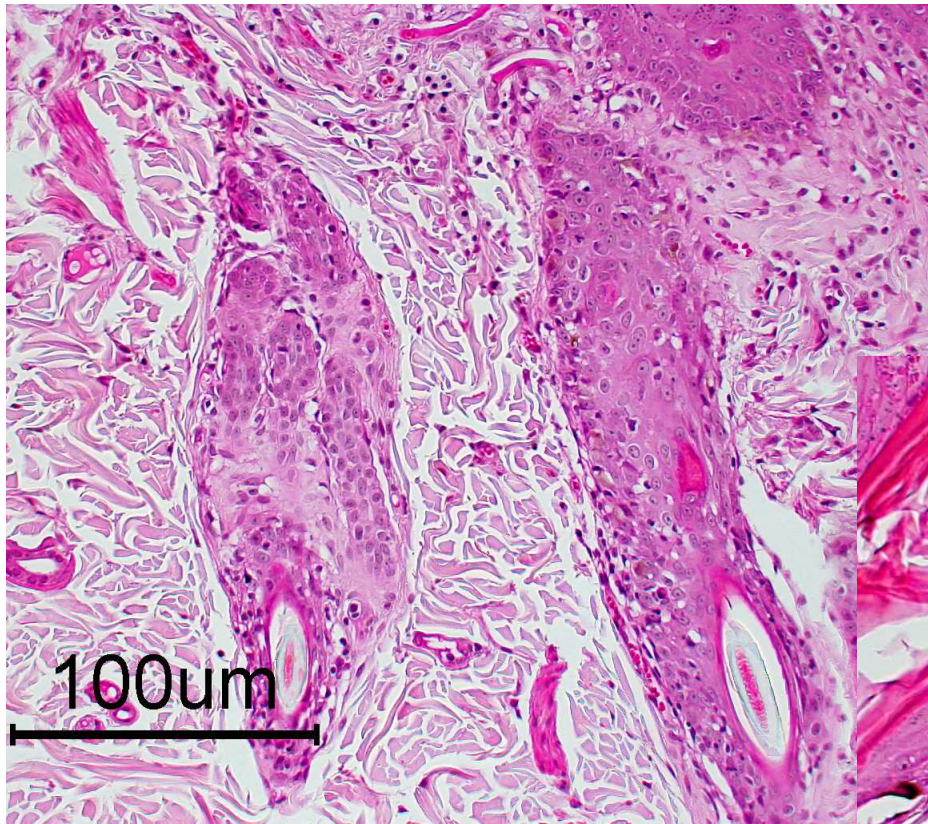
TAD- hair mats with thick adherent keratin scale and easily exfoliates → erosions



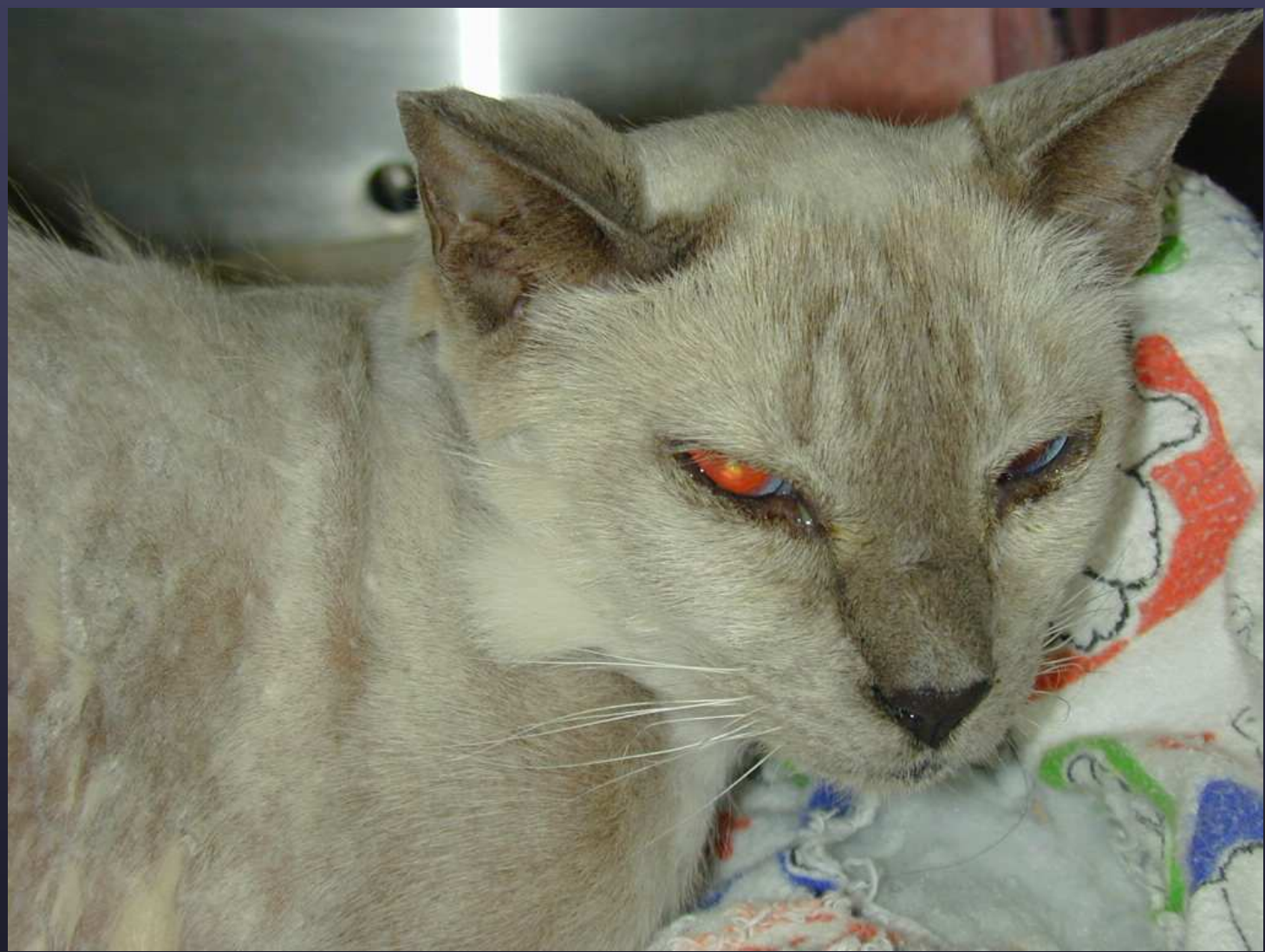TAD- note the severe scaling; hair mats with thick adherent keratin scale and easily exfoliates

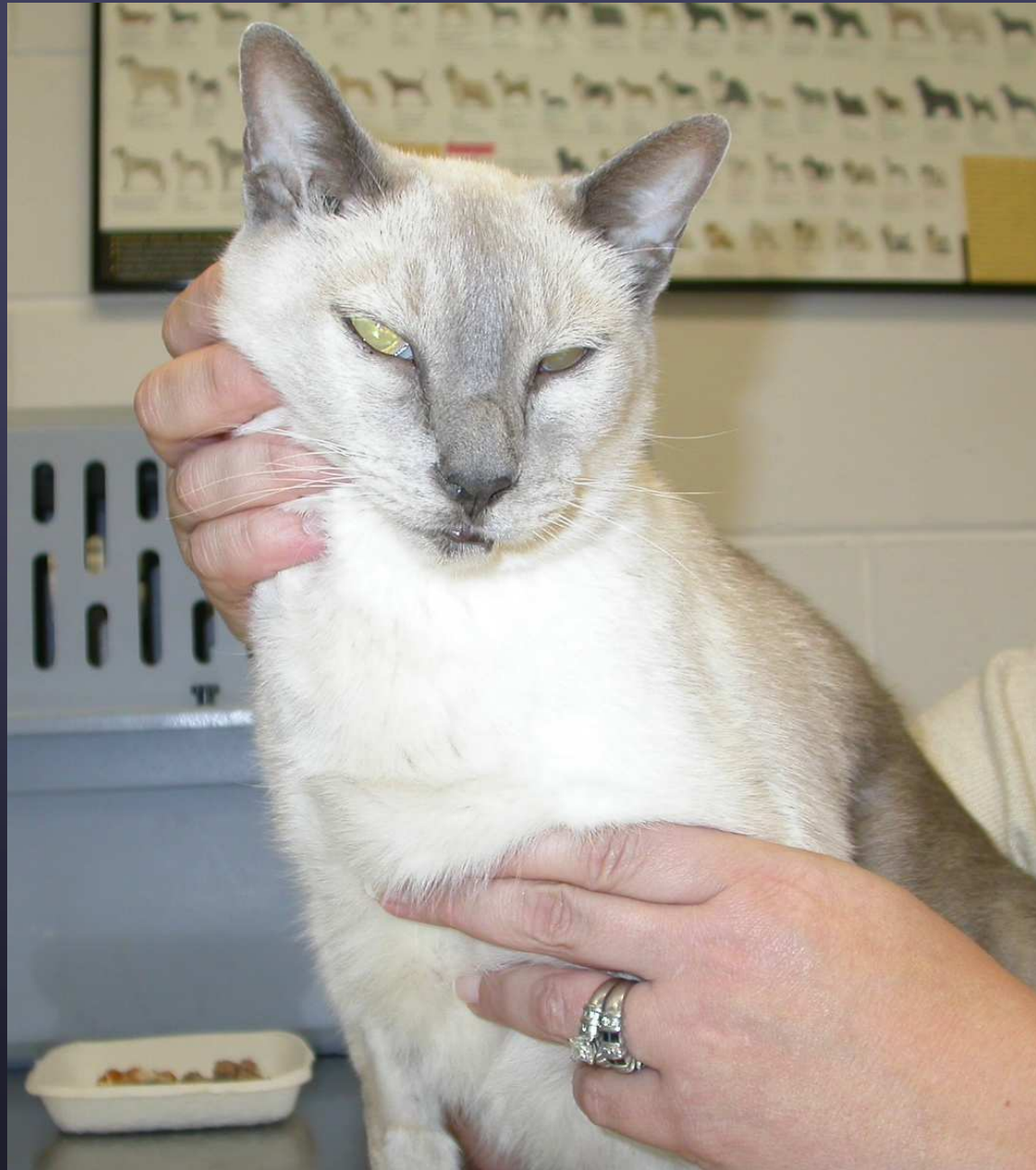

TAD 4 weeks post op

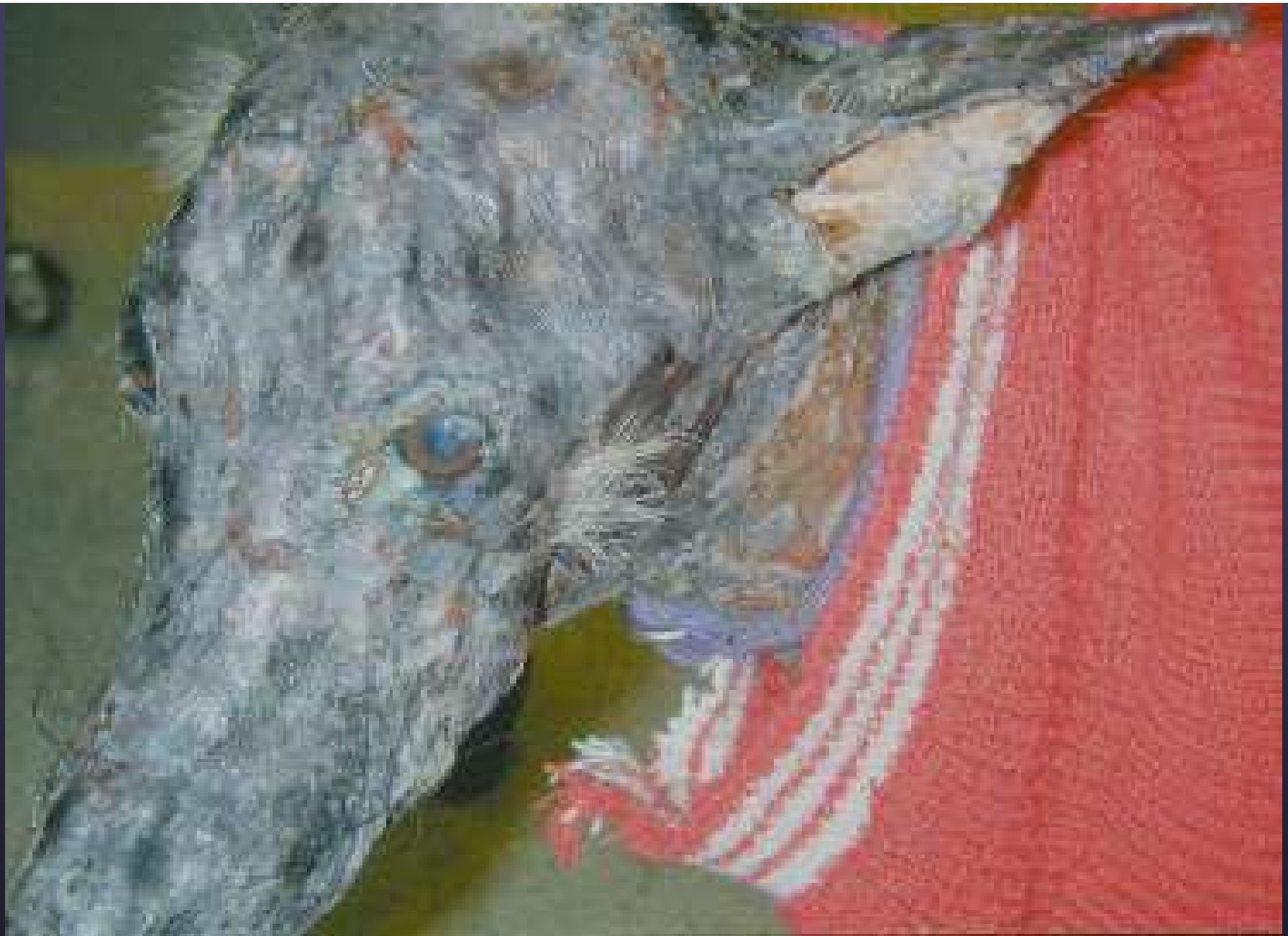

**4 weeks post op
Sebaceous gland loss**





1 yr post-op



Terminal dermatomyositis in a Sheltie