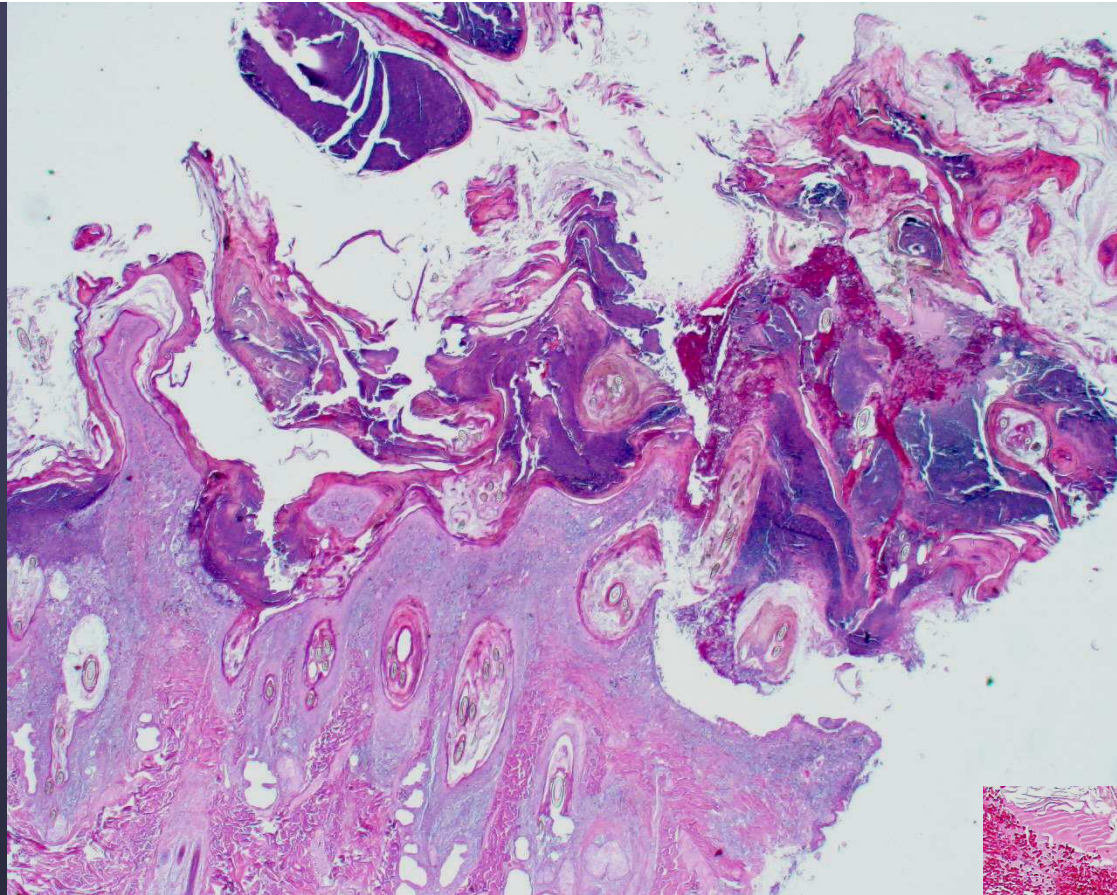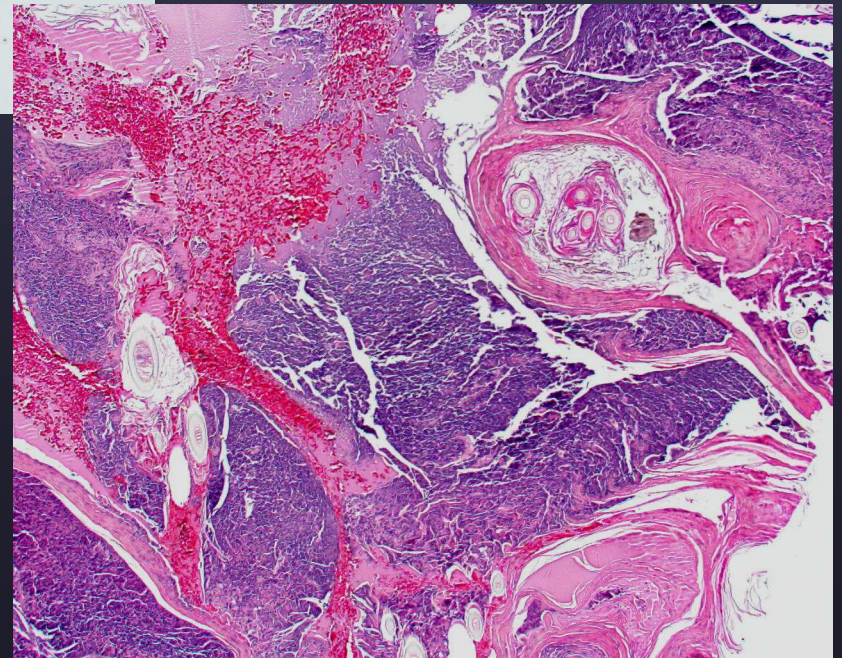
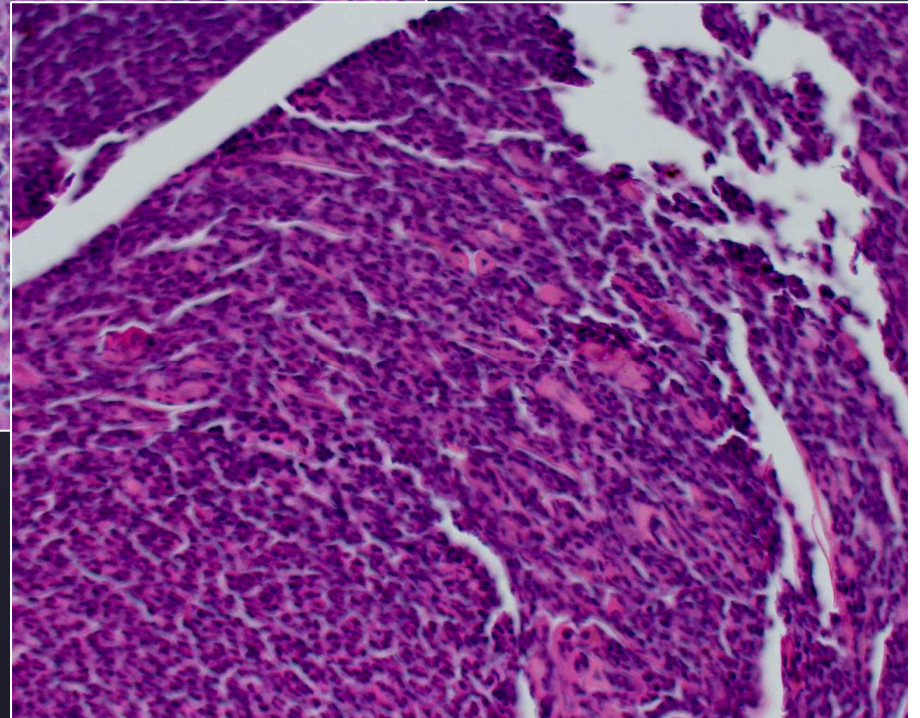
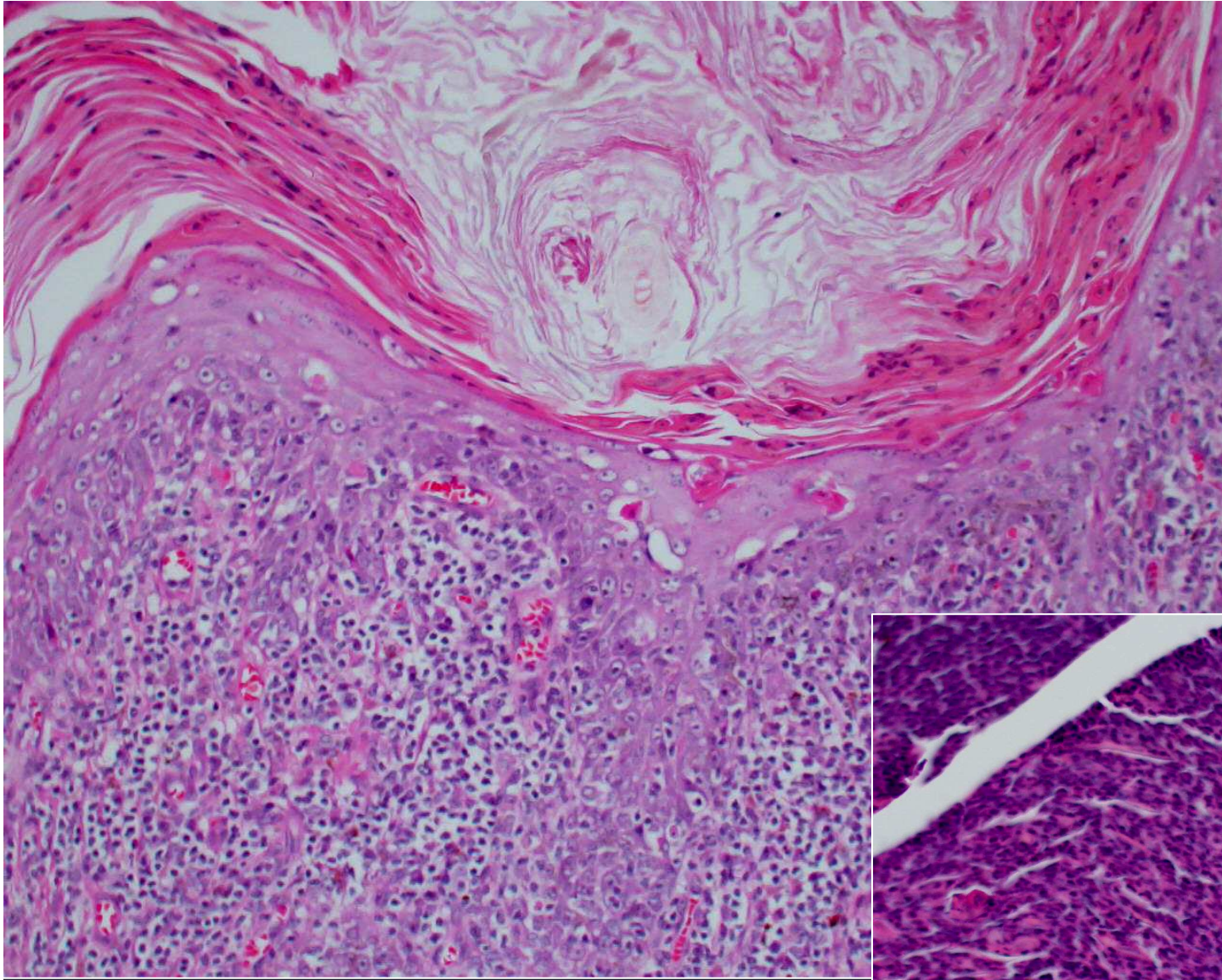

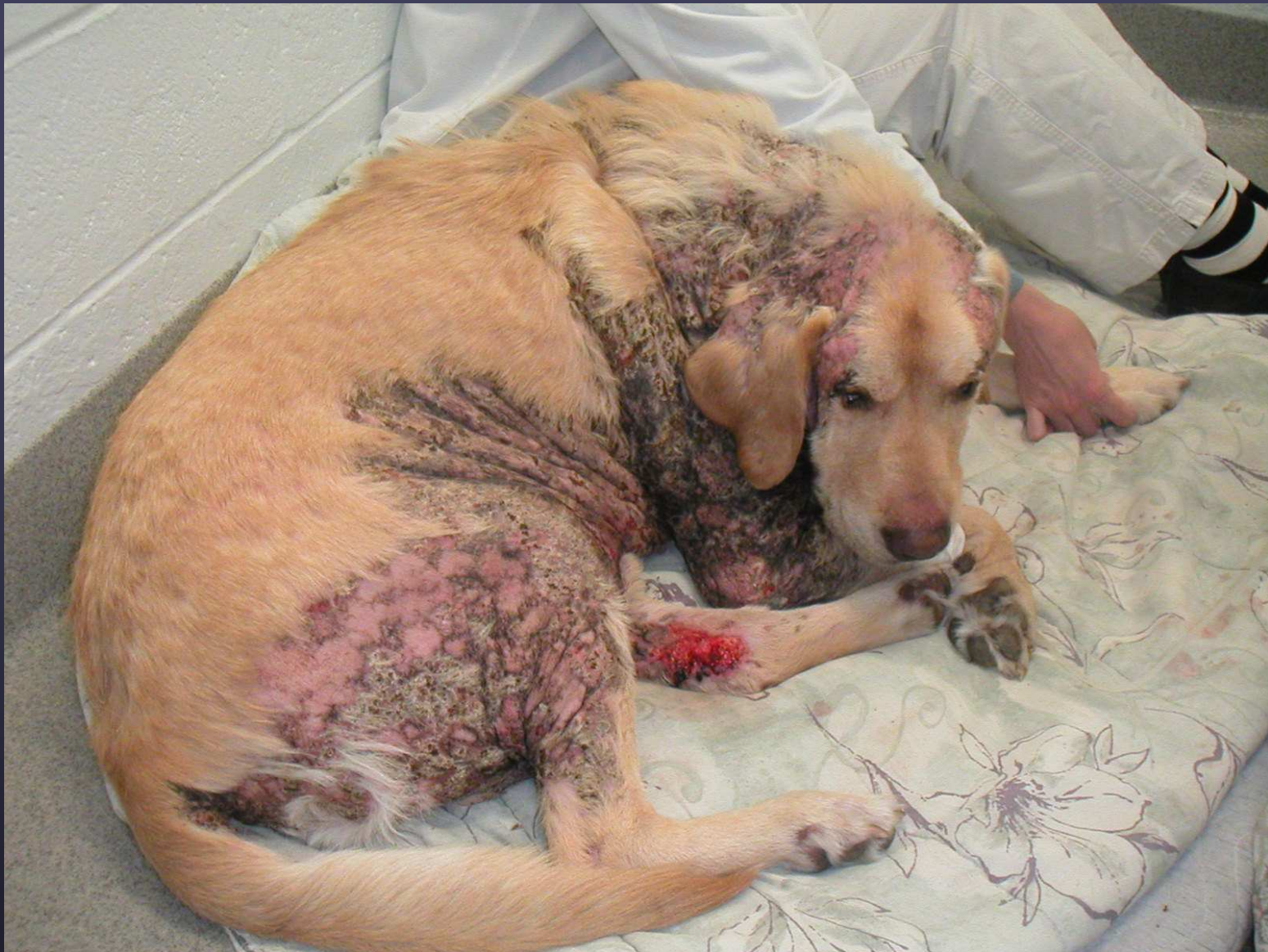
Acantholytic
EM?

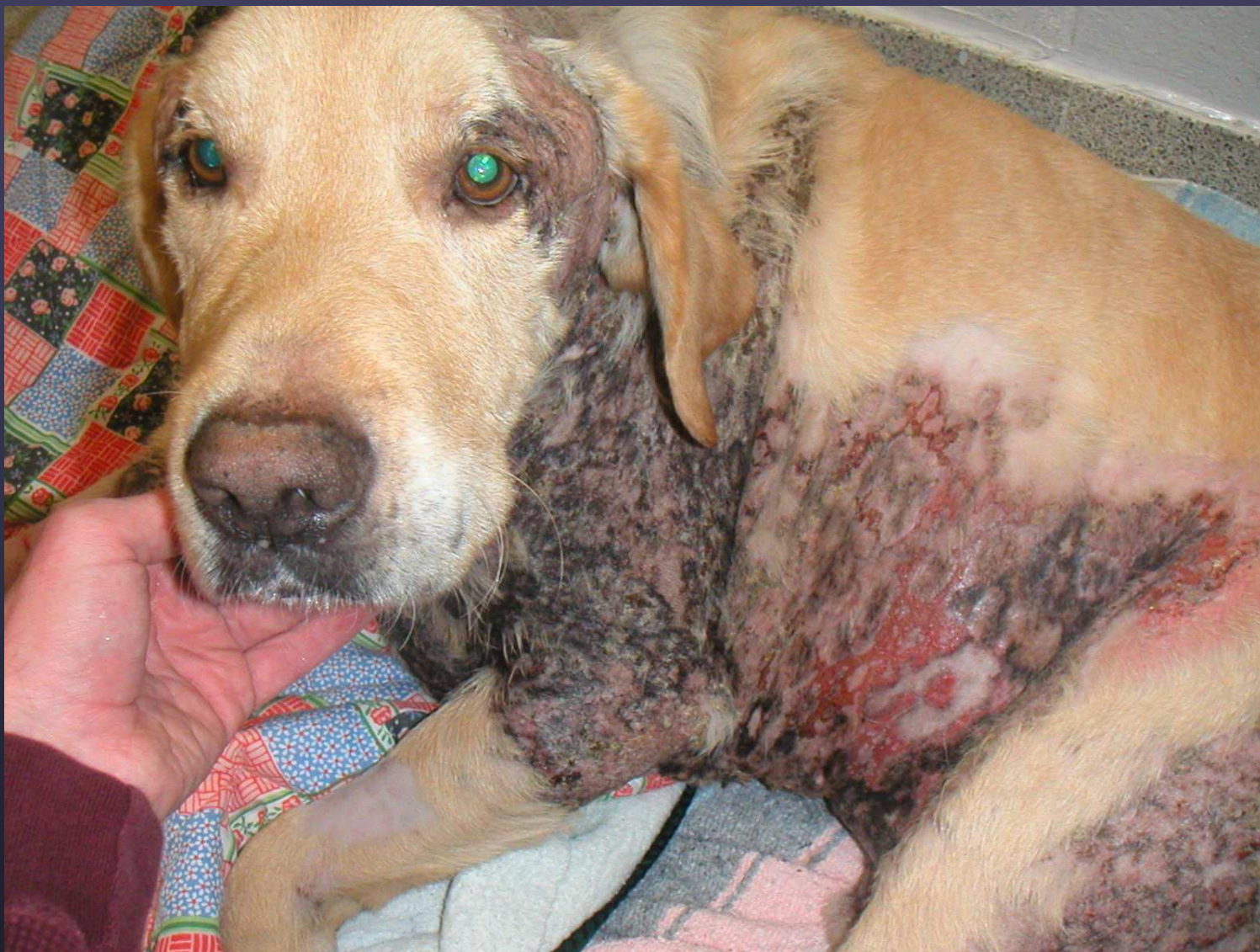





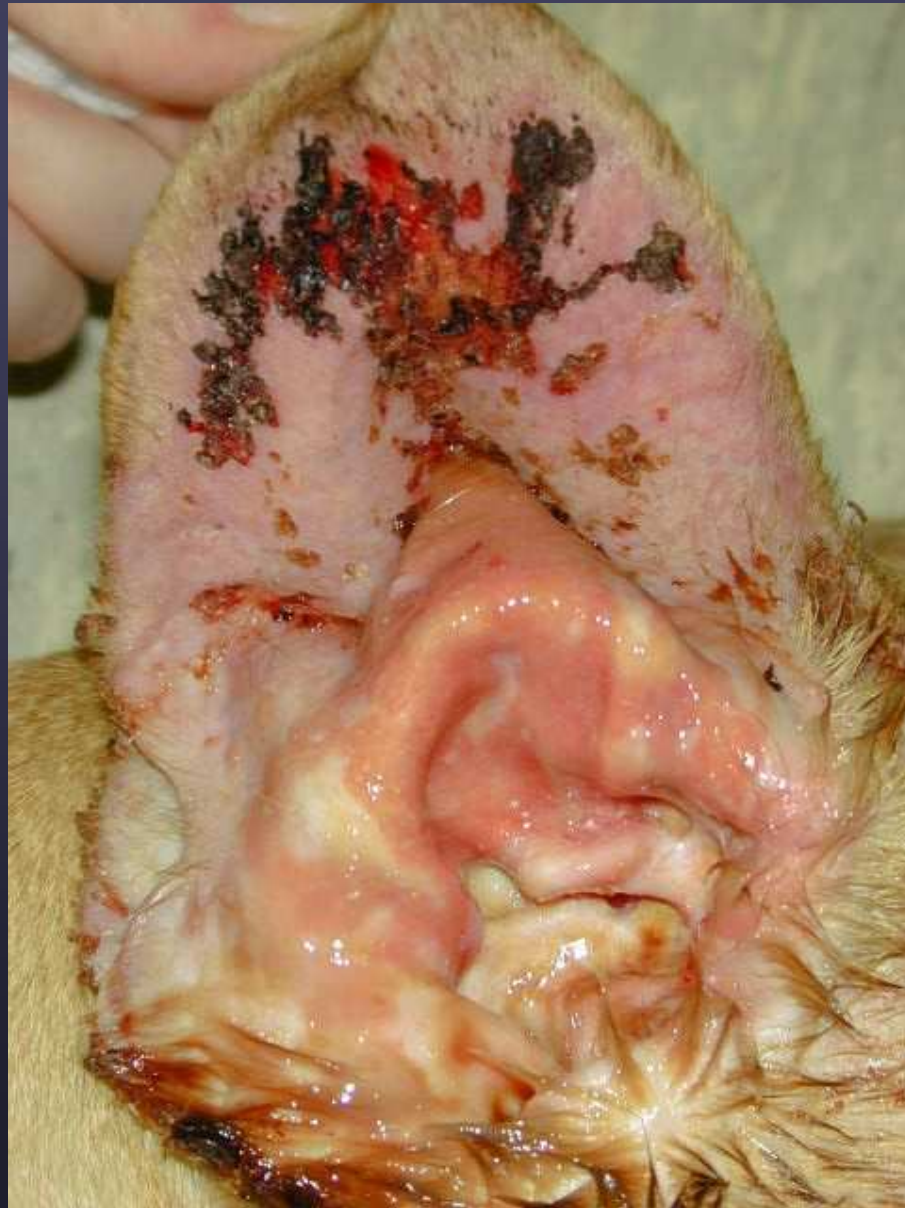Oct 2003

Severe hyperkeratosis and crusting and alopecia in dog with EMM

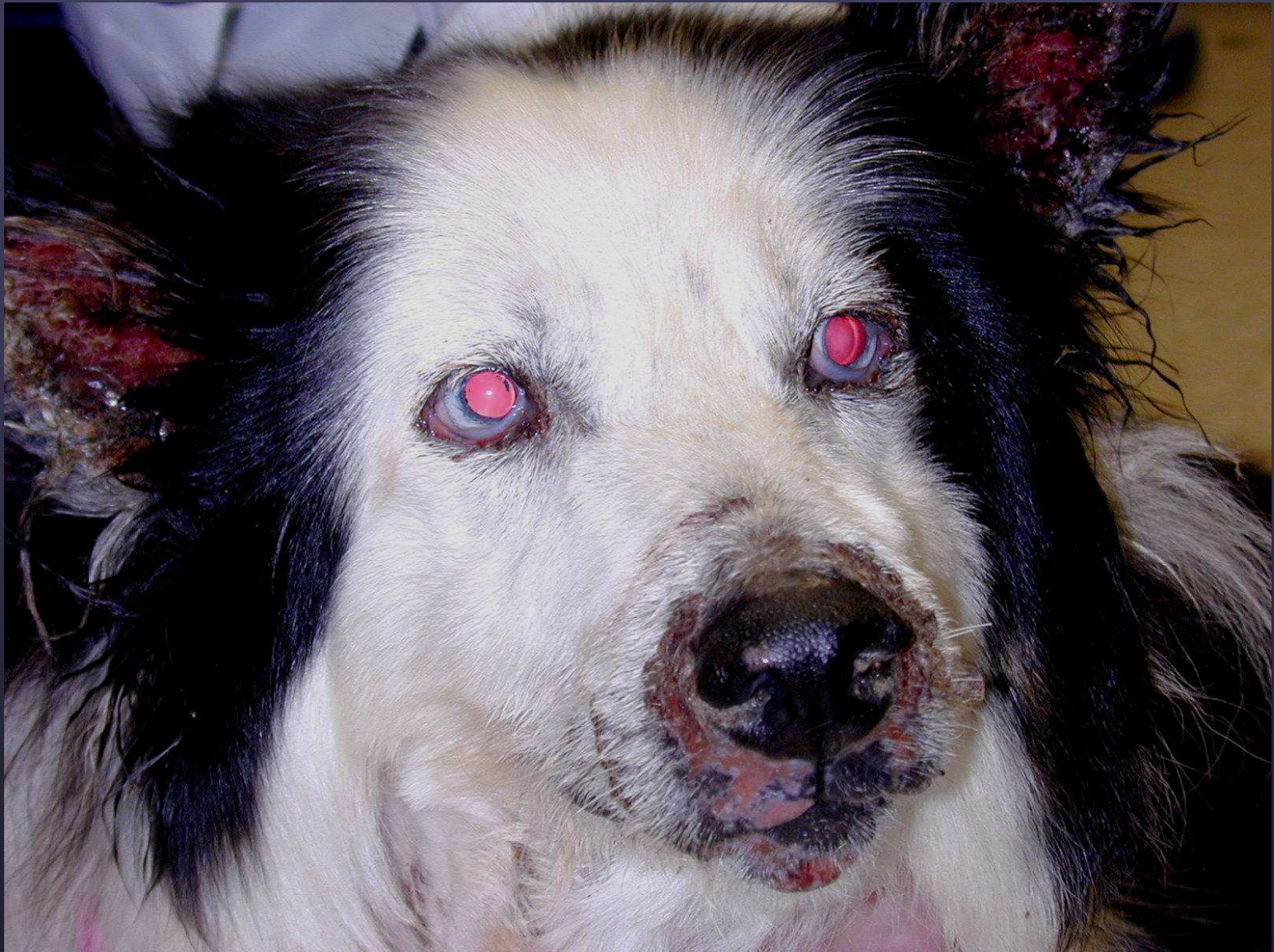

Oct 2003

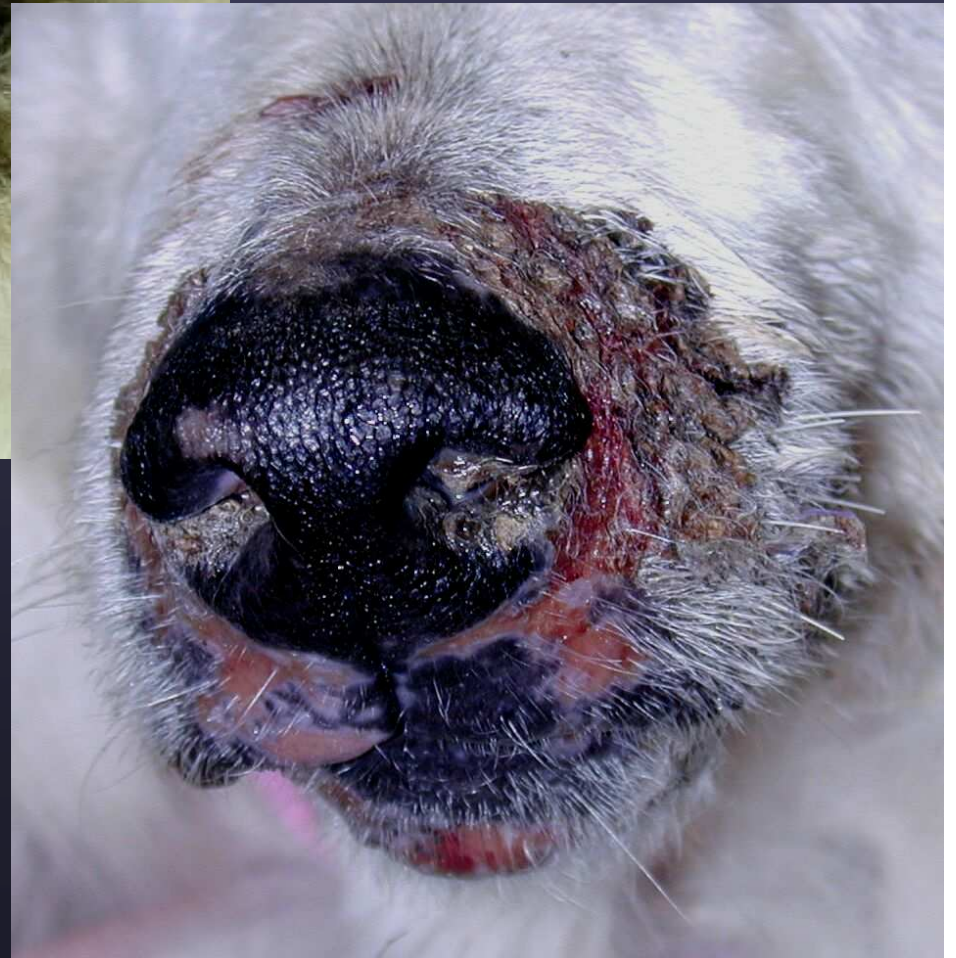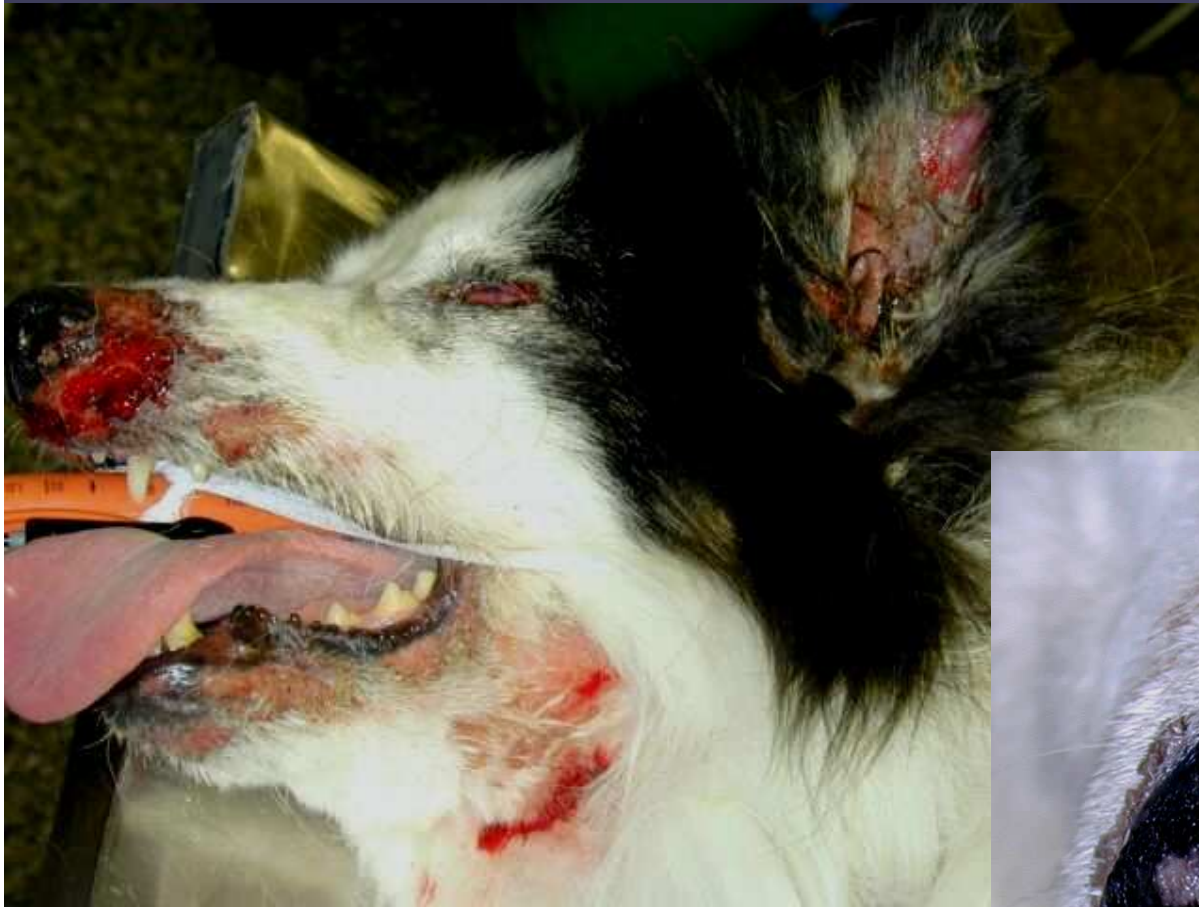Severe hyperkeratosis and crusting and alopecia in dog with EMM



Concurrent pseudomonas otitis



EMM/SJS associated with repositol injectable heartworm preventative



Drug-induced EMM/SJS