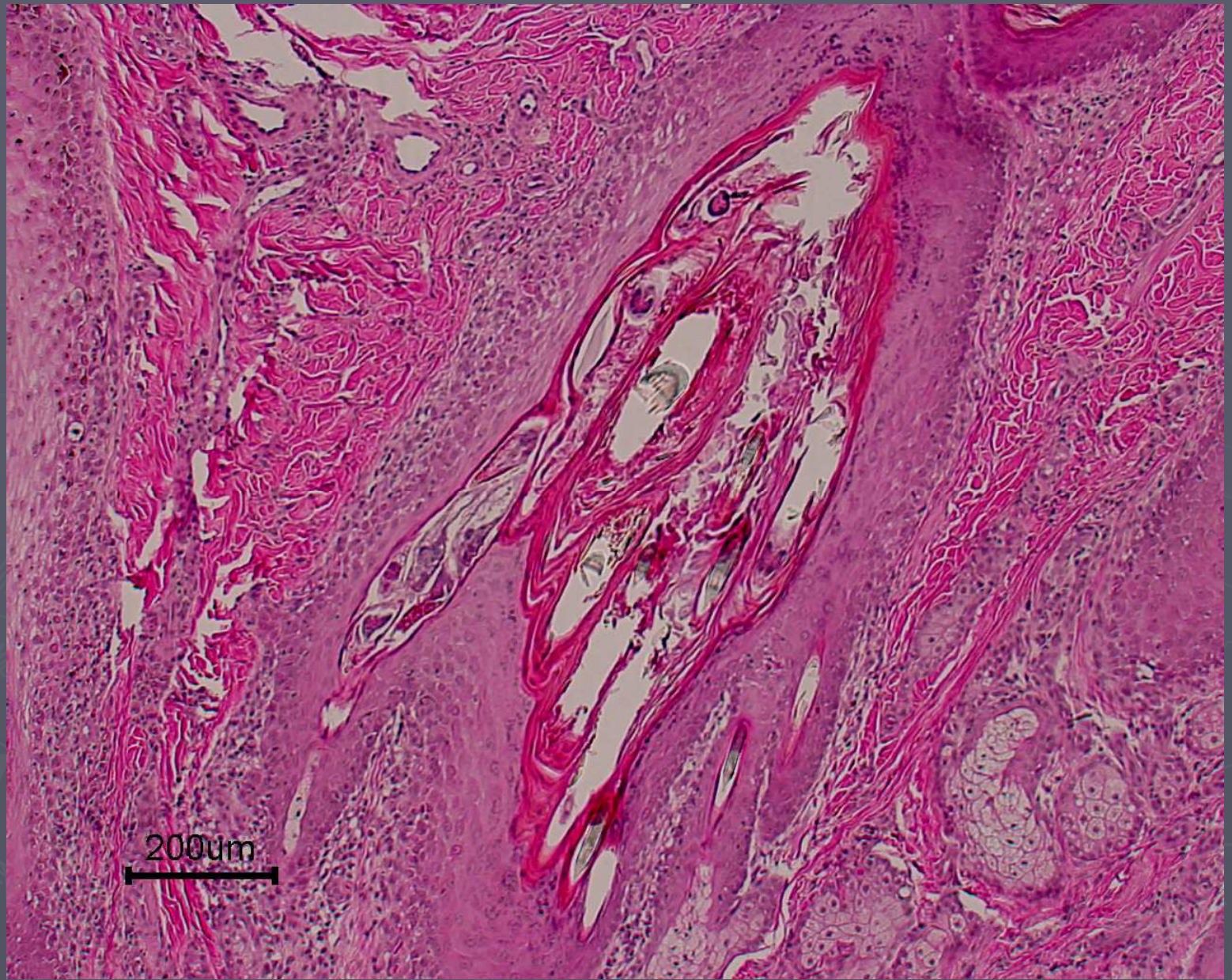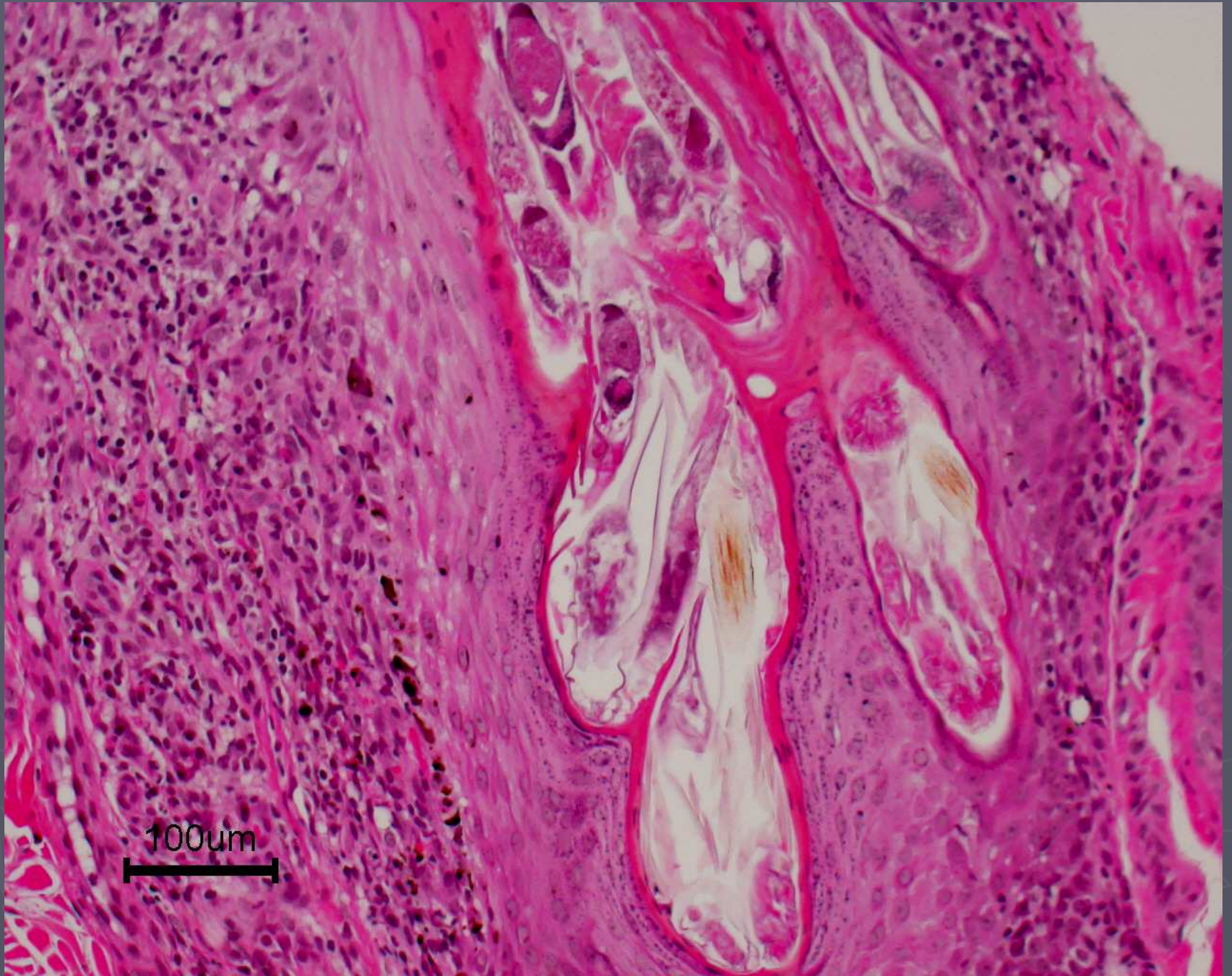
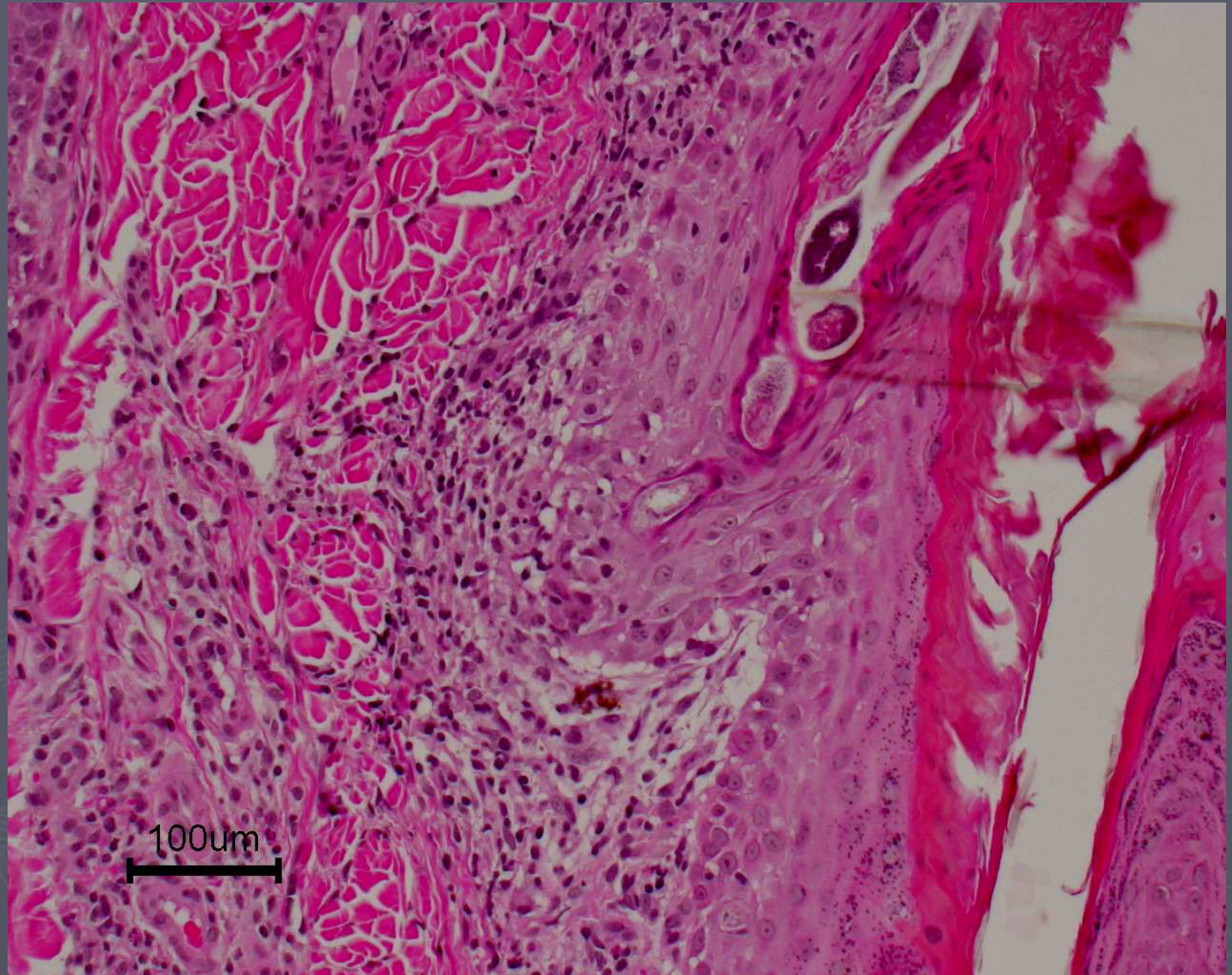


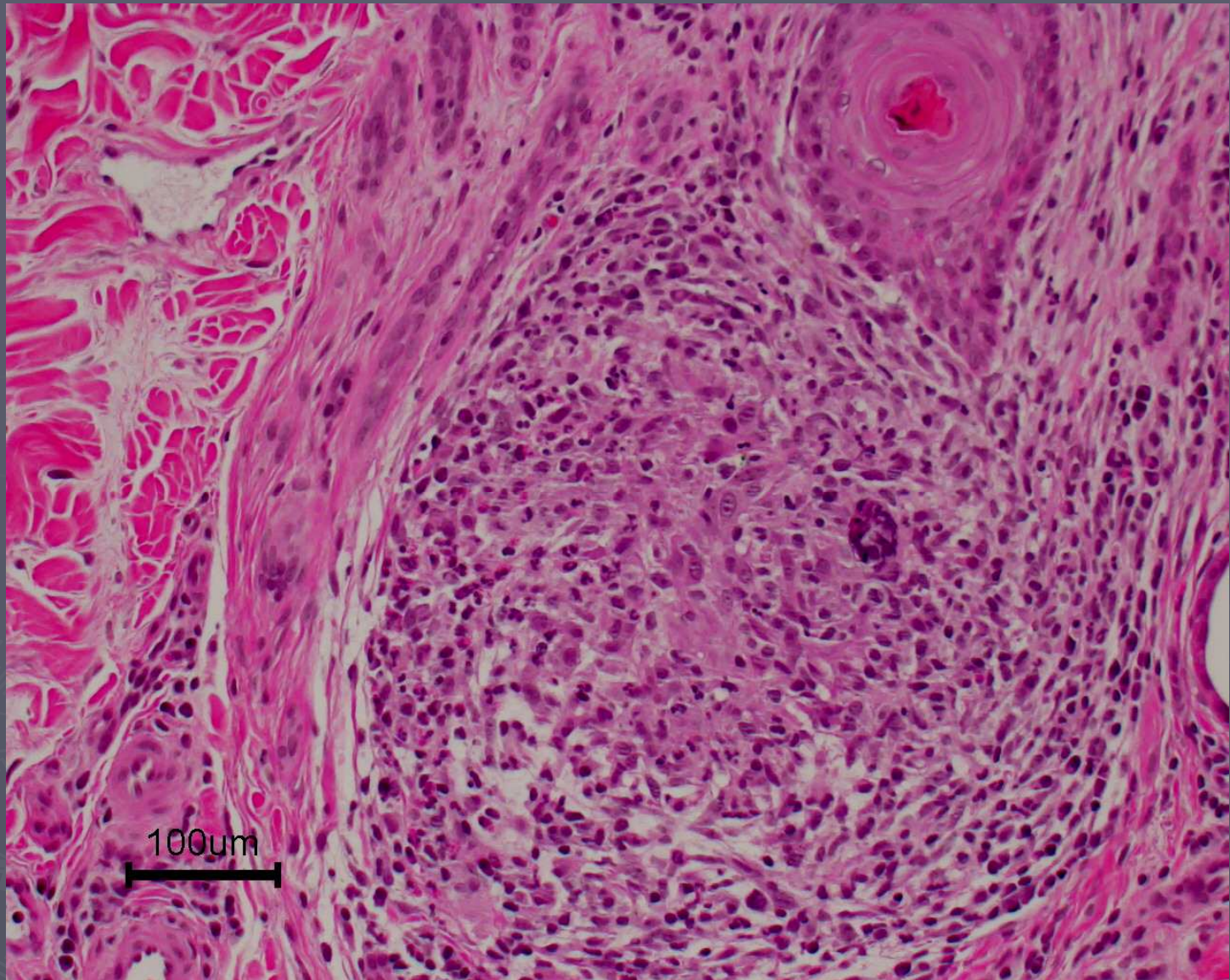
Mild mural folliculitis- Demodicosis



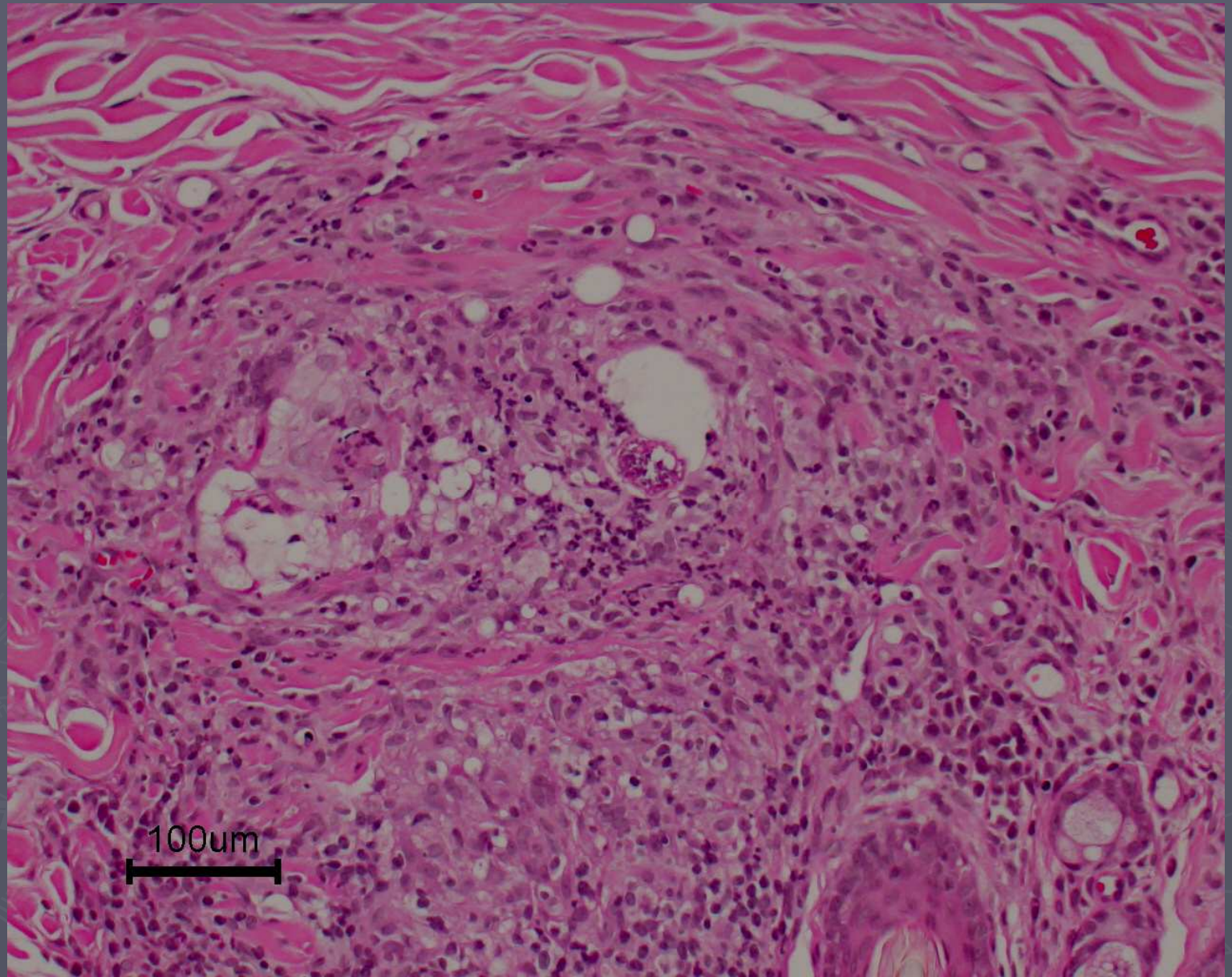
Mild mural folliculitis



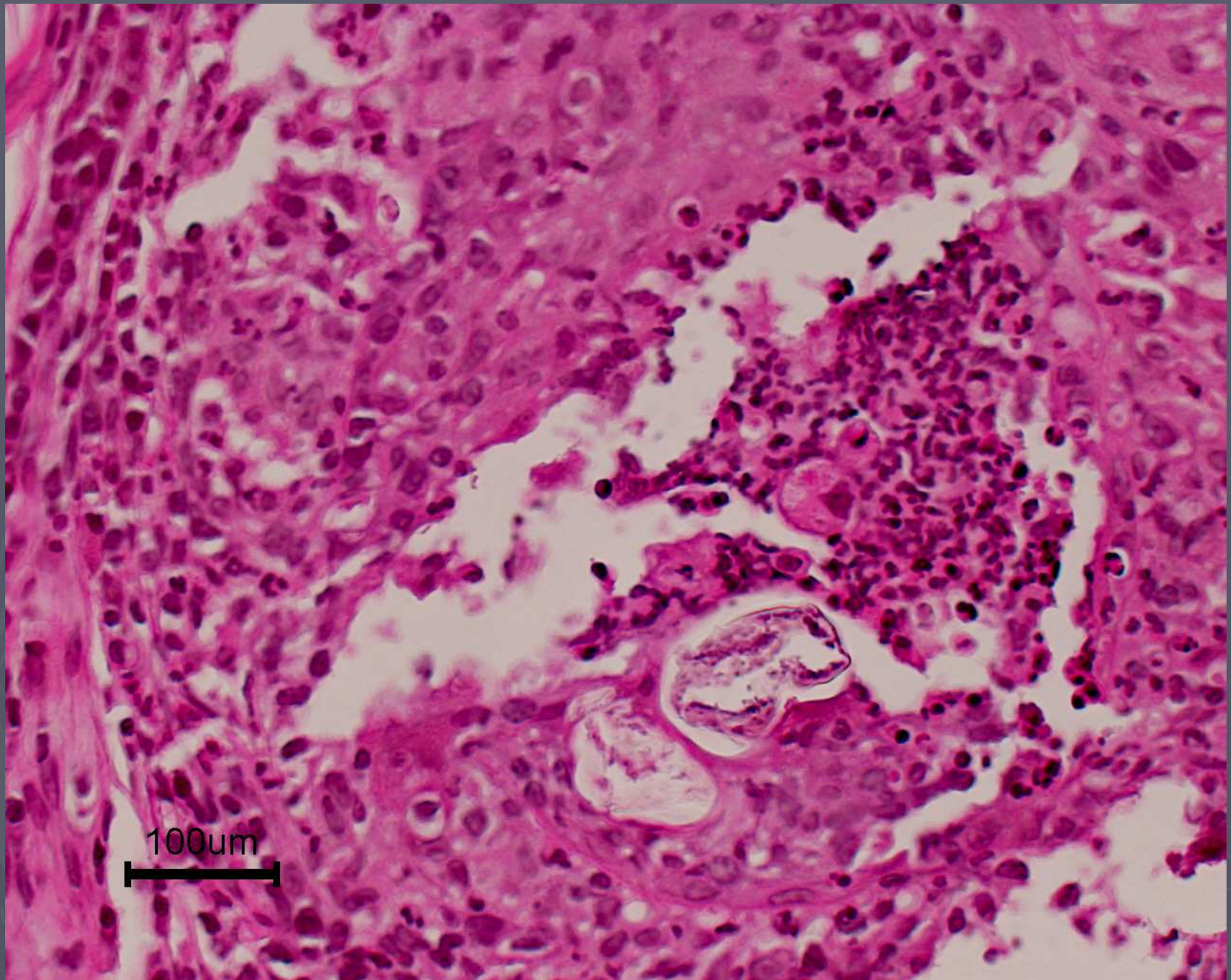
Note the basilar vacuolar change, loss of DEJ distinction and melanin drop off



Demodex granuloma

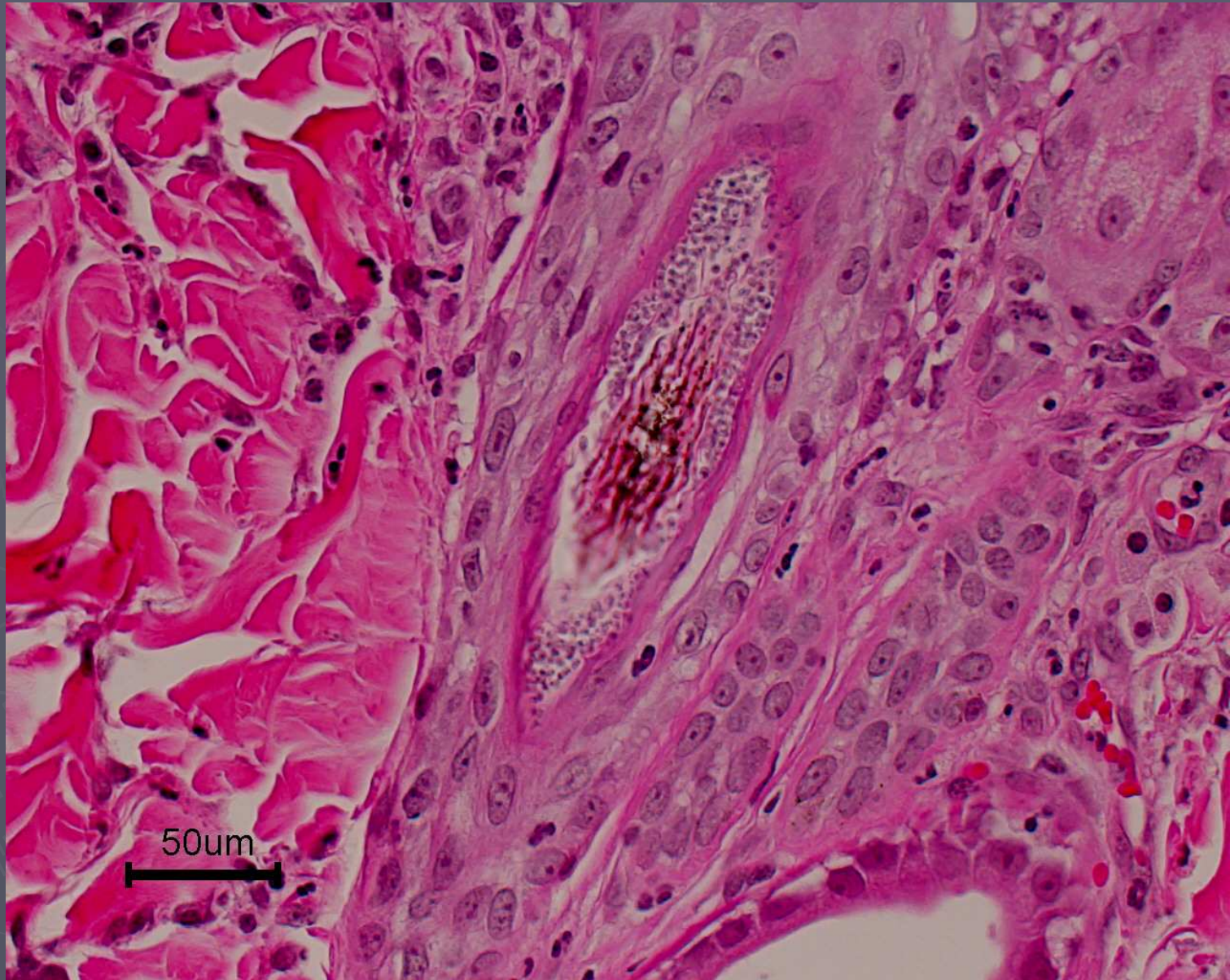


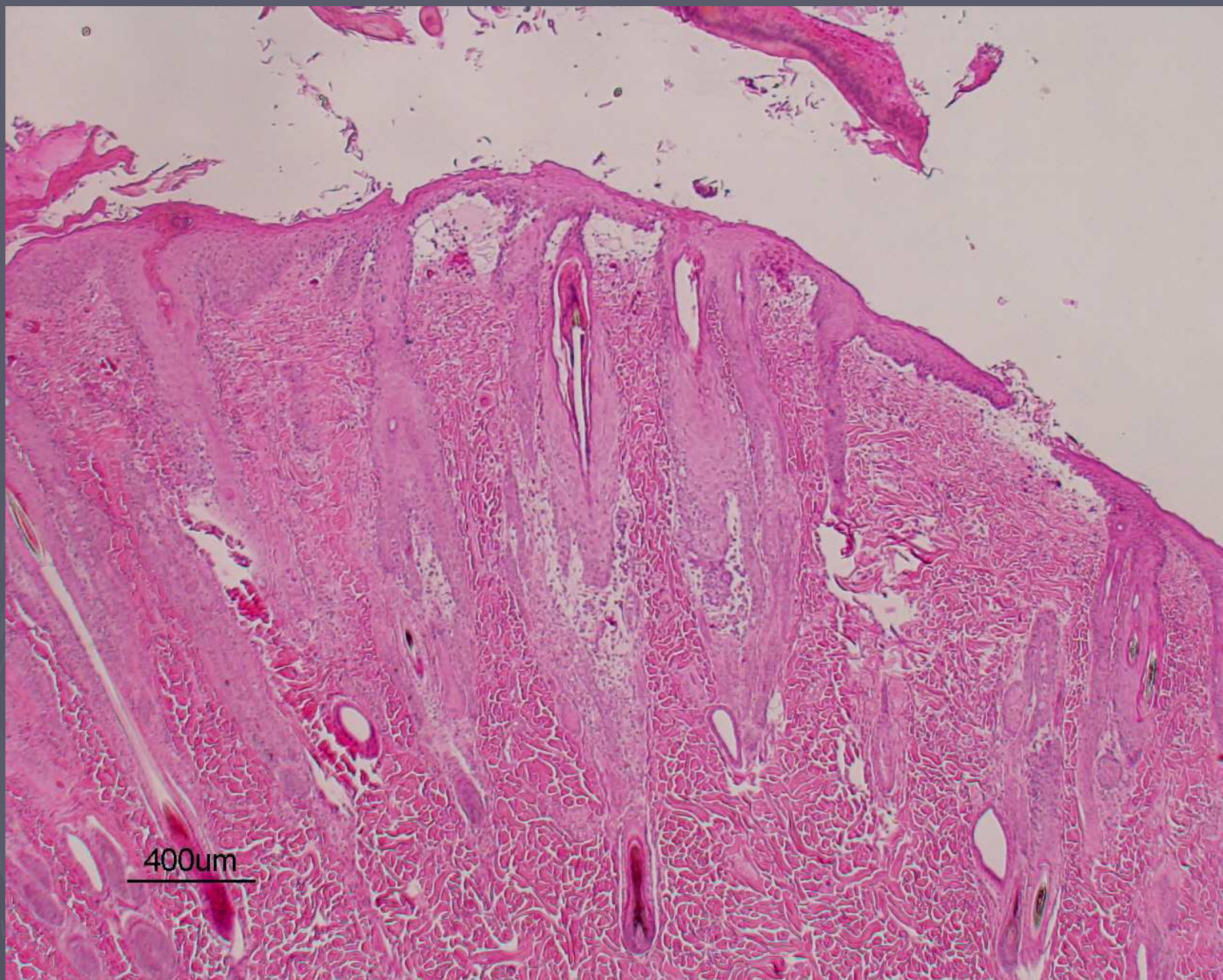
Deeper step sections revealed mite fragments in granuloma



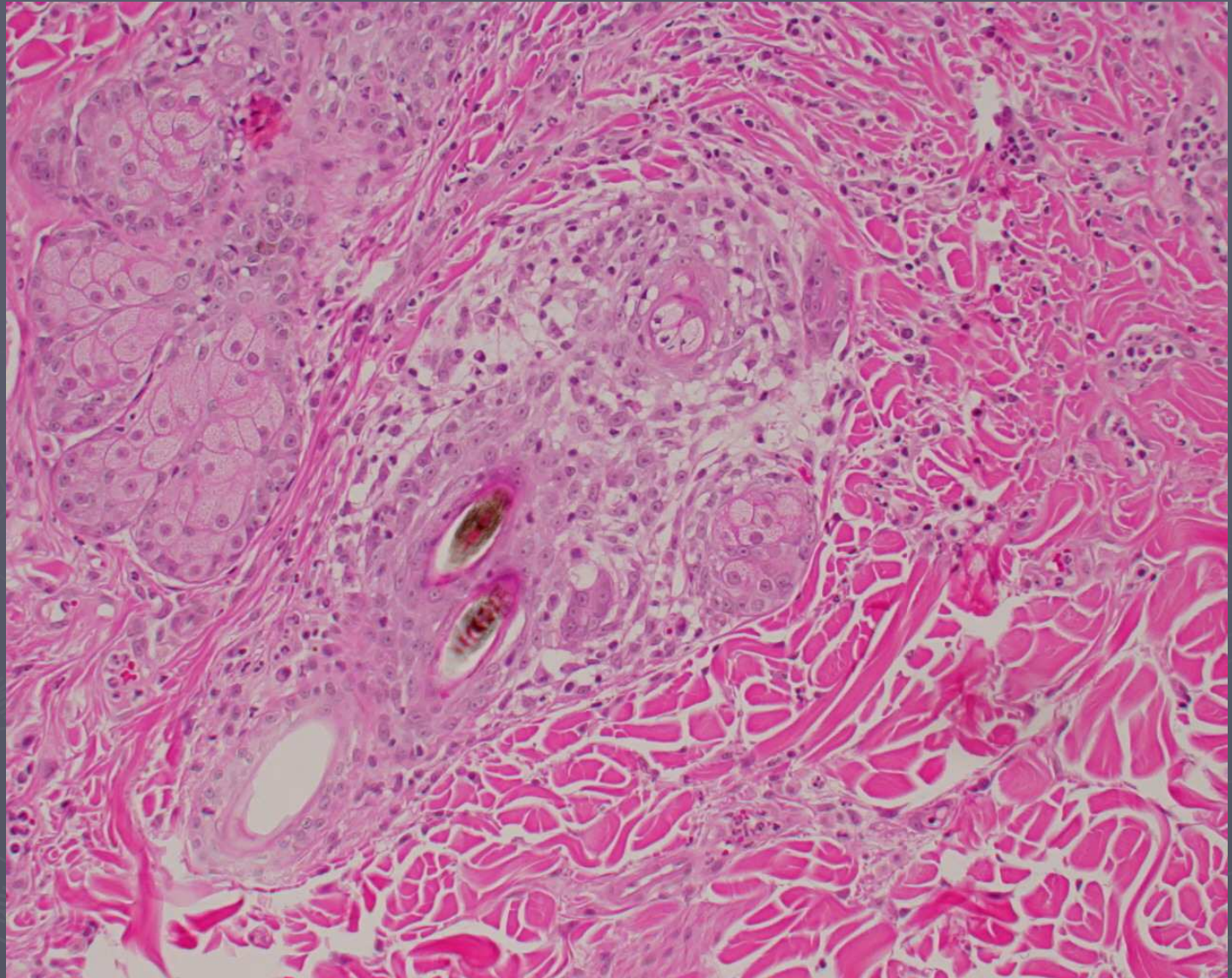
Pyogranuloma with fragments of demodex mites

Dermatophytosis

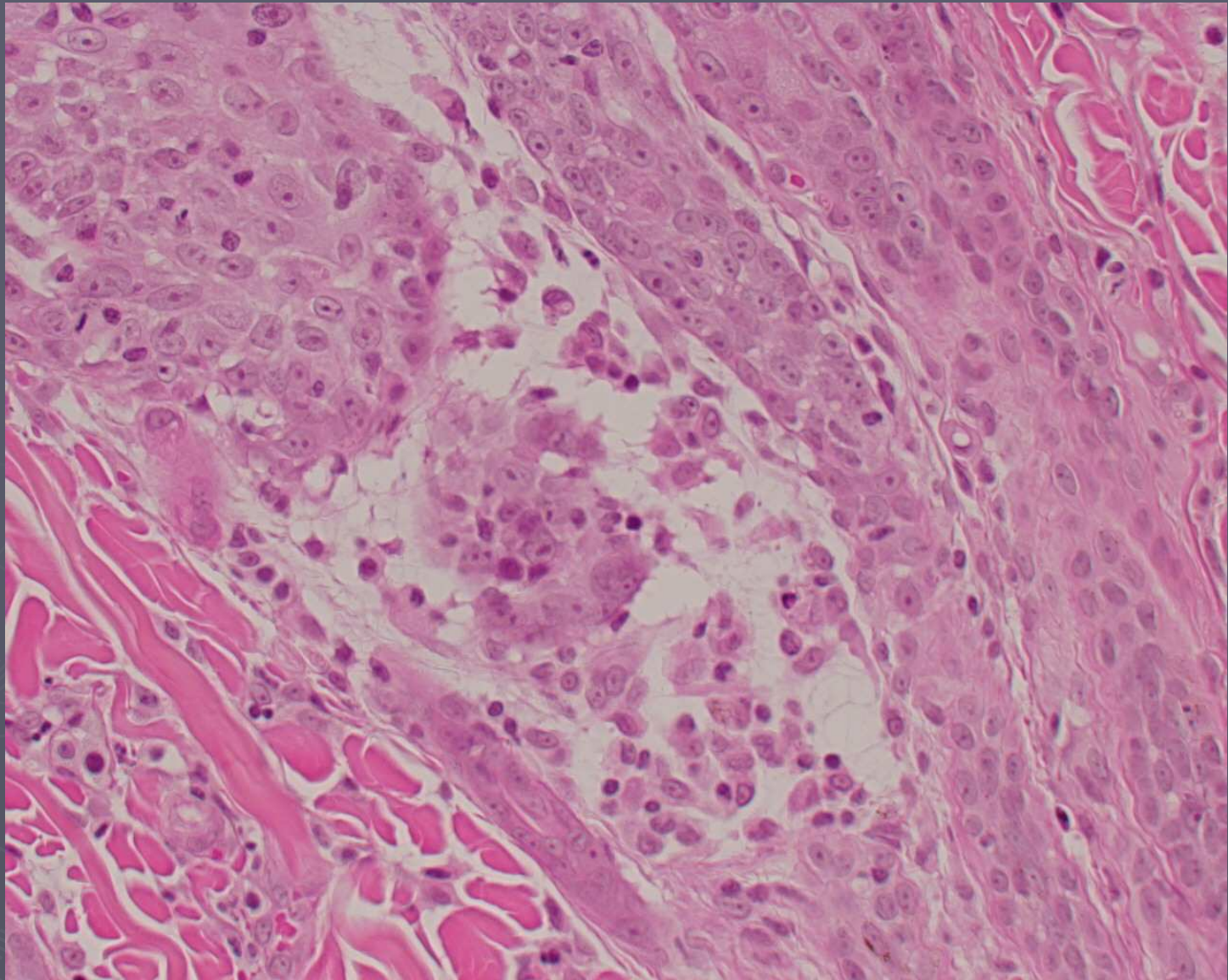




Mucinotic Mural F/F



Feline mucinotic mural folliculitis



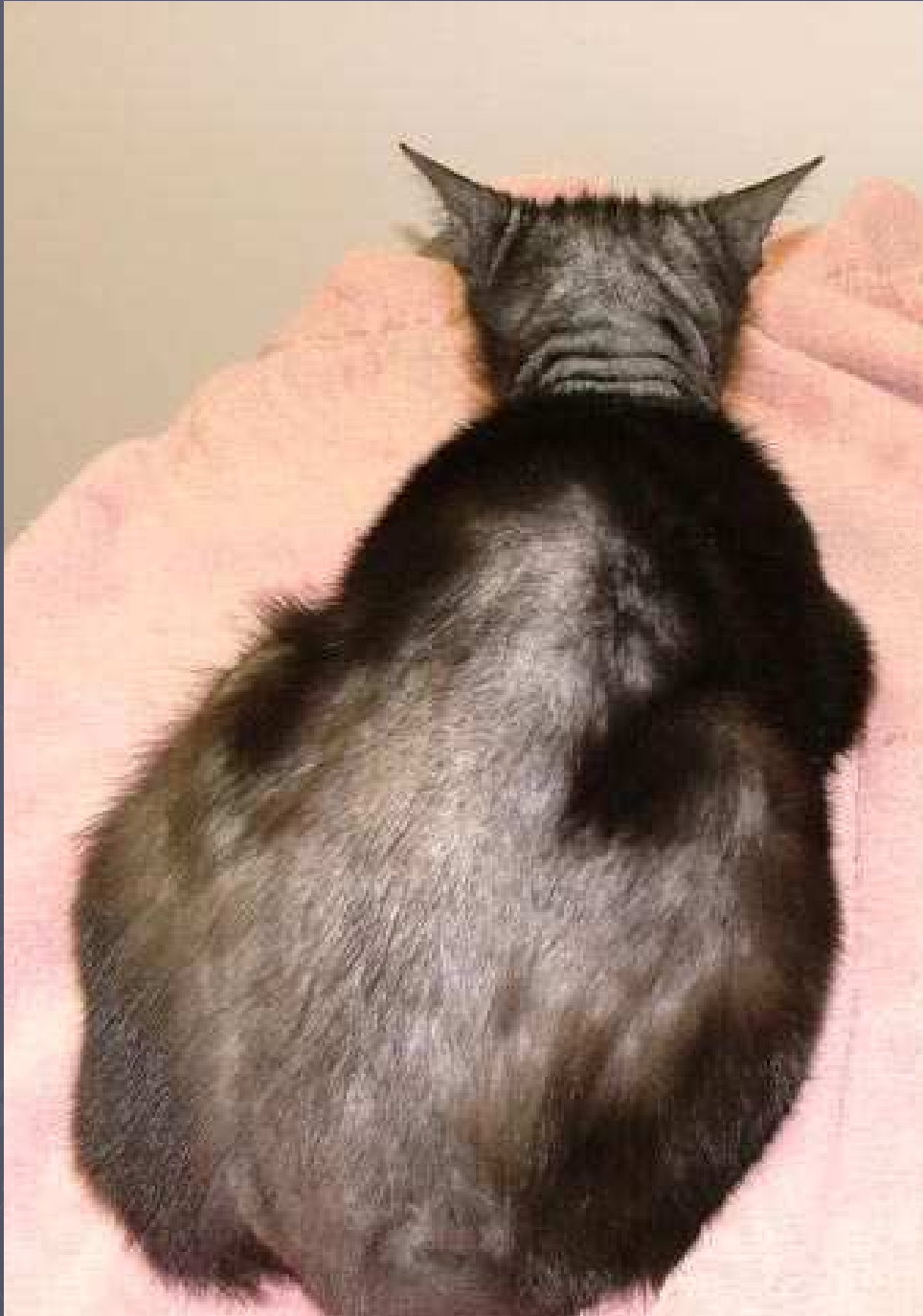Feline mucinotic mural folliculitis



*Gross photo of the same cat
with mucinotic mural folliculitis*

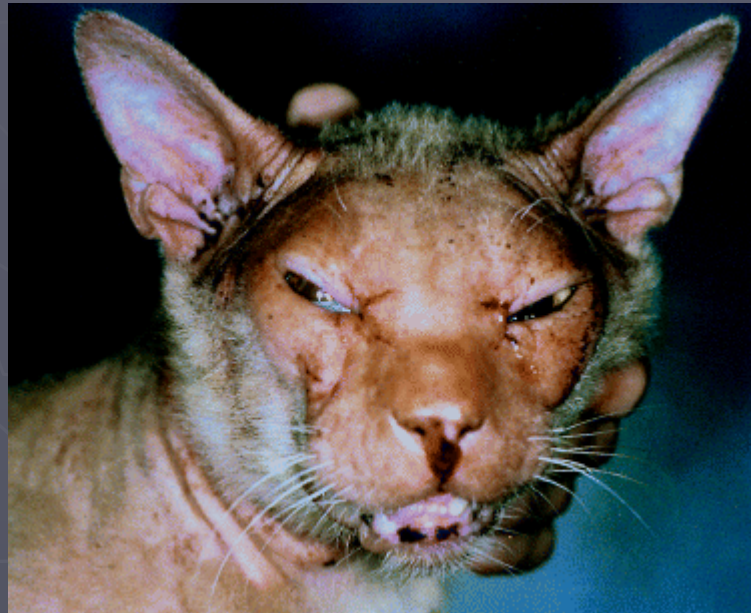Hair loss and scaling





The face is usually more severely affected

- ▶ Gross, Thelma Lee, Olivry, Thierry, Vitale, Carlo B. & Power, Helen T.
Degenerative mucinotic mural folliculitis in cats.
Veterinary Dermatology **12** (5), 279-283, October 2001.



Characteristic thickened muzzle and narrowed eyes