



**Penn**  
Veterinary Medicine


# Equine Dermatology

Elizabeth A. Mauldin  
School of Veterinary Medicine  
Laboratory of Pathobiology and Toxicology  
University of Pennsylvania

**Many Species. One Medicine.™**

# Outline

- Congenital Diseases
- Immune-mediated disease
- Alopecia in the horse
- Cornification defects
- Nodular Lesions
- Miscellaneous and Classics



Stannard's Illustrated Dermatology Notes, Vet Derm Vol 11, 2000.

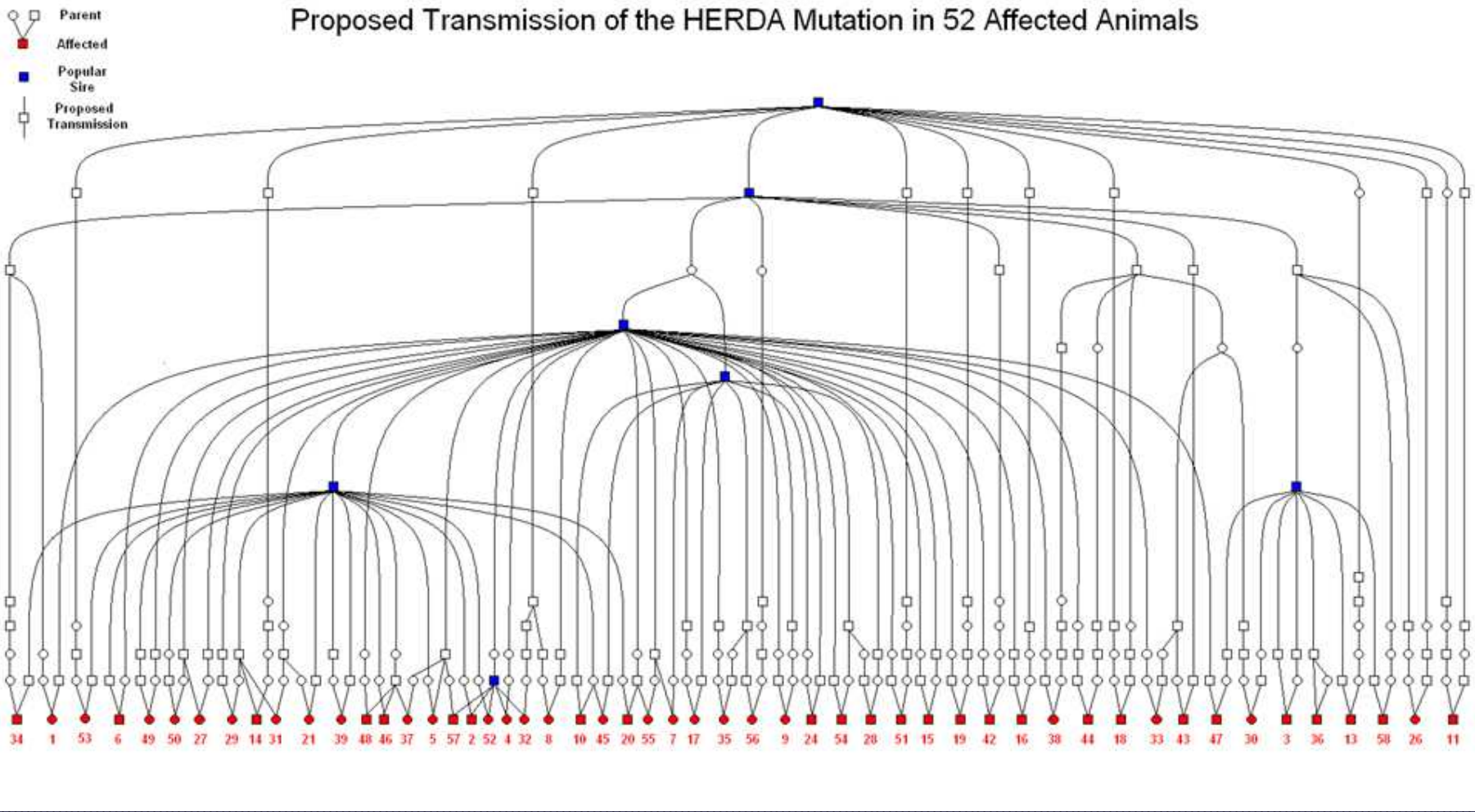
# Congenital Diseases

# HERDA

- Hereditary Equine Regional Dermal Asthenia ("Hyperelastosis cutis")
- Quarter horses, paints and appaloosas (rarely other breeds)
- Defect: deep dermal collagen fibers
- Autosomal recessive
- Usually noticed by 2 years of age

The following slide presentation on HERDA is the courtesy of Dr. Steve White  
University of California-Davis

# Proposed Transmission of the HERDA Mutation in 52 Affected Animals



Courtesy R. Tryon

# HERDA

- Lesions: dorsum, sides of the neck, legs; easily torn, stretched skin and/or ulcers, seromas and hematomas
- Healing usually OK, often leaves scars







