

Respiratory Pathology of the Horse

Minor resource

www.ivis.org

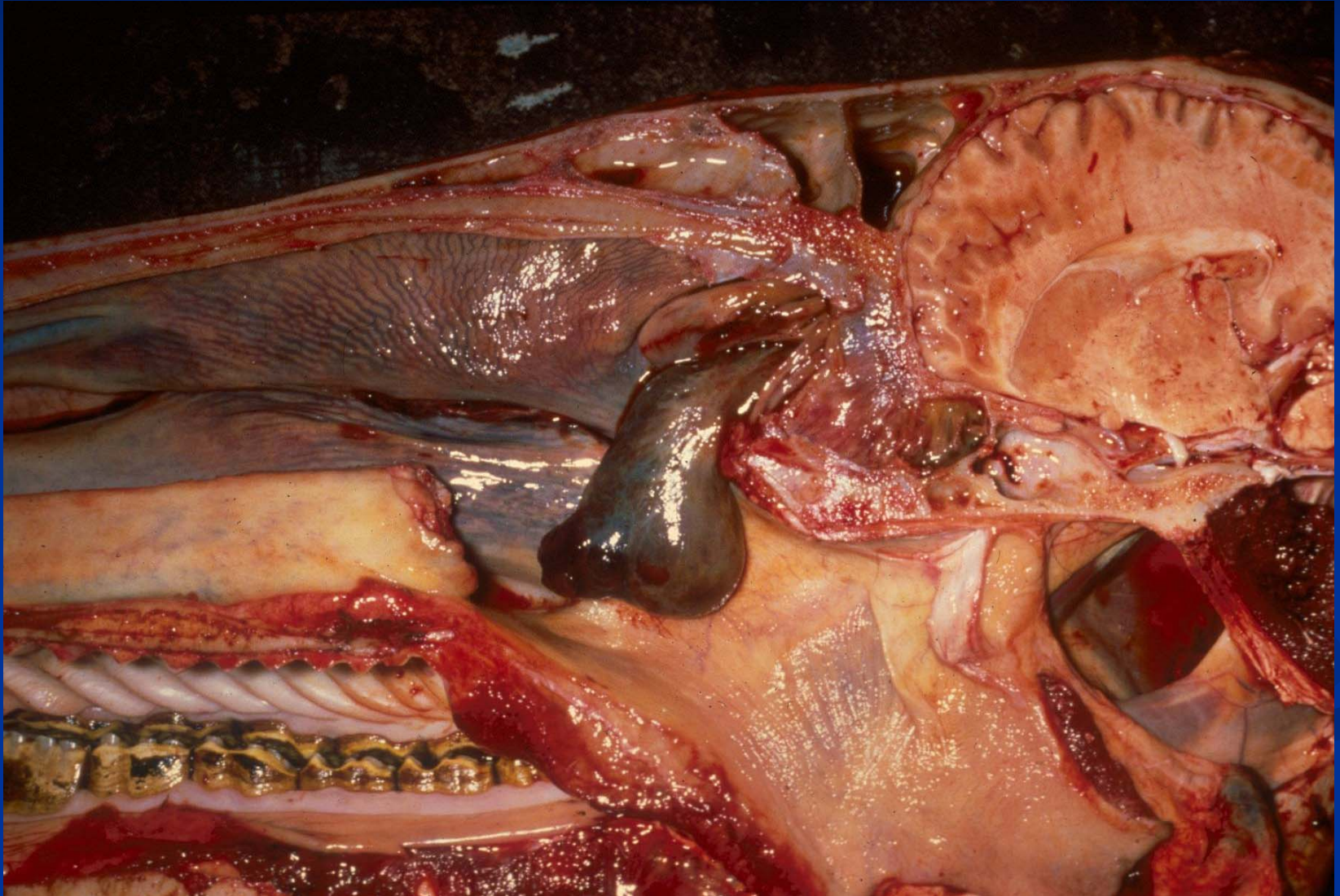
Pathology of Respiratory System

- Upper Respiratory Tract
 - Non infectious Disease
 - Developmental Abnormalities
 - Miscellaneous
 - Neoplasia
 - Infectious Disease
- Lower Respiratory Tract (Lung)
- Pleura and thoracic cavity

Noninfectious Disease of Upper Respiratory Tract – Nasal Cavity

- Ethmoid hematoma
 - Older horses
 - Cause of epistaxis
 - Polyp like mass
- Nasal amyloidosis (amyloid AL)
 - Multiple nodules
- Nasal and paranasal sinus cysts
- Neoplasia

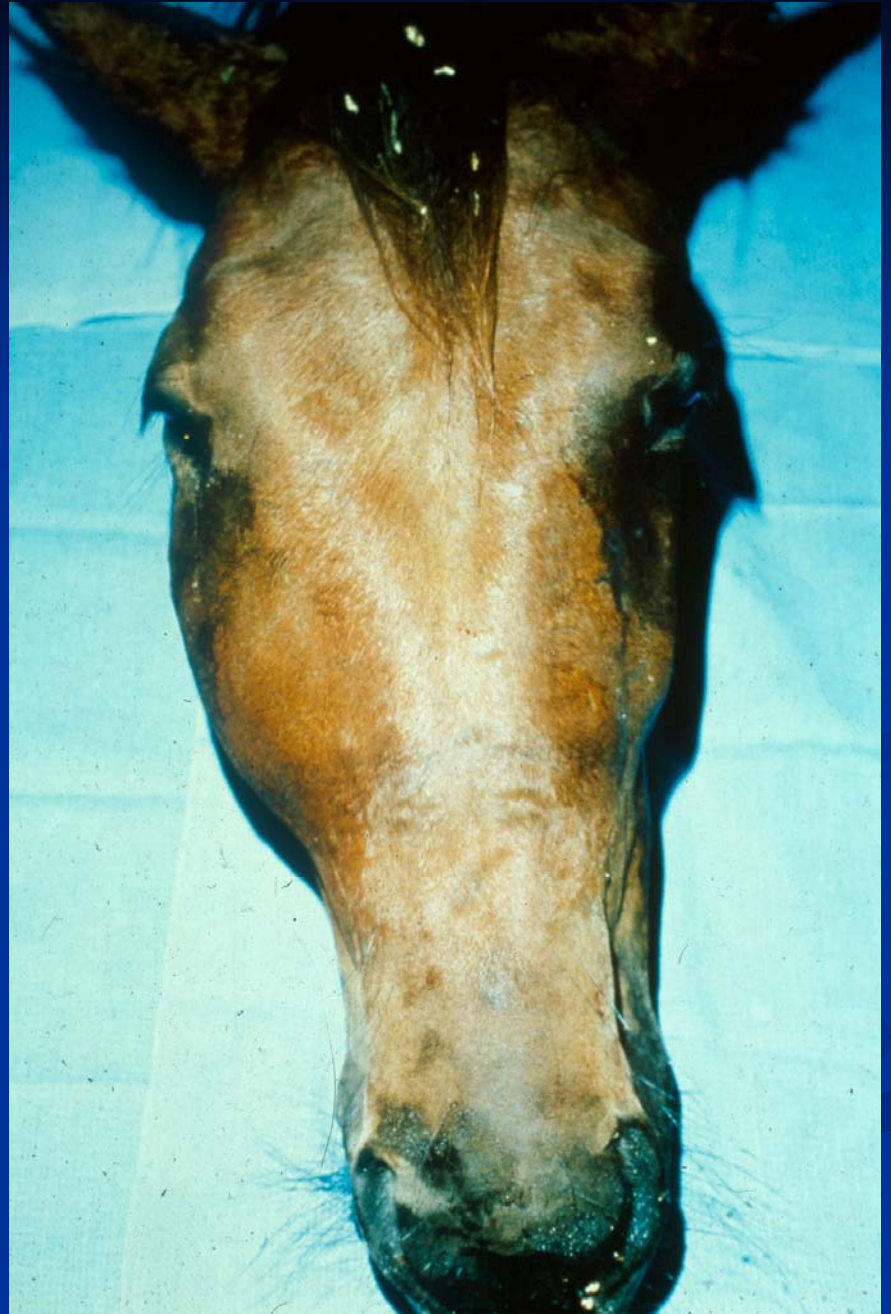Ethmoid Hematoma



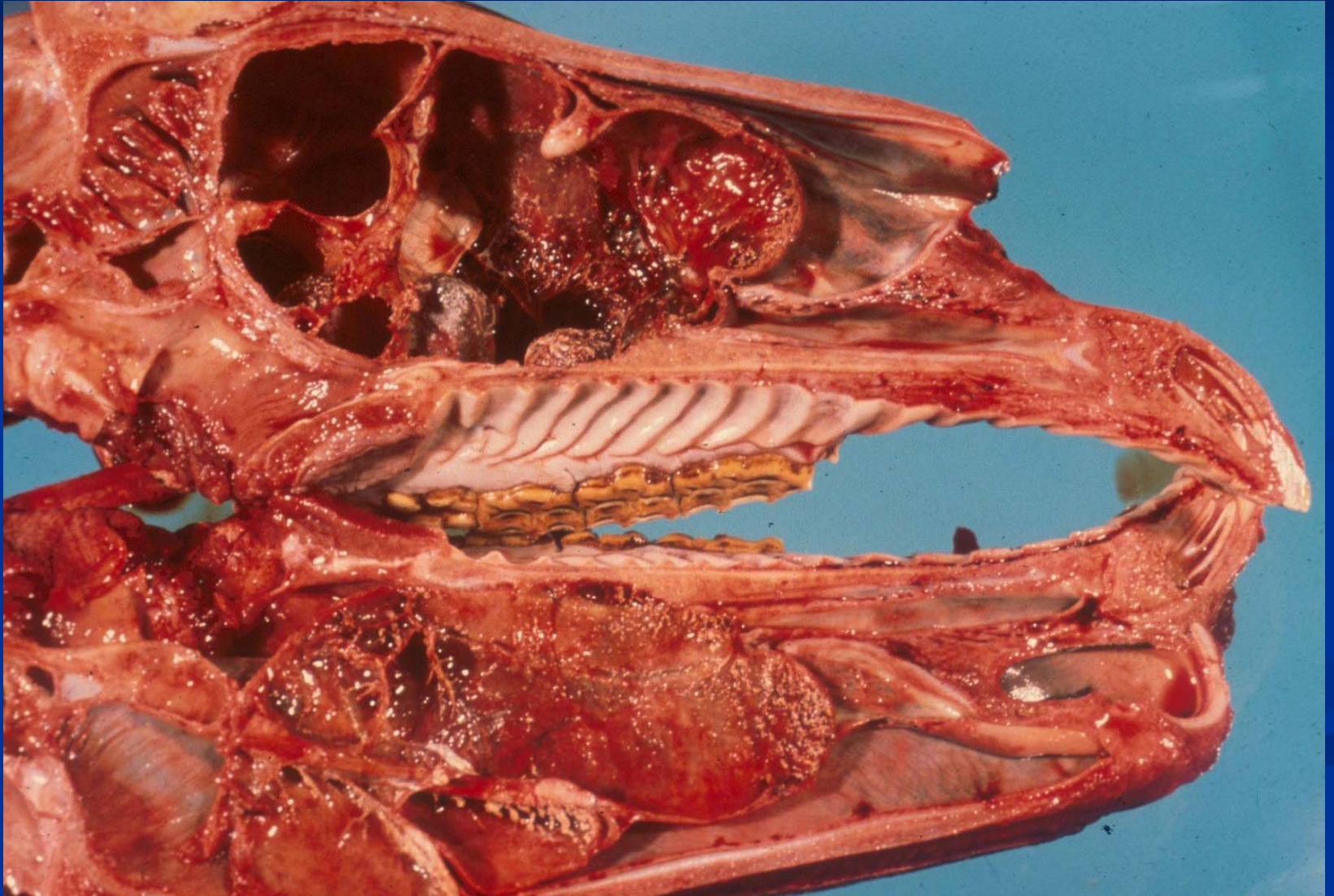
Upper Respiratory Tract - Developmental Abnormalities

- Nasal and paranasal sinus cysts
 - Originate from dentigerous tissue
 - Slowly growing and expansive
 - Result in cranial malformation
 - Secondary infection possible
 - DD neoplasia, tooth root abscess
 - Surgical treatment possible

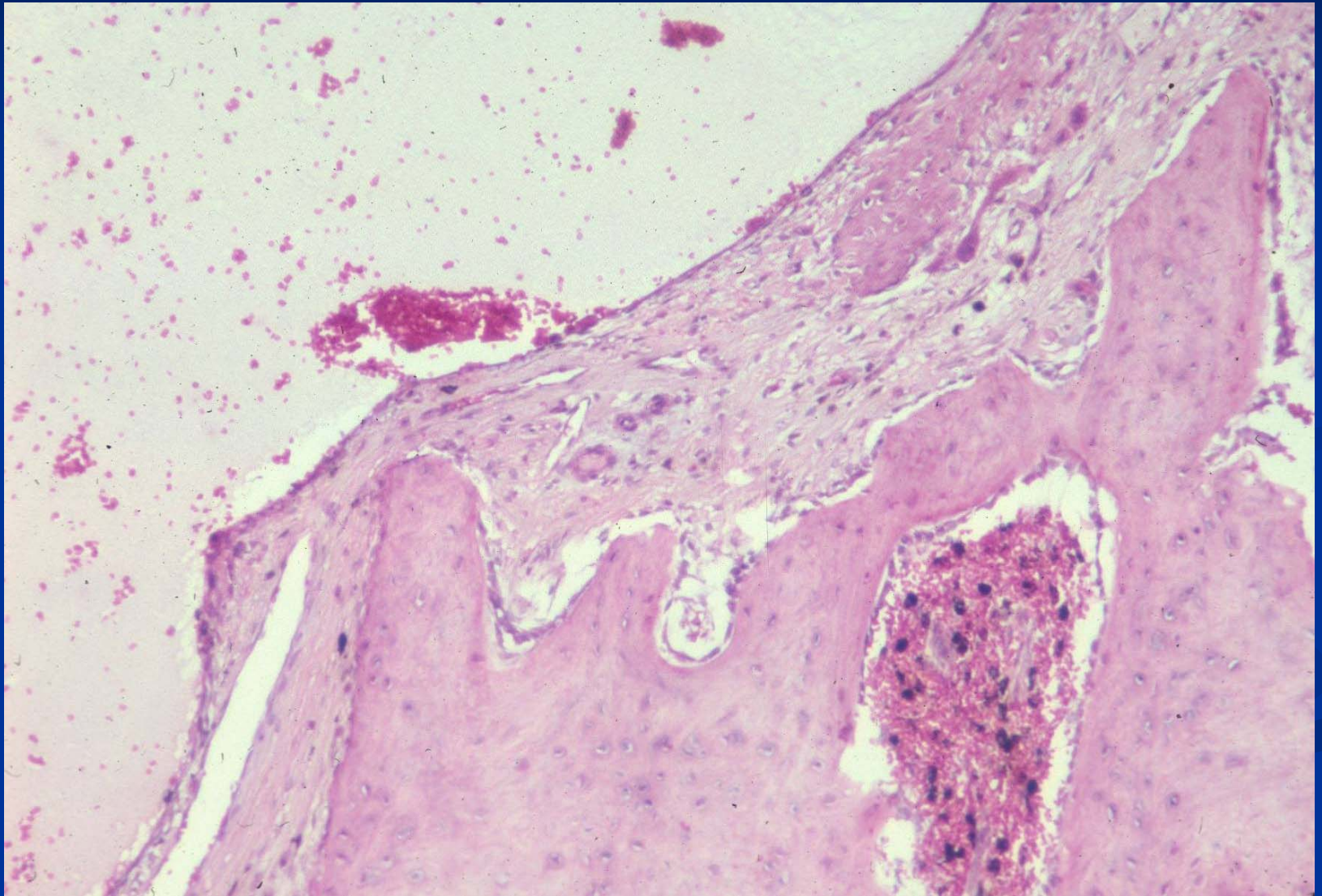
Nasal and Paranasal Sinus Cysts



Nasal and Paranasal Sinus Cysts



Nasal and Paranasal Sinus Cysts



Causes of Epistaxis

- Exercise induced pulmonary hemorrhage (EIPH)
- Gutteral pouch mycoses
- Trauma
- Ethmoid hematoma
- Invasive intranasal lesion
 - Neoplasia

Neoplasia of the Nasal Cavity: Clinical Signs

- Unilateral or bilateral muroid or bloody discharge
- Intermittent sneezing
- Obstruction of nasolacrimal duct
- Facial swelling