

- **Planes**
 - Macule(< 1-cm)
 - Patch (>1-cm)
- **Elevations**
 - Papule (< 1-cm)
 - Plaque (> 1-cm)
 - Pustule
 - Lichenification
 - Vesicle/Bulla
 - Wheal
 - Cyst/Nodule
- **Depressions**
 - Erosions and Ulcers
- **Tumor Openings**
 - Comedones/Fissures/Sinus

Primary Skin Lesions

- Macule
- Patch
- Papule
- Plaque
- Pustule
- Wheal
- Nodule
- **Tumor**
- **Vesicle**
- Bulla

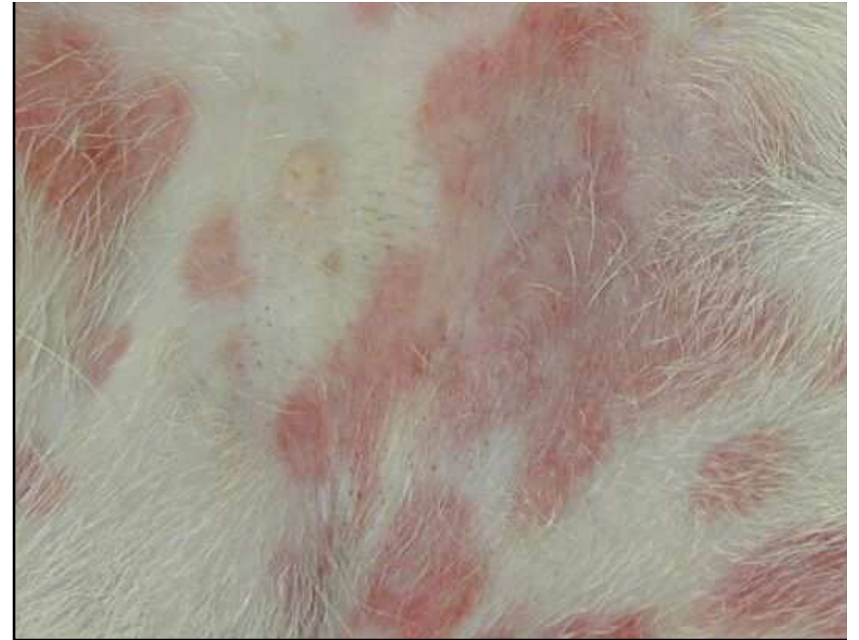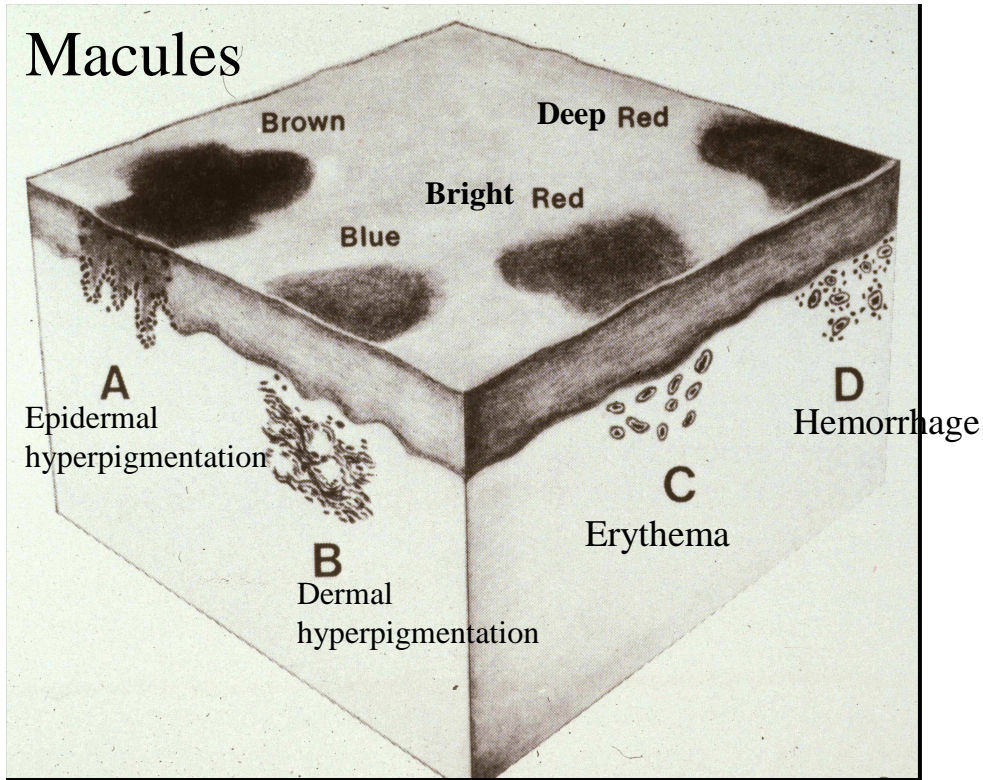
Secondary Skin Lesions

- Epidermal collarette
- Erosion
- Ulcer
- Lichenification
- Excoriation
- Hyperkeratosis (Scale)
- Fissure
- Scar
- Eschar
- Callus

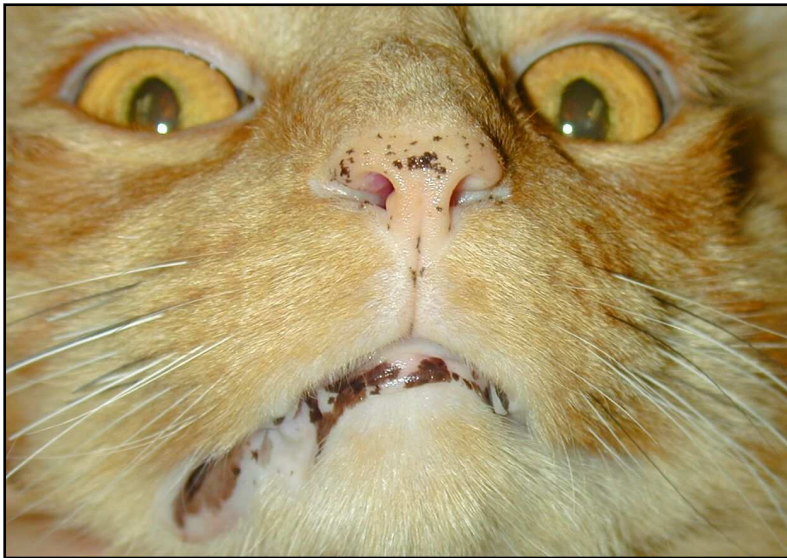
Lesions that may be either primary or secondary

- **Scale**
- Crust
- Follicular cast
- Comedo
- Hyperpigmentation
- Hypopigmentation
- Alopecia

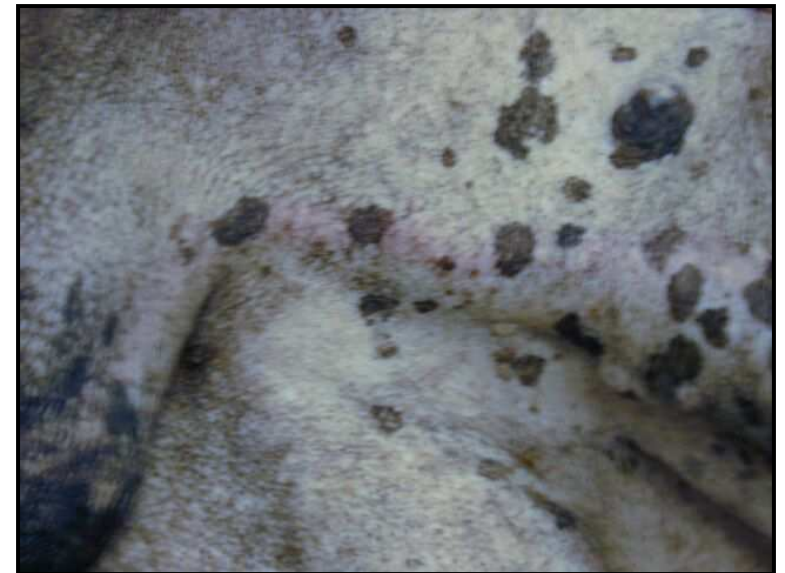
Macules



Erythemic macules and patches (coalescing) in a dog with eosinophilic dermatitis



Macular melanosis in a cat with lentigo simplex



Macular and patchy melanosis in a dog with Sertoli-cell tumor