

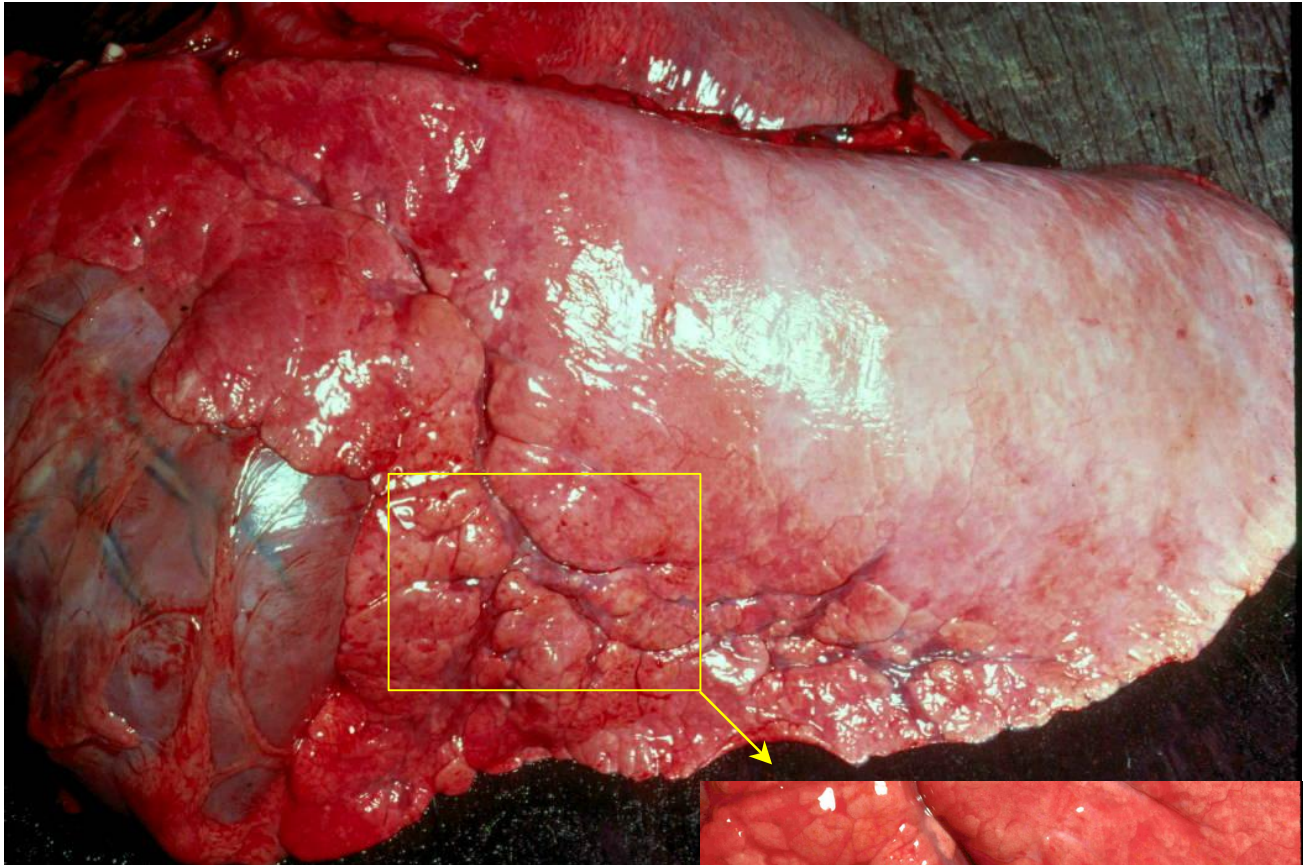
ASVP DIAGNOSTIC EXERCISE NO. 19

Roger Kelly

History:

Specimen from a 6 week-old foal that was believed to have received insufficient colostrum at birth. During its short life it suffered a range of febrile episodes, including destructive osteoarthritis of a hock joint that necessitated euthanasia

(this page can be enlarged to 200% for closer views of this specimen)



1. Describe the abnormalities.
2. What basic disease processes might be present?
3. Pathological diagnosis (give other possibilities in order of preference)?
4. Outline the likely pathogenesis of this condition.

As with previous exercises, I will send out a description and discussion of this case in a couple of weeks, and it will eventually be archived on the members login pages of the ASVP website <http://www.asvp.asn.au/>

Please advise me roger-kelly@aapt.net.au if you have any problem opening this case

If anyone wishes to provide a diagnostic case, please contact me if you need advice about image requirements.